



# Journal of the ASEAN Federation of Endocrine Societies

Volume No. 38 Special Edition 2 | ISSN 2308-118x (Online)



**MEMS**  
Established 1981  
Malaysian Endocrine  
& Metabolic Society

MEMS ANNUAL CONGRESS  
**MAC 13** 2023  
7-9 JULY 2023  
Hilton Kuala Lumpur & Le Méridien Kuala Lumpur

NAVIGATING THE  
MULTIVERSE OF  
**ENDOCRINOLOGY**

[www.memsmac.org](http://www.memsmac.org)  
Event ID: CPDE4473

## Messages

Organising Committee

Legacy Award 2023

International and Local Faculty

Programme Detail

Adult Oral Presentation

Adult Physical Poster Presentation

Adult E-Poster Presentation

Basic Science Oral Presentation

Basic Science Physical Poster Presentation

Basic Science E-Poster Presentation

Paediatrics Oral Presentation

Paediatrics Physical Poster Presentation

Paediatrics E-Poster Presentation

Sponsors and Exhibitors



# JAFES

[www.asean-endocrinejournal.org](http://www.asean-endocrinejournal.org)





# Journal of the ASEAN Federation of Endocrine Societies

Volume No. 38 Special Edition 2 | ISSN 2308-118x (Online)

The publication of the abstracts for the 2023 MEMS Annual Congress as a special edition of the Journal of the ASEAN Federation of Endocrine Societies is a service of the journal to its member societies. The statements and opinions expressed in this publication are those of the individual authors and do not necessarily reflect the views of the Journal of the ASEAN Federation of Endocrine Societies (JAFES). The abstracts included have been selected by the Convention's Scientific Committee and have not undergone the editorial deliberation and peer review of the JAFES. JAFES is not responsible or liable in any way for the currency of the information, for any errors, omissions or inaccuracies, or for any consequences arising therefrom. With respect to any drugs mentioned, the reader is advised to refer to the appropriate medical literature and the product information currently provided by the manufacturer to verify appropriate dosage, method and duration of administration, and other relevant information. In all instances, it is the responsibility of the treating physician or other healthcare professional, relying on independent experience and expertise, as well as knowledge of the patient, to determine the best treatment for the patient.



**Malaysian Endocrine  
& Metabolic Society**





## Welcome Message by President of MEMS

Dear Friends and Colleagues,

*Warmest Greetings from MEMS!*

On behalf of the Malaysian Endocrine and Metabolic Society (MEMS), we would like to welcome everyone to the 13<sup>th</sup> MEMS Annual Congress (MAC). This is the first time we are having a full face-to-face conference since the COVID-19 pandemic and we are very excited to see every one.

The theme for this year, **“Navigating the Multiverse of Endocrinology,”** was carefully chosen to reflect the multispecialty involvement in managing endocrine disorders. This emphasizes the importance of teamwork with different disciplines for a better management of our patients. Therefore, we have reached out to gather experts from various fields in and outside endocrinology to share their valuable insights in best clinical practice.

We would like to extend our most sincere gratitude to all the invited speakers who will share with us the latest updates and their clinical opinions on the various topics. The topics that have been outlined address many clinical issues that are seen in primary and secondary care. We will have interactive quizzes to make it more fun and interesting for everybody and of course, there are prizes to be won! We hope that your experience attending MAC will be rewarding and fulfilling in many ways.

Our Annual Congress also has a program dedicated to researchers and scientists to present their work. To all whose abstracts have been accepted, a big congratulations! We will be offering attractive incentives and prizes for those who walk away with awards in the various categories for Oral and Poster presentations. In addition to the Best Oral and Best Poster prizes, we are also introducing an exciting new award this year for the Best Visual Abstract.

We look forward to meeting and networking with everyone while exchanging the latest updates in the ever-evolving world of endocrinology. Once again, here’s a warm welcome to MAC 13!

Best Wishes,

**Dr Nurain Mohd Noor**

*President, MEMS 2022-2024*

*Chairperson, 13<sup>th</sup> MEMS Annual Congress 2023*





## Welcome Message by Scientific Committee 2023

Dear Esteemed Colleagues,

We are delighted to extend our warmest greetings and welcome you to the 13<sup>th</sup> MAC- MEMS Annual Congress 2023. It will be held from 7<sup>th</sup> July 2023 to 9<sup>th</sup> July 2023 at the Hilton and Le Meridien, KL Sentral Kuala Lumpur. It is my honour to chair the Scientific Program Committee of MAC 13 2023. Together with my other program committee members, we have created an outstanding agenda. With utmost pleasure, I would like to announce the theme for this exciting event, "**Navigating the Multiverse of Endocrinology**," which reflects the multidisciplinary team involved in managing endocrine disorders.

MAC serves as a platform for the exchange of basic science and clinical research and innovative ideas in the field of endocrinology. With a focus on the latest advancements, emerging trends, and multiverse interdisciplinary collaborations, this conference aims to foster dialogue and enrich our collective knowledge in understanding the intricate world of hormones and their impact on human health.

MAC 13<sup>th</sup> Highlights:

- 1. Distinguished Plenary, Symposium and Meet the Expert Speakers.** Internationally renowned and local experts who will share their expertise and present captivating keynote lectures, providing insights into the endocrine latest updates.
- 2. Scientific Sessions.** Our program will encompass a wide array of topics, including:
  - Endocrine disorders and therapeutics
  - Neuroendocrinology
  - Metabolic syndrome and obesity
  - Reproductive endocrinology and fertility
  - Pediatric endocrinology
  - Endocrine oncology
  - Precision medicine and personalized endocrine care
- 3. Poster Presentations on Day 1 and Oral presentations on Day 2.** We have received exciting research and case reports. This will provide an excellent opportunity for clinicians and scientists to share their findings, receive valuable feedback, and engage in discussions with fellow experts. Prizes to be won too for best oral and poster presentations.
- 4. Pre-Conference Thyroid Workshop on 6<sup>th</sup> July 2023.** Enhance your knowledge and gain practical skills by participating in our pre-conference thyroid workshop, which will focus on hands on ultrasound sessions.
- 5. Networking Opportunities.** Interact with esteemed colleagues, forge new collaborations, and establish meaningful connections during our networking sessions, social events, and informal gatherings.
- 6. Industry Exhibition.** Explore the latest advancements in endocrine-related technologies, products, and services showcased by leading industry partners, fostering collaborations between academia and industry.

In addition to getting all the above endocrine updates, we will take a moment to remember Prof Dato Khalid Kadir and Prof Rokiah Pendek, who we sadly lost. Both were eminent gurus in the endocrinology fraternity.

We would like to welcome everyone to our 13<sup>th</sup> MAC 2023. Together, let us push the boundaries of endocrinology and pave the way for new breakthroughs that will positively impact patient care and enhance human health.

On behalf of the organizing committee, I extend my gratitude for your commitment to advancing the field of endocrinology, and I eagerly anticipate your presence at this esteemed event.

Yours sincerely,

**Dr Masni Mohamad**

*Scientific Chairperson, 13<sup>th</sup> MEMS Annual Congress 2023*



## Organising Committee

Organising Chairperson and  
Honorary Advisor

**Dr Nurain Mohd Noor**  
*Consultant Endocrinologist, Hospital Putrajaya*

Scientific Chairperson

**Dr Masni Mohamad**  
*Consultant Endocrinologist, Hospital Putrajaya*

Scientific Co-Chairpersons

Adult Session

**Dr Tong Chin Voon**  
*Consultant Endocrinologist, Hospital Melaka*

Paediatric Session

**Dr Wong Sze Lyn Jeanne**  
*Consultant Paediatrician and Paediatric Endocrinologist  
Sunway Specialist Centre Damansara, Kota Damansara*

Committee Members

**Assoc Prof Dr Lim Lee Ling**  
*Consultant Endocrinologist, University Malaya Medical Centre*

**Dr Noor Arliena Mat Amin**  
*Paediatric Endocrinologist, Hospital Raja Permaisuri Bainun*

**Dr Noor Lita Adam**  
*Consultant Endocrinologist, Hospital Tuanku Ja'afar*

**Dr See Chee Keong**  
*Consultant Endocrinologist, Hospital Sultan Haji Ahmad Shah Temerloh*

**Ms Cheah Yet Mei**  
*Manager, Malaysian Endocrine and Metabolic Society*



# LEGACY AWARD 2023



EMERITUS PROFESSOR  
DR CHAN SIEW PHENG

**Emeritus Professor Dr Chan Siew Pheng** is the legendary leader of Malaysian Endocrinology and is no stranger to our fraternity.

She received her MBBS in 1979 from University of Malaya (UM), the very place where she started her career as a house-officer. She obtained her MRCP (UK) in 1984 and was then appointed lecturer in the Department of Medicine, UM. She trained in endocrinology under the mentorship of Dr Arlene Ngan and Dato' Professor Dr Anuar Zaini Md Zain, together with Professor Desmond Johnston, at the St. Mary's Hospital, United Kingdom. She ascended the academic ladder from Associate Professor in 1992 to Professor in 2001. As recognition to her continuous contribution to UM, she received the highest lifetime-academic title, "Emeritus Professor," in 2022.

Professor Chan was the Head of Endocrinology in UM for two decades from 1992 until retirement. During her tenure, she established the combined antenatal gestational diabetes service; the first dedicated osteoporosis clinic in Malaysia, as well as innovating the structured diabetes nurse education program. She was instrumental in initiating and establishing the endocrine subspecialty training program for the MOH and to date, continues to teach and train the fellows at UM. Despite her official retirement in 2011, Professor Chan is bursting with energy. She is currently still hands on into clinical work, including managing acute endocrine emergencies in the midst of her busy outpatient service at her private practice in Subang Jaya Medical Centre.

Professor Chan has contributed immensely in research, specifically in diabetes epidemiology and management in our local healthcare system, influence of nutrition on bone health and vitamin D deficiency in postmenopausal osteoporosis. The DiabCare Malaysia study, conducted by Professor Chan and other key endocrinologists from 1997-2013, was the stimulus to the initiation of a systematic diabetes management and Diabetes Resource Centres across Malaysia. She placed Malaysia and UM on the global map by leading landmark clinical trials including the ADVANCE, CHARISMA, FACT-International and other clinical trials for DPP4-inhibitors, SGLT2-inhibitors, lipid-lowering agents and osteoporosis.

Professor Chan is a charismatic leader and she has held many top office positions, sometimes even simultaneously at many endocrine related professional bodies in Malaysia. She is the immediate Past President of the Malaysian Endocrine and Metabolic Society, MEMS (2020-2022); Honorary Treasurer of MEMS from 2016-2020 and she was a council member of the ASEAN Federation of Endocrine Societies (AFES), 2020-2022. She is also the immediate Past President of the Malaysian Osteoporosis Society (2006-2010; 2018-2022) and Diabetes Malaysia (2001-2005). She also sits on the editorial board of the *Osteoporosis* and *Sarcopenia* journal.

Professor Chan is the go-to key opinion leader for many professional bodies, the mass media and pharmaceutical companies. She has zealously spearheaded the CPG for the Management of Type 2 diabetes (3<sup>rd</sup> CPG [2004], 6<sup>th</sup> CPG [2020] and Osteoporosis (Chairperson 2001, 2006, update 2015). She has also played a role as a member of the taskforces for development of CPG Management of Dyslipidaemia 2017; CPG prevention of CVD in women 2016; and CPG Menopause Management 2022.


On a personal note, her husband Dr Aw Seng Meng and two sons have been her consistent support throughout. Since 2020, Professor Chan is "Grand" mother not only to Malaysian endocrinology but also to her adorable granddaughter.

Despite having described her illustrious CV, I believe that the true reason Professor Chan is bestowed with the 2023 MEMS Legacy Award is the lasting impact she has made on Malaysian endocrinologists. For many of us who have graduated from the "SP Chan Training Academy," she has imparted to us valuable lessons inside and outside of endocrinology. Living by example, she continues to teach us the meaning of true hard work, the art of making the right judgement at the right time and place, and always placing everything in perspective without being carried away by finer details.

As impactful as the learnings from the UKPDS, this year's one and only legacy award recipient, Emeritus Professor Dr. Chan Siew Pheng has and continues to exert a positive legacy effect on the endocrine fraternity in Malaysia.



MEMS ANNUAL CONGRESS  
**MAC 13** 2023 **International  
Faculty**



Professor Dr Michael Lean  
*University of Glasgow  
United Kingdom*



Professor Dr Bu Yeap  
*University of Western Australia  
Australia*




Professor Dr Craig Munns  
*University of Queensland  
Australia*



Professor Dr C Rajasoorya  
*Sengkang General Hospital  
Singapore*



Professor Dr Fabian Yap Kok Peng  
*KK Women's and Children's Hospital  
Singapore*



Professor Dr Jonathan Shaw  
*Baker Heart and Diabetes Institute  
Australia*



Professor Dr Leanne Ward  
*University of Ottawa  
Canada*



MEMS ANNUAL CONGRESS  
**MAC 13** 2023 **Local Faculty**

Professor Dato' Dr Mafauzy  
 Mohamed  
*Universiti Sains Malaysia Kubang  
 Kerian*

Professor Dato' Dr Wan Mohamad  
 Wan Bebakar  
*Hospital Univesiti Sains Malaysia*

Emeritus Professor Dr Chan Siew  
 Pheng  
*Subang Jaya Medical Centre*

Professor Dr Muhammad Yazid  
 Jalaludin  
*University of Malaya Medical Centre*

Professor Dr Nor Azmi Kamaruddin  
*Institut Jantung Negara*

Professor Dr Norlaila Mustafa  
*Hospital Canselor Tuanku Muhriz  
 UKM*

Professor Dr Norlela Sukor  
*Hospital Canselor Tuanku Muhriz  
 UKM*

Professor Dr Rohana Abdul Ghani  
*Universiti Teknologi MARA (UiTM)*

Professor Dr Shireene Ratna  
 Vethakkan  
*University of Malaya Medical Centre*

Professor Dr Wu Loo Ling  
*Subang Jaya Medical Centre*

Associate Professor Dr Abdul Halim  
 Abdul Rashid  
*Hospital Canselor Tuanku Muhriz UKM*

Associate Professor Dr Ani Amelia  
 Dato' Zainuddin  
*Hospital Canselor Tuanku Muhriz  
 UKM*

Associate Professor Dr Azriyanti  
 Anuar Zaini  
*University of Malaya Medical Centre*

Associate Professor Dr Barakatun  
 Nisak Mohd Yusof  
*Universiti Putra Malaysia*

Associate Professor Dr Geeta  
 Appannah  
*Universiti Putra Malaysia*

Associate Professor Dr Jeyakantha  
 Ratnasingam  
*University of Malaya Medical Centre*

Professor Dato' Dr Mafauzy  
 Mohamed  
*Universiti Sains Malaysia Kubang  
 Kerian*

Professor Dato' Dr Wan Mohamad  
 Wan Bebakar  
*Hospital Univesiti Sains Malaysia*

Emeritus Professor Dr Chan Siew  
 Pheng  
*Subang Jaya Medical Centre*

Professor Dr Muhammad Yazid  
 Jalaludin  
*University of Malaya Medical Centre*

Professor Dr Nor Azmi Kamaruddin  
*Institut Jantung Negara*

Professor Dr Norlaila Mustafa  
*Hospital Canselor Tuanku Muhriz  
 UKM*

Professor Dr Norlela Sukor  
*Hospital Canselor Tuanku Muhriz  
 UKM*

Professor Dr Rohana Abdul Ghani  
*Universiti Teknologi MARA (UiTM)*

Professor Dr Shireene Ratna  
 Vethakkan  
*University of Malaya Medical Centre*

Professor Dr Wu Loo Ling  
*Subang Jaya Medical Centre*

Associate Professor Dr Abdul Halim  
 Abdul Rashid  
*Hospital Canselor Tuanku Muhriz UKM*

Associate Professor Dr Ani Amelia  
 Dato' Zainuddin  
*Hospital Canselor Tuanku Muhriz  
 UKM*

Associate Professor Dr Azriyanti  
 Anuar Zaini  
*University of Malaya Medical Centre*

Associate Professor Dr Barakatun  
 Nisak Mohd Yusof  
*Universiti Putra Malaysia*

Associate Professor Dr Geeta  
 Appannah  
*Universiti Putra Malaysia*

Associate Professor Dr Jeyakantha  
 Ratnasingam  
*University of Malaya Medical Centre*

Associate Professor Dr Lim Lee Ling  
*University of Malaya Medical Centre*

Associate Professor Dr Mohd Nahar  
 Azmi Mohamed  
*University of Malaya Medical Centre*

Associate Professor Dr Norasyikin  
 A. Wahab  
*Hospital Canselor Tuanku Mukhriz*

Associate Professor Dr Ting Tzer  
 Hwu  
*Universiti Putra Malaysia*

Dato' Dr Malik Mumtaz  
*Island Hospital*

Datuk Dr Mohamed Badrulnizam  
 Long Bidin  
*Hospital Kuala Lumpur*

Datuk Dr Mohamed Hatta Tarmizi  
*Sabah Care Fertility Centre*



MEMS ANNUAL CONGRESS  
**MAC 13** 2023 **Local Faculty**

Datuk Dr Zanariah Hussein  
*Hospital Putrajaya*

Dr Alexander Tan Tong Boon  
*Sunway Medical Centre*

Dr Annie Leong  
*Hospital Putrajaya*

Dr Arini Nuran Md Idris  
*Hospital Kuala Lumpur*

Dr Azraai Bahari Nasruddin  
*Hospital Putrajaya*

Dr Chen Harn Chin  
*Subang Jaya Medical Centre*

Dr Florence Tan Hui Sieng  
*Sarawak General Hospital*

Dr Foo Siew Hui  
*Hospital Selayang*

Dr Hew Fen Lee  
*Subang Jaya Medical Centre*

Dr Ijaz Hallaj Rahmatullah  
*Hospital Raja Permaisuri Bainun*

Dr Janet Hong Yeow Hua  
*Hospital Putrajaya*

Dr Kang Waye Hann  
*University Tunku Abdul Rahman*

Dr Krishnan Raman  
*Subang Jaya Medical Centre*

Dr Kuan Yueh Chien  
*Sarawak General Hospital*

Dr Lavannia Rajaratenam  
*Hospital Kuala Lumpur*

Dr Lee Yee Lin  
*Universiti Putra Malaysia*

Dr Lim Poi Giok  
*Hospital Kuala Lumpur*

Dr Lim Siang Chin  
*Mahkota Medical Centre*

Dr Lim Song Hai  
*Sabah Women and Children Hospital*

Dr Loh Huai Heng  
*Universiti Malaysia Sarawak*

Dr Masni Mohamad  
*Hospital Putrajaya*

Dr Meenal Mavinkurve  
*International Medical University*

Dr Noor Arliena Mat Amin  
*Hospital Raja Permaisuri Bainun*

Dr Noor Lita Adam  
*Hospital Tuanku Ja'afar*

Dr Noor Shafina Mohd Nor  
*Universiti Teknologi MARA (UiTM)*

Dr Norhaliza Mohd Ali  
*Hospital Sultanah Aminah*

Dr Nurain Mohd Noor  
*Hospital Putrajaya*

Dr Nurshadia Samingan  
*University of Malaya Medical Centre*

Dr Rashdan Zaki Mohamed  
*Damansara Specialist Hospital 2*

Dr See Chee Keong  
*Hospital Sultan Haji Ahmad Shah*

Dr Serena Khoo Sert Kim  
*Gleneagles Hospital Kota Kinabalu*

Dr Sharmila Sunita Paramasivam  
*University of Malaya Medical Centre*

Dr Subashini Rajoo  
*Hospital Kuala Lumpur*

Dr Suhaimi Hussain  
*Hospital Universiti Sains Malaysia*

Dr Tan Teik Hin  
*Sunway Medical Centre*

Dr Tong Chin Voon  
*Hospital Melaka*

Dr Vijay Ananda  
*Pantai Hospital Kuala Lumpur*

Dr Vijiya Mala Valayatham  
*Hospital Putrajaya*

Dr Wan Juani Wan Seman  
*KPJ Selangor Specialist Hospital*

Dr Wong Ming  
*Sunway Medical Centre*

Dr Wong Sze Lyn Jeanne  
*Sunway Specialist Centre Damansara*

Dr Yeap Swan Sim  
*Subang Jaya Medical Centre*

Dr Yong Sy Liang  
*Hospital Tengku Ampuan Rahimah  
 Klang*

Dr Yusniza Yusoff  
*Hospital Sungai Buloh*

Dr Zaridah Zainuri  
*Hospital Tunku Azizah*

Mr Azmi Alias  
*Hospital Kuala Lumpur*

Mr Mohd Yusof Abdullah  
*Kuala Lumpur Women and Children  
 Hospital*



## Programme Detail

Friday - 7<sup>th</sup> July 2023

	Clarke Ballroom	Ballroom B + Ballroom C	Sentral Ballroom
0730 - 0820	<b>Registration</b>		
0820 - 0830	Opening Speech and Welcome Remarks <i>Nurain Mohd Noor, President of MEMS</i>		
0830 - 0915	<b>PLENARY 1: The Diabetes Pandemic - Is There Hope for Tomorrow?</b> <i>Michael Lean</i> Chairperson: <i>Nurain Mohd Noor</i>		
0915 - 0945	<b>PLENARY 2: Recommendations from Malaysian Obesity Clinical Practice Guidelines</b> <i>Norlaila Mustafa</i> Chairperson: <i>Norasyikin A. Wahab</i>		
0945 - 1000	<b>Legacy Award</b> <i>Citation by Jeyakantha Ratnasingam</i>		
1000 - 1020	<b>Solve the Quiz! / Tea Break / Trade Exhibition</b>		
1020 - 1150	<b>Symposium 1: THYROID</b> <i>Chairperson: Subashini Rajoo</i>  DTC - What's Next After Surgery? <i>Vijay Ananda</i>  Non-iodine Avid DTC: What Are the Options? <i>Tan Teik Hin</i>  What's New in Undifferentiated Thyroid Cancer? <i>Lavannia Rajaratnam</i>	<b>Symposium 2: BONE METABOLISM</b> <i>Chairperson: Sharmila Sunita Paramasivam</i>  Update on Malaysian Osteoporosis CPG <i>Yeap Swan Sim</i>  Tools to Tackle Hypocalcemia <i>Chan Siew Pheng</i>  Dietary Calcium and Vitamin D – Are They Enough? <i>Hew Fen Lee</i>	<b>Symposium 3: PAEDIATRIC – DIABETES</b> <i>Chairperson: Ting Tzer Hwu</i>  T2DM and Obesity in Children and Adolescents: Nutritional Intervention <i>Zaridah Zainuri</i>  International Society for Pediatric and Adolescent Diabetes (ISPAD) T1DM 2022 Guidelines. What is New? <i>Muhammad Yazid Jalaludin</i>  Type 1 Diabetes: What is on the Horizon? <i>Azriyanti Anuar Zaini</i>
1150 – 1230	<b>MTE 1: Thickened Pituitary Stalk: Is it Harmful?</b> <i>Azmi Alias</i>	<b>MTE 2: Subclinical Thyroid Diseases Made Easy</b> <i>Mafauzy Mohamed</i>	<b>MTE 3: Genitoplasty in CAH – Early vs Late: The Surgeon Perspective</b> <i>Mohd Yusof Abdullah</i> <i>- Case presentation on Infant and Adolescent with CAH by Noor Arliena</i>
1230 - 1240	<b>Spot It! Challenge</b>		

**Note:**

Spot It! Challenge will take place in Clarke Ballroom and Sentral Ballroom

continue next page

## Programme Detail

Friday - 7<sup>th</sup> July 2023



	Clarke Ballroom	Ballroom B	Ballroom C
1240 - 1340	<p><b>Lunch Symposium</b></p>  <p><b>Abbott</b> A Promise for Life</p> <p><i>Chairperson: Jeyakantha Ratnasingam</i></p> <p>Evidence-Based Approach to a Holistic Diabetes Management</p> <p>Integrating Structured Lifestyle Intervention and CGM in Optimizing Diabetes Management <i>Luqman Ibrahim</i></p> <p>Non-HDL Cholesterol, Why Bother? <i>Jeyakantha Ratnasingam</i></p> <p>Value of Point of Care Testing for Diabetes Management <i>Lim Lee Ling</i></p>	<p><b>Lunch Symposium</b></p>  <p><i>Chairperson: Chan Siew Pheng</i></p> <p>The Legacy Effect of Modern Sulphonylureas: Can We Achieve Targets Early and Safely? <i>Joel Alex Dave</i></p> <p>Case discussion <i>Chan Siew Pheng</i></p>	<p><b>Lunch Symposium</b></p>  <p><i>Chairperson: Ravinjit Kaur</i></p> <p>The Legacy Effect in the Management of Type 2 Diabetes: Step Up Early with DPP-IV Inhibitors <i>Norlaila Mustafa</i></p>
1340 - 1400	<b>Trade Exhibition</b>		
	Clarke Ballroom	Ballroom B + Ballroom C	Sentral Ballroom
1400 - 1440	<p><b>MTE 4: Solving Bizarre TFTs</b> <i>Serena Khoo</i></p>	<p><b>MTE 5: Pitfalls in Hyponatremia Management</b> <i>Nor Azmi Kamaruddin</i></p>	<p><b>MTE 6: Optimising Bone Health in Children with Neurological Disorders</b> <i>Leanne Ward</i></p>
1440 - 1610	<p><b>Symposium 4: ADRENAL</b> <i>Chairperson: Mohamed Badrulnizam Long Bidin</i></p> <p>Wait and Watch Approach in Adrenal Nodule: Possible? <i>Norlela Sukor</i></p> <p>Treatment Options and Barriers in Adrenocortical Carcinoma <i>Subashini Rajoo</i></p> <p>Critical Illness-related Corticosteroid Insufficiency <i>Sharmila Paramasivam</i></p>	<p><b>Symposium 5: OBESITY</b> <i>Chairperson: Barakatun Nisak Mohd Yusof</i></p> <p>Intermittent Fasting: Yay or Nay <i>Geeta Appannah</i></p> <p>Pharmacotherapy for Obesity: Newest and in the Pipeline <i>Rohana Abdul Ghani</i></p> <p>Physical Activity: Benefits Beyond Weight Loss <i>Mohd Nahar Azmi Mohamed</i></p>	<p><b>Symposium 6: PAEDIATRIC – PUBERTAL DISORDERS</b> <i>Chairperson: Noor Shafina Mohd Nor</i></p> <p>Delayed Puberty in Boys – What to Do? <i>Rashdan Zaki Mohamed</i></p> <p>Early Puberty in Girls – To Treat or Not to Treat? <i>Meenal Mavinkurve</i></p> <p>Menstrual Management in Adolescents with Intellectual Disability <i>Ani Amelia Zainuddin</i></p>

continue next page



## Programme Detail

Friday - 7<sup>th</sup> July 2023

	Clarke Ballroom	Ballroom B + Ballroom C	Sentral Ballroom
1610 - 1700	Poster Presentation in Foyer Area	<b>High-Tea Symposium</b>  Chairperson: <i>Hiew Fu Liong</i>  Breaking Barriers in Diabetic Peripheral Neuropathy Management: New Regimen for Nerve Health Restoration <i>Hiew Fu Liong</i> <i>Alexander Tan Tong Boon</i>	<b>High-Tea Symposium</b>   Chairperson: <i>Muhammad Yazid Jalaludin</i>  X-Linked Hypophosphataemic Rickets – A New Treatment Paradigm <i>Craig Munns</i>
1700 - 1800	<b>Trade Exhibition</b>		
1900 - 2200	<b>MEMS Annual Dinner @ The Glass House, Level 8, LeMeridien (exclusively for members only)</b>		

## Programme Detail

Saturday - 8<sup>th</sup> July 2023

	Clarke Ballroom	Ballroom B + Ballroom C	Sentral Ballroom
0730 - 0810	<b>Breakfast Symposium</b>  <i>Chairperson: Nurain Mohd Noor</i>  Women's Journey in the Diabetes Continuum: From Prediabetes to Sweet Pregnancy <i>Chan Siew Pheng</i>		
0810 - 0855	<b>PLENARY 3: Testosterone and Diabetes in Men: Current Concepts and Controversies</b> <i>Bu Yeap</i> <i>Chairperson: Wan Mohamad Wan Bebakar</i>		
0855 - 0915	<b>Special Tribute Dedicated to Allahyarham Prof Dato' Dr Khalid Abd Kadir and Allahyarhamah Prof Dr Rokiah Pendek</b> <i>Tribute by Norlaila Mustafa and Shirenee Ratna Vethakkan</i>		
0915 - 1000	<b>Plenary 4: Dyslipidemia in Children and Adolescents</b> <i>Fabian Yap</i> <i>Chairperson: Janet Hong</i>		
1000 - 1020	<b>Solve the Quiz! / Tea Break / Trade Exhibition</b>		
1020 – 1150	<b>Symposium 7: DIABETES MELLITUS</b> <i>Chairperson: Tong Chin Voon</i>  Type 1 DM versus LADA <i>Vijiya Mala Valayatham</i>  Type 1, Type 2 or Type 3 Diabetes? <i>Florence Tan</i>  TIR versus HbA1c <i>Foo Siew Hui</i>	<b>Symposium 8: PITUITARY</b> <i>Chairperson: Ijaz Hallaj Rahmatullah</i>  Incidentally Found Pituitary Adenoma: What to Do? <i>Jeyakantha Ratnasingam</i>  Clinical Clues to Recognize Acromegaly <i>C Rajasoorya</i>  Does Hyperprolactinemia "Equals" Prolactinoma? <i>Wan Juani Wan Seman</i>	<b>Symposium 9: PAEDIATRIC – GROWTH DISORDERS</b> <i>Chairperson: Lim Song Hai</i>  Growth Disorders in Oncology Survivors <i>Nurshadia Samingan</i>  Growth Hormone Deficiency in Infants – Do They Need Treatment? <i>Jeanne Wong</i>  Growth Hormone Therapy in Russel-Silver and Noonan Syndrome – Efficacy and Safety <i>Arini Nuran Md Idris</i>
1150 - 1230	<b>MTE 7: HIV-Related Endocrinopathies</b> <i>Alexander Tan</i>	<b>MTE 8: Polyuria – Is It Just Diabetes Mellitus?</b> <i>C Rajasoorya</i>	<b>MTE 9: Hypoglycaemic Disorders – From Infancy to Adolescence</b> <i>Suhaimi Hussain</i>
1230 - 1240	<b>Spot It! Challenge</b>		

**Note:**

Spot It! Challenge will take place in Clarke Ballroom and Sentral Ballroom

*continue next page*



## Programme Detail

Saturday - 8<sup>th</sup> July 2023

	Clarke Ballroom	Ballroom B	Ballroom C
1240 - 1340	<p><b>Lunch Symposium</b></p>  <p><i>Chairperson: Rohana Abdul Ghani</i></p> <p>The R factors in Reimagining T2D Management</p> <p>Leading the Innovation the First and Only Ora GLP-1RA and the Only Insulin Co-Formulation <i>Rohana Abdul Ghani</i></p> <p>Oral semaglutide - IGNITE-ing New Possibilities for Early Initiation of GLP-1RA <i>Lim Lee Ling</i></p> <p>Driving Change for Generations Across Patient Treatment Journey <i>Chan Siew Pheng</i></p>	<p><b>Lunch Symposium</b></p>  <p><i>Chairperson: Norlela Sukor</i></p> <p>Diabetes in Malaysia: Unmasking the Sweet Epidemic <i>Norlela Sukor</i></p> <p>The Incretin Axis in Diabetes Management <i>Jonathan Shaw</i></p>	<p><b>Lunch Symposium</b></p>  <p><i>Chairperson: Jeyakantha Ratnasingam</i></p> <p>Gearing Forward: Protecting Kidneys Early in Your T2D Patients <i>Saiful B. Kassim</i></p> <p>CARDiovascular benefits of SGLT2i: Keep the Engine Running in T2D Patients <i>Lee Zhen-Vin</i></p>
1340 - 1400	<b>Trade Exhibition</b>		
	Clarke Ballroom	Ballroom B + Ballroom C	Sentral Ballroom
1400 - 1440	<p><b>MTE 10: Slaying the Dynamic Tests (Interpretation of ARR/SST/AVS/IPSS)</b> <i>Ijaz Hallaj Rahmatullah and Yusniza Yusof</i></p>	<p><b>MTE 11: The Bones, Stones and Moans</b> <i>Norasyikin A. Wahab and Loh Huai Heng</i></p>	<p><b>MTE 12: Orthopaedic Intervention in Children and Adolescents with Osteogenesis Imperfecta: When and What</b> <i>Abdul Halim Abdul Rashid - Case presentation by Annie Leong</i></p>
1440 - 1610	<p><b>Symposium 10: ANDROLOGY</b> <i>Chairperson: Kang Waye Hann</i></p> <p>Hypogonadal Men: Is There Fertility Chances? <i>Mohamed Hatta Tarmizi</i></p> <p>LOH - To Treat or Not to Treat? <i>Yong Sy Liang</i></p> <p>Testosterone, Cardiovascular Health and Male Longevity <i>Bu Yeap</i></p>	<p><b>Symposium 11: ENDOCRINE DISORDERS IN PREGNANCY</b> <i>Chairperson: Noor Lita Adam</i></p> <p>Prenatal Planning for Thyroid Diseases <i>Shireene Ratna Vethakkan</i></p> <p>Hypothyroidism in Pregnancy Simplified <i>Kuan Yueh Chien</i></p> <p>Diabetes During Pregnancy And Beyond <i>Nurain Mohd Noor</i></p>	<p><b>Symposium 12: REPRODUCTIVE ENDOCRINOLOGY</b> <i>Chairperson: Tong Chin Voon</i></p> <p>Advances in PCOS <i>Lim Siang Chin</i></p> <p>Functional Amenorrhoea – Harmless or Harmful? <i>Wong Ming</i></p> <p>Estrogen Replacement and Fertility in Turner Syndrome <i>Lee Yee Lin</i></p>

continue next page

## Programme Detail

Saturday - 8<sup>th</sup> July 2023

	Clarke Ballroom	Ballroom B + Ballroom C	Sentral Ballroom
1610 - 1700	<b>Oral Presentation (Young Investigator Award) Adult</b>	<b>High-Tea Symposium</b>  <b>ZUELLIG PHARMA</b> <small>making healthcare more accessible</small>  <i>Chairperson: Saiful B Kassim</i>  From Burden to Breakthrough: Reinventing the Insulin Journey <i>Lim Lee Ling</i>	<b>Oral Presentation (Young Investigator Award) Paediatric</b>
1700 - 1900	<b>MEMS Annual General meeting (exclusively for members only)</b>		
1900 - 2045	<b>Dinner Symposium</b>  <b>ZUELLIG PHARMA</b> <small>making healthcare more accessible</small>  The Journey and Future of Incretin Therapy for Diabetes Management <i>Chairperson: Zanariah Hussein</i>  Current Landscape of Diabetes in Malaysia <i>Zanariah Hussein</i>  The Journey and Future of Incretin Therapy for Diabetes Management <i>Jonathan Shaw</i>		



## Programme Detail

Sunday - 9<sup>th</sup> July 2023

	Clarke Ballroom	Ballroom B + Ballroom C	Sentral Ballroom
0750 - 0830	<b>Breakfast Symposium</b>  <i>Chairperson: Lim Lee Ling</i> Managing Osteoporosis in Patients with Recent Fractures with Romosozumab – A Case Study from the Falls Clinic <i>Jeyakantha Ratnasingam</i>		
0830 - 1000	<b>Symposium 13: PANCREAS</b> <i>Chairperson: Foo Siew Hui</i> Utilizing EUS in Endocrine Diseases <i>Chen Harn Chin</i> Functioning Pancreatic NETS - The Dos and Don't's <i>Zanariah Hussein</i> Surgical Versus Non-surgical Management of Pancreatic Nodules <i>Krishnan Raman</i>	<b>Symposium 14: DIABETES and CV</b> <i>Chairperson: See Chee Keong</i> Epidemiology of Cardiovascular Complications in Diabetes <i>Jonathan Shaw</i> The Role of Precision Medicine in Cardio-Diabetology <i>Lim Lee Ling</i> Diabetes Remission and Cardiovascular Risk Reduction <i>Michael Lean</i>	<b>Symposium 15: ADOLESCENT ENDOCRINOLOGY</b> <i>Chairperson: Lim Poi Giok</i> Osteoporosis in Adolescents: Role of Bisphosphonate Therapy <i>Craig Munns</i> Hyperandrogenism In Adolescent Females <i>Wu Loo Ling</i> Growth Hormone Deficiency Transition from Childhood to Adulthood <i>Fabian Yap</i>
1000 - 1030	<b>Tea Break / Trade Exhibition</b>		
1030 - 1115	<b>DEBATE: Long-Term ATD versus RAI</b> <i>Azraai Nasruddin vs Malik Mumtaz</i> <i>Chairperson: Chan Siew Pheng</i>		
1115 - 1200	<b>Lunch Symposium</b>  Which Comes First? HbA1c Control or Cardiorenal Protection <i>Chairperson: Alexander Tan</i> The Journey of a Type 2 Diabetes Patient <i>Alexander Tan</i> HbA1c Control or Cardiorenal Protection? <i>Lim Lee Ling</i> Primary Prevention Data of DECLARE for Type 2 Diabetes Patients <i>Juliana Chan</i>		
1200 - 1230	<b>Prize Giving / Closing Ceremony</b>		

## Adult Oral Presentation

Area of Interest	Code	Abstract Title and Author Name
Adrenal	OP_A001	MANAGEMENT OF ADRENAL INSUFFICIENCY DURING RAMADAN FASTING: A SURVEY OF MALAYSIAN ENDOCRINOLOGISTS <i>Nicholas Ken Yoong Hee, Quan Hziung Lim, Sharmila Paramasivam, Lee Ling Lim, Siew Pheng Chan, Shireene Vethakkan, Jeyakantha Ratnasingam</i>
	OP_A002	EXPLORING THE CORTISOL WORMHOLE: A SHORTCUT PREDICTOR FOR SHORT SYNACTHEN TEST OUTCOME IN THE SABAH POPULATION <i>Qin Zhi Lee, Hwee Ching Tee, Kai Xuan Teh</i>
Diabetes Mellitus	OP_A003	COMPARISON OF TITRATION ALGORITHMS IN INSULIN-NAÏVE PATIENTS WITH TYPE 2 DIABETES MELLITUS INITIATED WITH BASAL INSULIN NPH <i>Yi Jiang Chua, Luqman Ibrahim, Shireene Ratna Vethakkan, Jeyakantha Ratnasingam, Lee Ling Lim, Sharmila Paramasivam</i>
	OP_A004	COMPARISON OF THRICE-DAILY PREMIXED HUMAN INSULIN WITH BASAL-BOLUS THERAPY AMONG PATIENTS WITH TYPE 2 DIABETES MELLITUS: A CROSS-OVER STUDY <i>Jamie Hong Im Teoh, Nor Azizah Aziz, Chong Hui Khaw, Shanty Velaiutham, Phei Ching Lim, Shueh Lin Lim</i>
Obesity	OP_A005	THE EFFECT OF DRY INTERMITTENT FASTING ON ANTHROPOMETRIC OUTCOMES AND BODY COMPOSITION AMONG ADULTS WITH OVERWEIGHT AND OBESITY <i>Shazana Rifham Abdullah, Nur Hayati Azizul, Ruziana Mona Wan Mohd Zin, Nur Suffia Sulaiman, Norhayati Mustafa Khalid, Roshan Jahn Mohd Salim Mullahi Jahn, Muhamad Khairul Nazrin Khalil, Norhashimah Abu Seman, Nur Azlin Zainal Abidin, Azizan Ali, You Zhuan Tan, Azahadi Omar, Zamtira Seman, Mohd Fairulnizal Md Noh</i>
Parathyroid/Bone and Calcium Metabolism	OP_A006	EVALUATION OF BONE MINERAL DENSITY AND ASSOCIATION OF FRAX SCORE WITH FRACTURES AND DIABETES: A SINGLE-CENTRE CROSS-SECTIONAL REVIEW <i>Noor Ashikin Ismail, Abdullah Shamsir Abdul Mokti, Low Yen Nee, Carolina Shalini Singarayar, Lim Guat Yee, Chia Yong Kuang, Muhamad Riduan Daud, Dinehs Rao Ramakrishna Rao, Nirmalatiban Parthiban, Lio Jia Yin, Putri Arina Megat Mohamed Zainuddin, Chitra Devi Balasubramaniam, Gowri Chandran, Foo Siew Hui</i>
	OP_A007	FACTORS ASSOCIATED WITH VITAMIN D DEFICIENCY IN PATIENTS WITH TYPE 2 DIABETES MELLITUS <i>Nur Aini Eddy Warman, Fatimah Zaherah Mohamed Shah, Aimi Fadilah Mohamad, Mohd Hazriq Awang, Nur Aisyah Zainordin, Rohana Abdul Ghani</i>



## Adult Physical Poster Presentation

Area of Interest	Code	Abstract Title and Author Name
Adrenal	PP_A001	A SINGLE-CENTRE EXPERIENCE IN UTILIZATION OF MITOTANE AS AN ADJUVANT THERAPY FOR ADRENOCORTICAL CARCINOMA <i>Alyani H, Siti Sanaa WA, Masliza Hanuni MA, Nur Hidayah MM, Hussain M, Nor Hisham M</i>
	PP_A002	COMPUTED TOMOGRAPHY AND ADRENAL VEIN SAMPLING CONCORDANCE RATE IN PATIENTS WITH PRIMARY ALDOSTERONISM: A TERTIARY CENTRE EXPERIENCE <i>Ee Wen Loh, Ridzuan Abdul Rahim, Azraai Bahari Nasruddin</i>
Diabetes Mellitus	PP_A003	LONG-TERM TREATMENT OUTCOMES WITH GLUCAGON LIKE PEPTIDE 1 RECEPTOR AGONIST (GLP-1RA): A REAL LIFE STUDY AT HOSPITAL PUTRAJAYA <i>Vanusha Devaraja, Chee Koon Low, Vijiya Mala Valayatham, Navin Kumar Loganadan, Zanariah Hussein</i>
	PP_A004	A SINGLE-CENTRE, RETROSPECTIVE STUDY ON THE CLINICAL CHARACTERISTICS OF PATIENT WITH TYPE 3 C DIABETES MELLITUS <i>Marisa Khatijah Borhan, Florence Tan Hui Sieng, Kuan Yueh Chien, Chan Pei Lin</i>
	PP_A005	GLYCEMIC CONTROL AND UTILIZATION OF SODIUM-GLUCOSE COTRANSPORTER-2 INHIBITOR AND DIPEPTIDYL PEPTIDASE-2 INHIBITOR THERAPY IN A TERTIARY HOSPITAL DIABETES CLINIC IN PAHANG <i>Nurbadriah Jasmiad, Ilham Ismail, Mimi Syafiqah Mohd Samsudin, Norhaslinda Shamsudin, Nur Azwani Ramli, Zhe Lan Wong, Eileen Tan, Saiful Shahrizal Shudim, Chee Keong See</i>
Parathyroid/Bone and Calcium Metabolism	PP_A006	CLINICAL CHARACTERISTICS AND MANAGEMENT OF PATIENTS WITH SEVERE HYPERCALCEMIA IN HOSPITAL PUTRAJAYA <i>Syarifah Syahirah Syed Abas, Yong Shern Siau, Janaardhan Tinakaran, Shireen Lui Siow Leng, Zanariah Hussein</i>
Pituitary/ Neuroendocrinology	PP_A007	PATIENTS' QUALITY OF LIFE AFTER SWITCHING DESMOPRESSIN FROM TABLET TO SUBLINGUAL LYOPHILIZATE (MELT) FORMULATION: A SINGLE-CENTRE EXPERIENCE <i>Chee Koon Low, Vanusha Devaraja, Azraai Bahari Nasruddin, Zanariah Hussein</i>
	PP_A008	DOPAMINE AGONIST-INDUCED IMPULSE CONTROL DISORDERS IN PATIENTS WITH PROLACTINOMA: A CROSS-SECTIONAL MULTI-CENTRE STUDY <i>Woh Wei Mak, Nurain Mohd Noor, Mohamed Badrulnizam Long Bidin</i>
Thyroid	PP_A009	EVALUATION OF HYPOTHYROID STABILISATION AMONG PATIENTS WITH DIFFERENT DOSES OF LEVOTHYROXINE: A RETROSPECTIVE OBSERVATIONAL REVIEW STUDY <i>Basil Lee Choong Lin, Ernieda Md Hatah, Adyani Md Redzuan</i>
	PP_A010	RADIOACTIVE IODINE THERAPY FOR BENIGN THYROID DISORDERS: EXPERIENCES FROM A TERTIARY CENTRE IN MALAYSIA <i>Muhammad Faiz Che Ros, Samuel Yee Siew Mun, Noor Rafhati Adyani Abdullah</i>
	PP_A011	OPTIMISING TSH RECEPTOR ANTIBODY (TRAB) TESTING IN PREGNANCY: A SINGLE-CENTRE AUDIT <i>Kausalyaa Krishnabalan, Azraai Bahari Nasruddin</i>



## Adult E-Poster Presentation

Area of Interest	Code	Abstract Title and Author Name
Adrenal	EP_A001	BILATERAL GIANT ADRENAL MYELOLIPOMA <i>Noor Hafis Md Tob, Chin Voon Tong, Melissa Vergis, Siow Ping Lee</i>
	EP_A002	FUNCTIONING ADRENOCORTICAL ONCOCYTIC CARCINOMA: A RARE VARIANT <i>Dineash Kumar Kannesan, Teh Roseleen Nadia Roslan, Norhayati Yahaya, Aniza Hassan, Junaidi Awang Isa</i>
	EP_A003	'AN IMPENDING DOOM:' RARE CASE OF RUPTURED PHEOCHROMOCYTOMA PRESENTING AS PHEOCHROMOCYTOMA CRISIS <i>Noor Muhammad Azlan Shah, Prashanya Kannan, Nadia Helena, Dian Noriza, Fadzliana Hanum, Gunavathy Muthusamy</i>
	EP_A004	UNMASKING PRIMARY ALDOSTERONISM IN A PATIENT WITH END STAGE RENAL DISEASE: A CASE REPORT <i>Nurbadriah Jasmiad, Chee Keong See, Saiful Shahrizal Shudim, Ilham Ismail, Zhe Lan Wong, Eileen Tan</i>
	EP_A005	DIABETIC KETOACIDOSIS (DKA) AS A RARE PRESENTATION OF PHEOCHROMOCYTOMA <i>Marisa Masera Marzukie, Norhaliza Mohd Ali</i>
	EP_A006	MAX AND HIS FURY SPELLS: A CASE OF BILATERAL PHEOCHROMOCYTOMA WITH MAX-ASSOCIATED PATHOGENIC GENE MUTATION <i>Chee Koon Low, Kausalyaa Krishnabalan, Azraai Bahari Nasruddin, Zanariah Hussein</i>
	EP_A007	LATERAL APPROACH RETROPERITONEOSCOPIC ADRENALECTOMY: A SINGLE-CENTRE MALAYSIAN EXPERIENCE <i>Loh Chit Sin, Leslie Lai, Faridah Ismail, Saiful Kassim, Lee Chiang Heng, Liao Chee Ming, Thashvinatini Mohanavel</i>
	EP_A008	GERIATRIC ONSET OF PHEOCHROMOCYTOMA <i>Dorothy Maria Anthony Bernard, Yi Jiang Chua, Poh Shean Wong, Zanariah Hussein</i>
	EP_A009	PRIMARY ADRENAL LYMPHOMA WITH PRIMARY ADRENAL INSUFFICIENCY: A CASE REPORT <i>Farhana Ismail, Shamila Sutharsan, Sarah Hani Johari How, Siti Nazifah Md Rozi, Norlaila Mustafa, Norasyikin A. Wahab</i>
Diabetes Mellitus	EP_A010	USE OF PLASMAPHERESIS IN THE MANAGEMENT OF SEVERE HYPERTRIGLYCERIDEMIA IN A PATIENT PRESENTING WITH DKA AND NSTEMI: A CASE REPORT <i>Jie En Tan, Lin Hsin Yong, Huong Yew Ting, Yueh Chien Kuan</i>
	EP_A011	CONFRONTING THE CHALLENGE OF DIABETIC CYSTOPATHY WITH ESBL KLEBSIELLA PNEUMONIAE UROSEPSIS: A COMPLEX CLINICAL CONUNDRUM <i>Siti Nabihah Mohamed Hatta, Mohd Fyzal Bahrudin</i>
	EP_A012	USE OF SGLT2 INHIBITOR IN ALPELISIB-INDUCED HYPERGLYCEMIA <i>Hidayatil Alimi Bin Keya Nordin, Lavanya Jeevaraj, Ijaz Bt Hallaj Rahmatullah</i>
	EP_A013	SEVERE HYPERTRIGLYCERIDEMIA IN A NEWLY DIAGNOSED TYPE 1 DIABETES PATIENT WITH DIABETIC KETOACIDOSIS <i>Sherlyn Lai Hui Ern, Eunice Lau Yi Chwen</i>



## Adult E-Poster Presentation

Area of Interest	Code	Abstract Title and Author Name
Diabetes Mellitus	EP_A014	EUGLYCAEMIC DIABETIC KETOACIDOSIS AS A CAUSE OF REFRACTORY METABOLIC ACIDOSIS IN A PREGNANT PATIENT <i>Siti Sanaa WA, Masliza Hanuni MA, Firdaus MK</i>
	EP_A015	COMPARING DIABETIC KETOACIDOSIS(DKA) ADMISSION AMONG TYPE 2 DIABETIC MELLITUS (T2DM) PATIENTS DURING PRERAMADHAN AND RAMADAN: ASSOCIATED FACTORS, OUTCOME AND SEVERITY <i>Fakruradzi Z, Wan Mohd Izani WM, Najib Majdi Y, Masliza Hanuni MA</i>
	EP_A016	CAN ARTIFICIAL INTELLIGENCE (CHATGPT) REPLACE HEALTHCARE PROVIDERS' WORKLOAD IN MANAGING TYPE 2 DIABETES? <i>Goh Kian Guan, Mohd Syazwan Mohd Amin, Raja Nurazni Raja Azwan</i>
	EP_A017	CASE SERIES OF SEVERE INSULIN RESISTANCE IN HOSPITALIZED PATIENTS <i>Wan Mohd Hafez WH, Norhayati Yahaya, Teh Roseleen Nadia Roslan, Masliza Hanuni MA</i>
	EP_A018	ACQUIRED HYPOALDOSTERONISM WITH RENAL TUBULAR ACIDOSIS TYPE 4 IN A DIABETIC PATIENT <i>Calvin Ooi Gim Seong, Sivasangkari Mugilarasan</i>
	EP_A019	AN AUDIT OF PATIENTS WITH TYPE 1 DIABETES MELLITUS IN RELATION TO GLYCAEMIC CONTROL AND METABOLIC PROFILE IN A TERTIARY CENTRE <i>Shireen Lui Siow Leng, Tishanti Periasamy, Shamharini A/P Nagaratnam, Nurain Binti Mohd Noor, Zanariah Hussein</i>
	EP_A020	SAFETY AND EFFICACY OF DIFFERENT BASAL INSULINS IN TYPE 2 DIABETES MELLITUS WITH CHRONIC KIDNEY DISEASE DURING RAMADAN <i>Nur Haziqah Baharum, Sharifah Faradila Wan Muhamad Hatta, Nur Aisyah Zainordin, Rohana Abd Ghani</i>
	EP_A021	HEMICHOREA IN A NEWLY DIAGNOSED TYPE 2 DIABETIC PATIENT <i>Nur Haziqah Baharum, Nur Aisyah Zainordin, Nur'Aini Eddy Warman, Mohd Hazriq Awang, Aimi Fadilah Mohamad, Fatimah Zaherah Mohamed Shah, Rohana Abd Ghani</i>
	EP_A022	A RARE CASE OF HYPERGLYCEMIA HEMICHOREA IN A NEWLY DIAGNOSED TYPE 1 DIABETES MELLITUS PATIENT <i>Yi Jiang Chua, Zanariah Hussein</i>
	EP_A023	ZAPPING THE ELUSIVE CULPRIT <i>Herng Pin Yam, Siow Ping Lee, Chin Voon Tong</i>
	EP_A024	PROBIOTICS AND INSULIN AUTOIMMUNE SYNDROME <i>Yong Siang Ng, Qing Ci Goh, Woh Wei Mak, Gayathri Devi Krishnan, Yoke Mui Ng, Shazatul Reza Mohd Redzuan, Subashini Rajoo, Mohamed Badrulnizam Long Bidin</i>
	EP_A025	COVID 19 PANDEMIC AND VIRTUAL CLINIC FOR DIABETIC CARE: A SINGLE-CENTRE EXPERIENCE <i>Sazuan S, Ida IA, Yusniza Y</i>



## Adult E-Poster Presentation

Area of Interest	Code	Abstract Title and Author Name
Obesity	EP_A026	A GRIM TURN OF OBESITY-RELATED SURGERY: WERNICKE'S ENCEPHALOPATHY, SLEEVE GASTRECTOMY GONE WRONG <i>Mohd Fyzal Bahrudin, Sanusi Zulkifli</i>
	EP_A027	BASELINE CHARACTERISTICS OF PARTICIPANTS IN THE MOLECULAR, METABOLIC AND NUTRITIONAL CHANGES AFTER METABOLIC SURGERY IN OBESE DIABETIC PATIENTS (MOMEN) STUDY <i>Liyana Ahmad Zamri, Nur Azlin Zainal Abidin, Farah Huda Mohkiar, You Zhuan Tan, Fazliana Mansor, Poh Yue Tsen, Shu Yu Lim, Gee Tikfu</i>
	EP_A028	BASELINE BODY COMPOSITION OF OBESE INDIVIDUALS ACCORDING TO DIABETES STATUS IN MALAYSIA <i>Nur Azlin Zainal Abidin, Farah Huda Mohkiar, Liyana Ahmad Zamri, You Zhuan Tan, Fazliana Mansor, Poh Yue Tsen, Shu Yu Lim, Gee Tikfu</i>
	EP_A029	THE PREVALENCE OF THYROID DISORDERS AMONG OVERWEIGHT AND OBESITY PATIENTS IN SINGLE-CENTRE <i>Mohd Fyzal Bahrudin, Ooi Chuan Ng</i>
	EP_A030	THE PREVALENCE OF PRE-DIABETES AND DIABETES AMONG OVERWEIGHT AND OBESITY PATIENTS IN A SINGLE-CENTRE <i>Mohd Fyzal Bahrudin, Ooi Chuan Ng</i>
Others	EP_A031	LOCAL EXPERIENCE OF TOLVAPTAN IN THE MANAGEMENT OF INPATIENTS WITH SIADH <i>Jia Miin Sun, Azraai Bahari Nasruddin</i>
	EP_A032	ENDOCRINOPATHIES IN ADULT PATIENTS WITH TRANSFUSION-DEPENDENT THALASSEMIA IN HOSPITAL SULTANAH BAHIIYAH <i>LW Wong, Nor Shaffinaz Yusoff Azmi Merican, Noor Rafhati Adyani Abdullah, Norasmidar Aziz, Shartiyah Ismail</i>
	EP_A033	SUCCESSFUL PREGNANCY IN HOMOZYGOUS FAMILIAL HYPERCHOLESTEROLEMIA PATIENT REQUIRING LIPID APHERESIS AND MULTIDISCIPLINARY TEAM MANAGEMENT <i>Siau Chenn Khong, Ashcwiniswarie Gunasegaran, Nurul Atikah Hamza, Hazwani Aziz, Sadanah Aqashiah Mazlan, Elliyin Katiman</i>
	EP_A034	THE USE OF THERAPEUTIC PLASMA EXCHANGE IN A PATIENT WITH RECURRENT SEVERE HYPERTRIGLYCERIDEMIA-INDUCED ACUTE PANCREATITIS <i>Wei Wei Ng, Wai Leong Liew</i>
	EP_A035	HEPATOMA-INDUCED NON-ISLET CELL TUMOR HYPOGLYCEMIA: A CASE REPORT <i>Jen Hoong Oon, Yon Li Ho, Chin Voon Tong, Noor Hafis Md Tob, Siow Ping Lee, Melissa Vergis</i>
	EP_A036	RENINOMA: A SURGICALLY CURABLE CAUSE OF HYPERTENSION <i>Gaayathri Krishnan</i>



## Adult E-Poster Presentation

Area of Interest	Code	Abstract Title and Author Name
Parathyroid/Bone and Calcium Metabolism	EP_A037	A BONY PREDICAMENT: CATCHING THE CULPRIT IN THE CHEST <i>Quan Hziung Lim, Nicholas Ken Yong Hee, Ken Seng Chiew, Marisa Khatijah Borhan, Katherine Khor, Ee Wen Loh, Tharsini Sarvanandan, Sharmila Paramasivam, Lee Ling Lim, Jeyakantha Ratnasingam, Siew Pheng Chan, Shireene Ratna Vethakkan</i>
	EP_A038	PRIMARY HYPERPARATHYROIDISM IN PREGNANCY, INITIAL PRESENTATION WITH HYPOCALCAEMIA SECONDARY TO ACUTE PANCREATITIS AND SEPSIS <i>Alvin Gnanasegaran, Sivasangkari Mugilarassan</i>
	EP_A039	A CHALLENGING CASE OF FAMILIAL HYPOCALCIURIC HYPERCALCEMIA CONCEALED BY CONCOMITANT VITAMIN D DEFICIENCY AND PAPILLARY THYROID CARCINOMA <i>Vanusha Devaraja, Shazatul Reza Mohd Redzuan, Subashini Rajoo</i>
	EP_A040	TERIPARATIDE [HUMAN PARATHYROID HORMONE (PTH) 1-34] FOR THE MANAGEMENT OF POST THYROIDECTOMY HYPOCALCEMIA EXACERBATED BY CHYLE LEAK <i>Ken Seng Chiew, Quan Hziung Lim, Nicholas Ken Yoong Hee, Sharmila Paramasivam, Lee Ling Lim, Jeyakantha Ratnasingam, Shireene Vethakkan</i>
	EP_A041	OSTEOMALACIA SECONDARY TO RENAL TUBULAR ACIDOSIS TYPE 1 WITH VITAMIN D DEFICIENCY <i>Lavanya Jeevaraj, Anilah Bt AR Rahman, Ijaz Bt Hallaj Rahmatullah</i>
	EP_A042	A RARE CASE OF PREGNANCY LACTATION-INDUCED OSTEOPOROSIS <i>Wan Mohd Hafez WH, Norhayati Yahaya, Teh Roseleen Nadia Roslan</i>
	EP_A043	THE CURIOUS CASE OF THE HIDDEN PARATHYROID GLAND: TWO CASE SERIES <i>Nur Hidayah MM, Masliza Hanuni MA, Siti Sanaa WA</i>
	EP_A044	PARATHYROID CARCINOMA PRESENTING AS PRIMARY HYPERPARATHYROIDISM IN ADOLESCENCE <i>Thamarai Supramaniam, Siti Aishah Mahamad Dom</i>
	EP_A045	COVID-19 MOVEMENT CONTROL ORDER RELATED OSTEOPOROTIC FRACTURE AND VITAMIN D DEFICIENCY IN AN ADOLESCENT MALE <i>Suhasheni Rajendran, Chu Ee Seow, Jerri Chiu Yun Ling, Hui Chin Wong</i>
Pituitary/ Neuroendocrinology	EP_A046	A RARE CASE OF NONFUNCTIONING APPENDICEAL NEUROENDOCRINE TUMOUR (ANET) WITH BASE INVOLVEMENT NEEDING HEMICOLECTOMY <i>Abdullah Shamshir Abd Mokti, Raja Nurazni Raja Azwan</i>
	EP_A047	PEMBROLIZUMAB-INDUCED HYPOPHISITIS IN A PATIENT WITH UNDERLYING HYPOTHYROIDISM PRESENTING AS ADRENAL CRISIS: A CASE REPORT <i>Abdullah Shamshir Abd Mokti, Raja Nurazni Raja Azwan</i>



## Adult E-Poster Presentation

Area of Interest	Code	Abstract Title and Author Name
Pituitary/ Neuroendocrinology	EP_A048	HYPONATREMIA AND TSHoma: THE ODD COUPLE <i>Quan Hziung Lim, Nicholas Ken Yong Hee, Ken Seng Chiew, Marisa Khatijah Borhan, Katherine Khor, Ee Wen Loh, Tharsini Sarvanandan, Sharmila Paramasivam, Lee Ling Lim, Jeyakantha Ratnasingam, Siew Pheng Chan, Shireene Ratna Vethakkan</i>
	EP_A049	GIANT PITUITARY MACROADENOMA MASKED BY BILATERAL RETINAL DETACHMENT <i>Joel Xiang Loong Lee, Jen Hoong Oon, Noor Hafis Md Tob, Chin Voon Tong, Melissa Verghis, Siow Ping Lee</i>
	EP_A050	RESOLUTION OF CYSTIC MACROPROLACTINOMA WITH DOPAMINE AGONIST THERAPY <i>Goh Qing Ci, Loh Yee Wen, Ng Yong Siang, Mak Woh Wei, Gayathri Devi A/P Krishnan, Ng Yoke Mui, Shazatul Reza Binti Mohd Redzuan, Subashini A/P Rajoo, Mohamed Badrulnizam Long Bidin</i>
	EP_A051	ENDOSCOPIC ULTRASOUND-GUIDED RADIOFREQUENCY ABLATION USED IN THE TREATMENT OF INSULINOMA <i>Wei Wei Ng, Xe Hui Lee, Anilah Bt Abdul Rahim, Ijaz Binti Hallaj Rahmatullah</i>
	EP_A052	SUCCESSFUL RESOLUTION OF THYROID STORM FROM TSHoma WITH SOMATOSTATIN RECEPTOR LIGAND <i>Ken Seng Chiew, Quan Hziung Lim, Nicholas Ken Yoong Hee, Sharmila Paramasivam, Lee Ling Lim, Shireene Vethakkan, Jeyakantha Ratnasingam</i>
	EP_A053	PITUITARY METASTASIS: A RARE PRESENTATION OF SMALL CELL LUNG CANCER <i>Meng Loong Mok, Shu Teng Chai, Vivithirah K. Arjunan Roy, Norsarah Shamsudin</i>
	EP_A054	METYRAPONE AS A BRIDGING THERAPY IN FLORID CUSHING'S DISEASE PATIENT PRIOR TO PITUITARY ADENOMECTOMY <i>Muhamad Shafiq MY, Siti Sanaa WA, Masliza Hanuni MA, Nur Hidayah MM</i>
	EP_A055	UNCOMMON CAUSE OF SECONDARY EMPTY SELLA SYNDROME <i>Sharifah Noor Adrilla binti Long Mohd Noor Affendi, Mohd Sofi Hafizi bin Sarip @ Ma'arof, Noor Lita binti Adam, Nor Afidah binti Karim</i>
	EP_A056	USTEKINUMAB-INDUCED HYPOPHYSITIS IN CROHN'S DISEASE: A CASE REPORT <i>Tharsini Sarvanandan, Ken Seng Chiew, Shireene Vethakkan, R.Jeyakantha Ratnasingam, Lee-Ling Lim, Quan Hziung Lim, Nicholas Ken Yoong Hee, Sharmila Paramasivam</i>
	EP_A057	A RARE CASE OF MICROPROLACTINOMA AND GRANULOMATOUS MASTITIS <i>Kai Xuan Teh, Joon Hi Tham, Ann Feng Pan, Hwee Ching Tee, Jin Hui Ho</i>
EP_A058	FASTING AND POSTPRANDIAL HYPOGLYCEMIA IN AN ADOLESCENT PRESENTING WITH ENDOGENOUS HYPERINSULINEMIC HYPOGLYCEMIA LIKELY INSULINOMA: A CASE REPORT <i>Nashriq Khan Bin Adam Khan, Noor Rafhati Adyani Abdullah</i>	



## Adult E-Poster Presentation

Area of Interest	Code	Abstract Title and Author Name
Pituitary/ Neuroendocrinology	EP_A059	LONG STANDING ACROMEGALY WITH PERSISTENT DISEASE RESPONSE TO PASIREOTIDE: A CASE REPORT <i>Eileen Tan, Chee Keong See, Saiful Shahrizal Shudim, Ilham Ismail, Nurbadriah Jasmiad, Zhe Lan Wong, Subashini Rajoo, Mohamad Badrulnizam Long Bidin, Xin-Yi Ooi</i>
	EP_A060	ATYPICAL PRESENTATION OF FUNCTIONING MALIGNANT METASTATIC PARAGANGLIOMA WITH RECURRENT MYASTHENIA CRISIS <i>Nur Hidayah MM, Masliza Hanuni MA, Siti Sanaa WA, Khairul Azmi, Hadzfadzila MU, Mohd Noor I</i>
	EP_A061	APOPLEXY IN MICROPROLACTINOMA <i>Zhe Lan Wong, Eileen Tan, Ilham Ismail, Nurbadriah Jasmiad, Chee Keong See, Saiful Shahrizal Shudim</i>
	EP_A062	A RARE CASE OF TOTAL LEFT ANTERIOR CIRCULATION INFARCT (TACI) SECONDARY TO THYROTROPINOMA (TSHoma) TREATED WITH MEDICAL THERAPY OCTREOTIDE <i>Yi Jiang Chua, Choon Peng Sun, Zanariah Hussein</i>
	EP_A063	A CASE OF GIANT INVASIVE MACROPROLACTINOMA PRESENTING AS A NASOPHARYNGEAL MASS <i>Li Sin Yeh, Chan Pei Lin, Florence Tan Hui Sieng</i>
	EP_A064	TSHoma: A CASE OF MISTAKEN IDENTITY <i>Chong Li Ren Albert, Chan Pei Lin, Florence Tan Hui Sieng</i>
	EP_A065	PITUITARY MACROADENOMA MIMICRY: A CASE REPORT <i>Nurqystina Binti Ahmad Senusi, Syahrizan Binti Samsuddin</i>
Reproductive Endocrinology	EP_A066	DIAGNOSTIC AND THERAPEUTIC UTILITY OF GONADOTROPHIN-RELEASING HORMONE AGONIST IN POSTMENOPAUSAL HYPERANDROGENISM OF OVARIAN ORIGIN <i>Muhammad Qyairil Anwar Che Zainol, Rosliza Shafie, Noor Rafhati Adyani Abdullah</i>
	EP_A067	ANDROGEN-SECRETING OVARIAN STEROID CELL TUMOR: A RARE CASE OF POSTMENOPAUSAL HIRSUTISM AND POLYCYTHEMIA <i>Jing Li Lim, Hwee Ching Tee, Jin Hui Ho, Joon hi Tham</i>
	EP_A068	GELLER SYNDROME: A RARE CASE OF HYPOKALAEMIA IN PREGNANCY <i>Mas Suria</i>
	EP_A069	ANDROGEN INSENSITIVITY SYNDROME WITH METABOLIC SYNDROME: A CHALLENGE IN BALANCING THE HORMONES <i>Fatimah Zaherah Mohamed Shah, Mohd Hazriq Awang, Nur'Aini Eddy Warman, Nur Aisyah Zainordin, Aimi Fadilah Mohamad, Rohana Abdul Ghani</i>
	EP_A070	VAN WYK-GRUMBACH SYNDROME: A CHILD WITH MENSTRUATION <i>Gerard Jason Mathews, Teh When Yee, Seetha Devi Subramaniam, Joel Mathews, Nor Shaffinaz Yusoff Azmi Merican, Noor Rafhati Adyani Abdullah, Shartiyah Ismail</i>



## Adult E-Poster Presentation

Area of Interest	Code	Abstract Title and Author Name
Thyroid	EP_A071	SYNDROME OF RESISTANCE TO THYROID HORMONE <i>Tan Jia Miao</i>
	EP_A072	THE SILENT ATTACK: PANCYTOPENIA AS AN ATYPICAL PRESENTATION OF HASHITOXICOSIS PHASE OF HASHIMOTO'S DISEASE <i>Siti Nabihah Mohamed Hatta, Mohd Fyzal Bahrudin, Zahira Zohari</i>
	EP_A073	OVERT HYPOTHYROIDISM COMPLICATED BY STROKE IN A YOUNG PREGNANT WOMAN <i>Noor Amirah Mohd Hairani, Mohd Fyzal Bahrudin, Ooi Chuan Ng</i>
	EP_A074	ACUTE MYOCARDIAL INFARCTION MASKING THYROTOXICOSIS IN PREGNANCY <i>Nur Hidayah MM, Masliza Hanuni MA, Sini Sanaa WA</i>
	EP_A075	SEEING BLUES ALL AROUND: A CASE OF PROPYLTHIOURACIL-INDUCED CYANOPSIA <i>Noor Hafis Md Tob, Chin Voon Tong, Joel Xiang Loong Lee, Siow Ping Lee, Melissa Vergis</i>
	EP_A076	MYXEDEMA ASCITES: A RARE INITIAL PRESENTATION OF HASHIMOTO THYROIDITIS <i>Sanmuga Vimalanathan, Sivasangkari Mugilarassan</i>
	EP_A077	A RARE PRESENTATION OF SYMPTOMATIC COMPLETE HEART BLOCK IN A MILDLY HYPERTHYROID PATIENT <i>Alia Anis Y, Masliza Hanuni MA, Siti Sanaa WA, Ahmad Wazi R</i>
	EP_A078	THE INNOCENT CARBIMAZOLE <i>Wee Mee Cheng, Yueh Chien Kuan, Qi Ji Lai, Sharifah Aishah bt Wan Mohamad Akbar</i>
	EP_A079	SEVERE MARROW APLASIA SECONDARY TO CARBIMAZOLE <i>Nur Adani Ishak, Elliyyin Katiman, Hazwani Aziz</i>
	EP_A080	SUCCESSFUL TREATMENT OF HYPOTHYROIDISM WITH RECTAL LEVOTHYROXINE: A CASE REPORT <i>Woh Wei Mak, Yong Siang Ng, Qing Ci Goh, Gayathri Devi Krishnan, Yoke Mui Ng, Shazatul Reza Mohd Redzuan, Subashini Rajoo, Mohamed Badrulnizam Long Bidin</i>
	EP_A081	A CASE OF TRIPTORELIN-INDUCED THYROIDITIS <i>Marisa Khatijah Borhan, Shirenee Ratna Vethakkan, Jeyakantha Ratnasingam, Lee-Ling Lim, Sharmila Sunita Paramshivam</i>
	EP_A082	ONE-YEAR AUDIT OF PATIENTS ADMITTED WITH THYROID DISORDERS TO THE MEDICAL DEPARTMENT, SIBU HOSPITAL <i>Lau Pei Ying, Lai Shu Xian, Eunice Lau Yi Chwen</i>
	EP_A083	RETROSPECTIVE ANALYSIS AND EVALUATION OF SPECIALISED MULTIDISCIPLINARY THYROID EYE SERVICES IN A TERTIARY CENTRE IN MALAYSIA <i>Tan Ying Jie, Teh When Yee, Tan Yi Shan, Chai Huei Xian, Adlina Abdul Rahim, Noor Rafhati Adyani Abdullah</i>
	EP_A084	TROCHANTERIC FEMUR FRACTURE UNRAVELS FUNCTIONAL METASTATIC FOLLICULAR THYROID CARCINOMA: CASE REPORT <i>Ilham Ismail, Chee Keong See, Saiful Shahrizal Shudim, Nurbadriah Jasmiad, Zhe Lan Wong, Eileen Tan</i>



## Adult E-Poster Presentation

Area of Interest	Code	Abstract Title and Author Name
Thyroid	EP_A085	THE CONUNDRUM OF RADIOACTIVE IODINE TREATMENT IN CONCOMITANT DIFFERENTIATED THYROID CARCINOMA AND GRAVES' OPTHALMOPATHY <i>Ee Wen Loh, Shireene Ratna Vethakkan, Jeyakantha Ratnasingam, Lee-Ling Lim, Quan Hziung Lim, Nicholas Ken Yoong Hee, Sharmila Sunita Paramasivam</i>
	EP_A086	MYELODYSPLASTIC SYNDROME AND GRAVES' DISEASE <i>Yong Siang Ng, Qing Ci Goh, Woh Wei Mak, Gayathri Devi Krishnan, Yoke Mui Ng, Shazatul Reza Mohd Redzuan, Subashini Rajoo, Mohamed Badrulnizam Long Bidin</i>
	EP_A087	THE CALM BEFORE THE STORM AND THE STORM BEFORE THE CALM: A CASE OF RETRACTABLE THYROID STORM, CAN YOU TELL IF THE STORM IS OVER? <i>Mohd Hazriq A, Aimi Fadilah M, Nur Aini EW, Aisyah Z, Fatimah Zaherah MS, Rohana AG</i>
	EP_A088	ATRIAL FLUTTER IN HYPERTHYROIDISM: ACHIEVING EARLY RHYTHM CONTROL <i>M Razi Zulkufli, HKR Subbarao, Mohd Syafiq MS, Salbiah S, Rafizi Mohamed Rus</i>
	EP_A089	PERSISTENT VOMITING AS PRESENTATION OF THYROTOXICOSIS: A CASE REPORT <i>Chee Keong Seow, Chin Voon Tong</i>
	EP_A090	REFRACTORY HYPOTHYROIDISM POST-CHOLECYSTECTOMY SUCCESSFULLY TREATED WITH SOFTGEL CAPSULE THYROXINE <i>Seetha Devi Subramanian, Gerard Jason Mathews, Teh When Yee, Nor Shaffinaz Yusoff Azmi Merican, Noor Rafhati Adyani Abdullah, Shartiyah Ismail</i>
	EP_A091	INCREASED LEVOTHYROXINE REQUIREMENT IN A PATIENT WITH NEPHROTIC SYNDROME <i>Chong Yee Chua, Azraai Nasruddin</i>



## Basic Science Oral Presentation

Code	Abstract Title and Author Name
OP_B001	DECREASED PTX3 DNA METHYLATION LEVELS ARE ASSOCIATED WITH DIABETIC NEPHROPATHY IN MALE PATIENTS <i>Norhashimah Abu Seman, Wan Nazaimoon Wan Mohamud, Harvest F. Gu</i>
OP_B002	ASSOCIATION OF THADA, LHCGR, DENND1 A, CYP17 A1 AND FSHR GENE POLYMORPHISMS IN INFERTILE MALAY WOMEN WITH PCOS <i>Mariam Ahmed Abdelbadie Mohamed, Habibah Abdul Hamid, Ling King Hwa</i>

## Basic Science Physical Poster Presentation

Code	Abstract Title and Author Name
PP_B001	DIABETIC AUTOANTIBODY TESTING IN MALAYSIA: TIME FOR A PARADIGM CHANGE <i>Saraswathy Apparow, Ker Yang Chua, Poi Giok Lim, Vengketeswara Rao Seetharaman, Shamharini Nagaratnam, Janet Yeow Hua Hong</i>

## Basic Science E-Poster Presentation

Code	Abstract Title and Author Name
EP_B001	NIRMATRELVIR/RITONAVIR-INDUCED HYPONATREMIA PRESENTING WITH SIADH AND GASTROINTESTINAL LOSS: A CASE REPORT <i>Reemarachna P, Suprhamanyam E, Subashini R</i>
EP_B002	INHIBITION OF LIPID ACCUMULATION AND UPREGULATION OF BROWNING GENES BY SIRT1 ACTIVATION IN 3T3-L1 CELLS <i>Siti Sarah Hamzah, Liyana Ahmad Zamri, Norhashimah Abu Seman, Shazana Rifham Abdullah</i>
EP_B003	CENTRAL DIABETES INSIPIDUS WITH COVID-19 PNEUMONIA: A CASE REPORT <i>Suprhamanyam E, Subashini R, Leong CL</i>
EP_B004	IMPACT OF COVID-19 ON THE INCIDENCE OF NEWLY DIAGNOSED TYPE 1 DIABETES MELLITUS: A SINGLE-CENTRE EXPERIENCE <i>Amira Yasmin Mohamed Zaini, Syarifah Nursyazana Syed Ridzuan, Alexis Anandas Lordudass, Azriyanti Anuar Zaini, Nurshadia Samingan</i>
EP_B005	DOES THE INCIDENCE OF DIABETIC KETOACIDOSIS IN PATIENTS WITH TYPE 1 DIABETES MELLITUS DIFFER DURING COVID-19 PANDEMIC? <i>Syarifah Nursyazana Syed Ridzuan, Amira Yasmin Mohamed Zaini, Alexis Anandas Lordudass, Azriyanti Anuar Zaini, Nurshadia Samingan</i>
EP_B006	INSULIN ANTIBODY MEASUREMENTS: SHEDDING LIGHT ON HIRATA'S DISEASE <i>Saraswathy Apparow, Chin Voon Tong, Chee Koon Low, Hui Chin Wong, Sy Liang Yong</i>
EP_B007	HYPERGLYCAEMIA-INDUCED MOVEMENT DISORDER <i>Nor Afifah Ibrahlim, Sanihah Abdul Halim, Wan Izani Wan Mahmood</i>



## Paediatrics Oral Presentation

Code	Abstract Title and Author Name
OP_P001	NEW ONSET DIABETES BEFORE AND DURING COVID-19 PANDEMIC AND FACTORS ASSOCIATED WITH DIABETIC KETOACIDOSIS IN SELECTED TERTIARY HOSPITALS <i>Fatin Fariyah Wan Ahmad Nasir, Muhammad Yazid Jalaludin, Azriyanti Anuar Zaini, Nalini Selveindran, Poi Giok Lim, Yee Lin Lee</i>
OP_P002	PAEDIATRIC GRAVES' DISEASE AND FACTORS IN A SINGLE TERTIARY CENTRE <i>Shi Hui Saw, Nalini M Selveindran, Janet Yeow Hua Hong</i>
OP_P003	SOCIETAL JUDGEMENTS OF PHYSICAL APPEARANCE IN RELATION TO FOOD BEHAVIOUR, PHYSICAL ACTIVITIES, SMOKING AND INTERNET USE IN ADOLESCENTS SEEN IN PAEDIATRIC OBESITY AND DIABETES CLINIC <i>Balqis Nur Sabrina Affendi, Hakima Muhamad Ali, Nur Aimi Nabilah Zanalabidin, Azriyanti Anuar Zaini</i>
OP_P004	MENTAL HEALTH CONCERNS IN RELATION TO BULLYING, FEELINGS AND FRIENDSHIP, EMOTIONAL DISTURBANCES IN HOME AND SCHOOL, AMONG ADOLESCENTS SEEN IN THE PAEDIATRIC OBESITY AND DIABETES CLINIC <i>Hakima Muhamad Ali, Balqis Nur Sabrina Affendi, Nur Aimi Nabilah Zanalabidin, Azriyanti Anuar Zaini</i>
OP_P005	OUTCOME OF CONGENITAL HYPERINSULINISM (CHI): A SINGLE-CENTRE EXPERIENCE <i>Mazidah Noordin, Hajime Miyagi, Mizuho Igarashi, Takemoto Kashima, Akiko Fujioka, Nagisa Ujita, Keisuke Yoshii, Yasuhiro Naiki, Reiko Horikawa</i>

## Paediatrics Physical Poster Presentation

Code	Abstract Title and Author Name
PP_P001	PREVALENCE AND RISK FACTORS OF ENDOCRINE DISORDER IN CHILDHOOD BRAIN TUMOR SURVIVORS : A SINGLE-CENTRE STUDY <i>Nurul Wahidah Ramezan, Suhaimi Hussain, Norsarwany Mohamad, Najib Majdi Yaacob</i>
PP_P002	CLINICAL CHARACTERISTICS AND OUTCOMES OF PAEDIATRIC TYPE 2 DIABETES IN HOSPITAL PUTRAJAYA <i>Siti Salamah Mohd Idris, Janet Hong Yeow Hua, Nalini M.Selveindran</i>
PP_P003	IMPACT OF THE COVID 19 PANDEMIC ON GLYCAEMIC CONTROL, BODY MASS INDEX AND LIFESTYLE CHANGES IN CHILDREN AND ADOLESCENT PATIENTS WITH DIABETES MELLITUS IN STATE OF NEGERI SEMBILAN <i>Mastura Ibrahim</i>
PP_P004	REVIEW OF HYPOPHOSPHATEMIC RICKETS IN HOSPITAL PUTRAJAYA <i>Shi Hui Saw, Nalini M Selveindran, Tzer Hwu Ting, Karupiah Thilakavathy, Janet Yeow Hua Hong</i>
PP_P005	SUCCESSFUL TRANSITION CARE FOR ADOLESCENT AND YOUNG ADULTS WITH DIABETES: A SINGLE-CENTRE EXPERIENCE AND REPORT <i>Qiao Yun Lee, Noor Azleen Ambak, Alexander Tong Boon Tan, Luqman Ibrahim, Azriyanti Anuar Zaini</i>



## Paediatrics E-Poster Presentation

Code	Abstract Title and Author Name
EP_P001	THYROID HORMONE RESISTANCE SYNDROME (THR): A CASE REPORT <i>W Mohd Hilmi bin W. Omar, Jia Cheng Ong, Suhaimi Hussain</i>
EP_P002	A RARE CASE OF NEONATAL DIABETES WITH INSULIN GENE (INS) MUTATION: A CASE REPORT <i>Michael Pook Sow Zhung, L Alexis Anand, Arini Nuran Idris, Lim Poi Giok</i>
EP_P003	ZOLEDRONIC ACID THERAPY FOR MONO-OSTOTIC LANGERHANS CELL HISTIOCYTOSIS: A CASE REPORT <i>Pian Pian Tee, Wei Li Cindy Ho</i>
EP_P004	CASE REPORT: MUCOLIPIDOSIS BONE DISEASE RESEMBLING NEONATAL RICKETS <i>Jian Ann Boo, Sze Teik Teoh, Eric Boon Kuang Ang</i>
EP_P005	CASE REPORT: VAN WYK-GRUMBACH SYNDROME: HYPOTHYROIDISM PRESENTING AS PRECOCIOUS PUBERTY <i>Hazirah Ahmad</i>
EP_P006	CASE REPORT: EXOGENOUS CUSHING SYNDROME IN A GROWING CHILD FOLLOWING CHRONIC TOPICAL STEROIDS FOR FAMILIAL PSORIASIS <i>Tsae Yun Tan</i>
EP_P007	STEROID-RESPONSIVE ENCEPHALOPATHY ASSOCIATED WITH AUTOIMMUNE THYROIDITIS: THE OUTCOME OF NEUROLOGICAL AND THYROID STATUS <i>Jen Ern Tan, Joyce Soo Synn Hong, Sau Wei Wong</i>
EP_P008	TRIPLE-A SYNDROME: A RARE PRESENTATION OF ADRENAL INSUFFICIENCY <i>Muhamad Ideris Othman, Song Hai Lim, Janaeni Vethaguru</i>
EP_P009	AUTOSOMAL DOMINANT, NON AUTOIMMUNE, CONGENITAL HYPERTHYROIDISM <i>Vivian Lai How Mun, Janet Hong Yeoh Hua, Nalini M Selveindran</i>
EP_P010	DIABETIC KETOACIDOSIS WITH MELIROIDOSIS: A CASE REPORT <i>Nur Syafiqah Hamizi, Jia Jian Tang, Qiao Yun Lee, Mia Tuang Koh, Anna Marie Nathan, Siti Zarina Yaakop, Muhammad Yazid Jalaludin, Azriyanti Anuar Zaini, Nurshadia Samingan</i>
EP_P011	HASHIMOTO'S THYROIDITIS WITH SYSTEMIC INVOLVEMENT: A CASE REPORT <i>Jia Jian Tang, Qiao Yun Lee, Nur Syafiqah Hamizi, Nurshadia Samingan, Azriyanti Anuar Zaini, Muhammad Yazid Jalaludin</i>
EP_P012	A CASE OF CHILDHOOD ADRENOCORTICAL TUMOR: A TICKING TIME BOMB <i>Sin Toun Loh, Poi Giok Lim, Arini Nuran Idris, Mohd Yusof Abdullah, Mohd Yusran Othman, Kok Hoi Teh, Hui Hui Siah</i>
EP_P013	CONGENITAL HYPOTHYROIDISM IN A TWIN MISSED BY NEWBORN SCREENING: A CASE REPORT <i>Shemalatha Kejendaram, Ting Tzer Hwu, Lee Yee Lin</i>
EP_P014	CHALLENGES OF INITIATING GROWTH HORMONE THERAPY IN TURNER SYNDROME WITH CHIARI MALFORMATION: A FOLLOW UP REPORT <i>Amir Hamzah Maju AS, Muntari MI, Noordin M, Mohd Nor NS</i>
EP_P015	A CASE OF NON-CLASSICAL CONGENITAL ADRENAL HYPERPLASIA (NCCAH) PRESENTING WITH CENTRAL PRECOCIOUS PUBERTY <i>Mazidah Noordin, Abdul Salam Amir Hamzah Maju, Noor Shafina Mohd Nor</i>
EP_P016	A CASE OF AUTOSOMAL DOMINANT OSTEOPETROSIS TYPE 2 WITH A CLCN7 GENE MUTATION <i>Banumathy R, Nalini M Selveindran, Shi-Hui Saw, Noor Arliena Mat Amin, Janet Yeow Hua Hong</i>



## Adult Oral Presentation

### OP\_A001

#### MANAGEMENT OF ADRENAL INSUFFICIENCY DURING RAMADAN FASTING: A SURVEY OF MALAYSIAN ENDOCRINOLOGISTS

<https://doi.org/10.15605/jafes.038.S2.01>

**Nicholas Ken Yoong Hee, Quan Hziung Lim, Sharmila Paramasivam, Lee Ling Lim, Siew Pheng Chan, Shireene Vethakkan, Jeyakantha Ratnasingam**

*Endocrine Unit, Department of Medicine, Universiti Malaya, Kuala Lumpur, Malaysia*

#### INTRODUCTION

The management of adrenal insufficiency (AI) in Muslim patients fasting during Ramadan poses a challenge for endocrinologists. As the afternoon dose of hydrocortisone needs to be omitted, most guidelines recommend converting twice daily hydrocortisone to once daily, dose equivalent prednisolone, but this is not standard practice.

#### METHODOLOGY

An online survey was disseminated amongst all endocrinologists and endocrinology trainees in Malaysia.  
<https://forms.gle/XR629nBjMu4XWM6HA>.

#### RESULT

There was a total of 91 respondents, consisting of adult endocrinologists (58.2%) and endocrinology trainees (41.8%). Among these physicians, 84.6% treated more than 10 patients with AI in a year, with 34.1% of respondents estimating that more than half of their patients were Muslim. Hydrocortisone was the most common formulation (91.2%) during non-fasting months. According to 70.3% of respondents, Ramadan would have a definite effect on glucocorticoid replacement therapy. Respondents detected fatigue as the most common symptom encountered by AI patients during Ramadan (92.3%), followed by dizziness (90.1%), hypoglycaemia (85.7%), hypotension (81.3%), nausea (74.7%) and weight loss (45.1%). Late afternoon was considered the most likely time for symptoms of glucocorticoid under-replacement to occur by 56% of respondents. A vast majority (90.1%) confirmed that they provide specific recommendations during Ramadan fasting. There was a difference in practice amongst those who provided recommendations, with 53.0% of respondents recommending once daily prednisolone at *sahur* while the remainder opting for twice daily hydrocortisone given at *sahur* and second dose at *iftar*. The rate of prescribing prednisolone was different among endocrinologists and trainees (42.6% vs 66.7%,  $p=0.03$ ). When comparing the type of practice— public hospital, academic hospital or private practice, prednisolone prescription rate was 51.8%, 78.6% and 30.8% respectively ( $p=0.05$ ).

#### CONCLUSION

There is significant variation in practice amongst the endocrinology fraternity in Malaysia when prescribing glucocorticoids during Ramadan. There is a crucial, urgent need for development of local guidelines on glucocorticoid replacement for fasting during Ramadan for Muslims with AI.



## OP\_A002

### EXPLORING THE CORTISOL WORMHOLE: A SHORTCUT PREDICTOR FOR SHORT SYNACTHEN TEST OUTCOME IN THE SABAH POPULATION

<https://doi.org/10.15605/jafes.038.S2.02>

**Qin Zhi Lee, Hwee Ching Tee, Kai Xuan The**

*Hospital Queen Elizabeth 2, Kota Kinabalu, Sabah, Malaysia*

#### INTRODUCTION

The Short Synacthen Test (SST) is a commonly used diagnostic tool for adrenal insufficiency. Recent studies demonstrating a correlation between morning cortisol levels and SST outcomes suggest the utility of establishing cut-off values for morning cortisol levels to maximize the potential for cost reduction.

#### METHODOLOGY

In this retrospective cross-sectional analysis, we evaluated 620 SSTs conducted in both inpatient and outpatient settings. Baseline morning cortisol levels were drawn prior to Synacthen injection, while cortisol levels at 30- and 60-minutes post-injection of Synacthen were also obtained. All samples underwent analysis using the Abbott Architect Assay.

#### RESULT

Receiver-operator curve analysis revealed an area under the curve (AUC) of 0.865 (95% CI 0.838-0.892). Our findings indicated that morning cortisol levels above 382.5 nmol/L could predict a passing result on the SST with 100% specificity (86% sensitivity, 100% positive predictive value). Conversely, a level below 81.2 nmol/L exhibited a 100% sensitivity (47% specificity, 100% positive predictive value) in predicting SST failure. Of the participants, 38 (14%) passed the SST using the >382.5 nmol/L cutoff, while 164 (46%) failed using the <81.2 nmol/L cutoff. Notably, our study suggests that approximately 32% of the conducted SSTs (202 tests) may have been unnecessary based on these findings.

#### CONCLUSION

Our research supports the use of morning cortisol cutoff values to predict SST outcomes. A morning cortisol level below 81.2 nmol/L is indicative of SST failure, while a level above 382.5 nmol/L predicts SST success. Patients falling within the 81.2-382.5 nmol/L range should undergo further assessment with the SST to establish an accurate diagnosis.



## OP\_A003

### COMPARISON OF TITRATION ALGORITHMS IN INSULIN-NAÏVE PATIENTS WITH TYPE 2 DIABETES MELLITUS INITIATED WITH BASAL INSULIN NPH

<https://doi.org/10.15605/jafes.038.S2.03>

**Yi Jiang Chua, Luqman Ibrahim, Shireene Ratna Vethakkan, Jeyakantha Ratnasingam, Lee Ling Lim, Sharmila Paramasivam**

*Division of Endocrinology, Department of Internal Medicine, University Malaya, Kuala Lumpur, Malaysia*

#### INTRODUCTION

Insulin is one of the most widely used injectable diabetic medications especially in patients with long-standing T2DM. Various patient-led basal insulin titration regimens have been shown to be effective and safe to be carried out in an outpatient setting. We designed this prospective randomized study to compare the difference in the patient-led basal NPH insulin titration method (daily titration versus every 3-day titration) in reducing HbA1c among patients with T2DM.

#### METHODOLOGY

In this prospective interventional study, insulin naïve patients were randomized to either a daily basal NPH insulin titration by 1 unit per day or every 3-day basal NPH insulin titration by 2 units to achieve the fasting CBG of <7 mmol/L. All patients were followed up for 12 weeks and the difference in the HbA1c after 12 weeks were recorded together with other secondary parameters such as hypoglycaemia, duration to achieve fasting CBG target, weight, BMI and patient satisfaction.

#### RESULT

Daily and every 3-day basal NPH insulin titration method managed to reduce median HbA1c from 10.2 (9.3-12.1)% to 8.0 (6.7-8.8)% and 10.5 (9.6-13.0)% to 7.7 (7.2-8.4)% respectively within the 12 week period. In the daily titration group, 100% (n=33/33) of patients achieved fasting CBG <7 mmol/L while in the every 3-day titration group, 93.5% (n= 29/31) of the patients achieved the target. The daily titration group needed a median of 5 days to achieve a CBG <7 mmol/L as compared with every 3-day titration group of a median of 11 days ( $p= 0.009$ ). There was an equal number of patients who experienced hypoglycaemia in both groups.

#### CONCLUSION

Patient-led titration of NPH Insulatard® basal insulin could be done effectively and safely in insulin-naïve patients with T2DM. Daily titration of 1 unit per day is as safe as the every 3-day titration technique and is able to achieve target fasting blood sugar faster.



## OP\_A004

### COMPARISON OF THRICE-DAILY PREMIXED HUMAN INSULIN WITH BASAL-BOLUS THERAPY AMONG PATIENTS WITH TYPE 2 DIABETES MELLITUS: A CROSS-OVER STUDY

<https://doi.org/10.15605/jafes.038.S2.04>

Jamie Hong Im Teoh,<sup>1</sup> Nor Azizah Aziz,<sup>1</sup> Chong Hui Khaw,<sup>1</sup> Shanty Velaiutham,<sup>1</sup> Phei Ching Lim,<sup>2</sup> Shueh Lin Lim<sup>1</sup>

<sup>1</sup>Endocrine Unit, Medical Department, Penang Hospital, Malaysia

<sup>2</sup>Pharmacy Department, Penang Hospital, Malaysia

#### INTRODUCTION

Thrice-daily (TDS) biphasic insulin analogues are suitable alternatives used for intensifying insulin therapy, but the clinical use of TDS premixed human insulin (PHI) is unclear. We hypothesised that TDS PHI is as efficacious as basal-bolus (BB) therapy.

#### METHODOLOGY

A cross-over study comparing TDS PHI with BB regimens among patients with T2DM was conducted in Penang Hospital between October 2020 and June 2021. Patients receiving TDS PHI or BB regimen were monitored over the first 12 weeks and then crossed over to the other regimen for another 12 weeks. The outcomes measured were HbA1c, fasting plasma glucose (FPG), total daily dose (TDD) of insulin, weight, hypoglycaemia events, and adherence to insulin injection over a 12-week period.

#### RESULT

Forty-four patients (75% female; mean baseline HbA1c 9.55%) were included. Mean HbA1c in patients receiving TDS PHI and BB regimens was reduced after the 12-week period (-0.62%;  $p < 0.001$  and -0.56%;  $p = 0.015$ , respectively). However, the change in mean HbA1c and FPG over the 12-week period was similar in patients receiving both regimens. Weight increased in patients receiving TDS PHI regimen ( $+1.07 \pm 1.73$  kg), but it decreased in patients receiving BB regimen ( $-0.30 \pm 2.60$  kg) over the 12-week period ( $p = 0.005$ ). The total daily dose of insulin in patients receiving TDS PHI was reduced ( $-1.71 \pm 6.52$  units), whereas it increased in patients receiving BB regimen ( $+1.95 \pm 6.96$  units) ( $p = 0.012$ ) over the 12-week period. Patients receiving TDS PHI regimen had a higher mean total basal insulin dose ( $49.22 \pm 12.45$  units,  $p < 0.001$ ), while patients receiving BB regimen had a higher mean total prandial insulin dose ( $39.67 \pm 9.84$  units,  $p < 0.001$ ). No difference in hypoglycaemia events and adherence rate were observed within and between the groups.

#### CONCLUSION

Among patients with poorly controlled T2DM on insulin, TDS PHI is a viable intensification therapy with similar efficacy and safety profile as the BB regimen.



## OP\_A005

### THE EFFECT OF DRY INTERMITTENT FASTING ON ANTHROPOMETRIC OUTCOMES AND BODY COMPOSITION AMONG ADULTS WITH OVERWEIGHT AND OBESITY

<https://doi.org/10.15605/jafes.038.S2.05>

Shazana Rifham Abdulla,<sup>1</sup> Nur Hayati Azizul,<sup>1</sup> Ruziana Mona Wan Mohd Zin,<sup>1</sup> Nur Suffia Sulaiman,<sup>1</sup> Norhayati Mustafa Khalid,<sup>1</sup> Roshan Jahn Mohd Salim Mullahi Jahn,<sup>1</sup> Muhamad Khairul Nazrin Khalil,<sup>1</sup> Norhashimah Abu Seman,<sup>1</sup> Nur Azlin Zainal Abidin,<sup>1</sup> Azizan Ali,<sup>1</sup> You Zhuan Tan,<sup>1</sup> Azahadi Omar,<sup>2</sup> Zamtira Seman,<sup>2</sup> Mohd Fairulnizal Md Noh<sup>1</sup>

<sup>1</sup>Nutrition, Metabolism and Cardiovascular Research Centre, Institute for Medical Research, National Institutes of Health, Ministry of Health Malaysia, Selangor, Malaysia

<sup>2</sup>Sector for Biostatistics and Data Repository, National Institutes of Health, Ministry of Health, Selangor, Malaysia

#### INTRODUCTION

Adult obesity and overweight pose a significant risk to global public health and are associated with various non-communicable diseases. The effectiveness of two days per week of dry fasting is still unknown, even though intermittent fasting is widely practised as a weight loss method. This study aimed to evaluate the effectiveness of a combined dry intermittent fasting and healthy plate (IFHP) versus healthy plate (HP) intervention in improving anthropometric outcomes and body composition.

#### METHODOLOGY

This quasi-experimental study involved 177 adults with overweight and obesity, of whom 91 (51.4%) were allocated to the IFHP group and 86 (48.6%) to the HP group. Data was collected at baseline, after the supervised phase (month 3), and after the unsupervised phase (month 6). Anthropometric (weight, height, waist circumference, and hip circumference) and body composition (body fat percentage, body fat mass, skeletal muscle mass, and visceral fat area) data were measured at all 3 points of data collection. Sociodemographic data were obtained using a questionnaire at baseline.

#### RESULT

Most of the participants were female (n=147, 83.1%) and Malays (n=141, 79.7%).

In the IFHP group, there were significant reductions in weight, body mass index (BMI), body fat percentage, body fat mass, and visceral fat area after 3 and 6 months compared to baseline ( $p < 0.05$ ). For waist and hip circumference, a significant decrease of these parameters was observed in both groups at month 6 compared to baseline and month 3 ( $p < 0.05$ ). No significant improvement in other parameters was observed among participants in the HP group. Similarly, no significant difference in between-group comparison was detected throughout the intervention.

#### CONCLUSION

A combined intermittent fasting and healthy plate intervention was effective for improving anthropometric outcomes and body composition in adults with overweight and obesity.



## OP\_A006

### EVALUATION OF BONE MINERAL DENSITY AND ASSOCIATION OF FRAX SCORE WITH FRACTURES AND DIABETES: A SINGLE-CENTRE CROSS-SECTIONAL REVIEW

<https://doi.org/10.15605/jafes.038.S2.06>

Noor Ashikin Ismail,<sup>1</sup> Abdullah Shamsir Abdul Mokti,<sup>1</sup> Low Yen Nee,<sup>1</sup> Carolina Shalini Singarayar,<sup>1</sup> Lim Guat Yee,<sup>2</sup> Chia Yong Kuang,<sup>2</sup> Muhamad Riduan Daud,<sup>2</sup> Dinehs Rao Ramakrishna Rao,<sup>2</sup> Nirmalatiban Parthiban,<sup>2</sup> Lio Jia Yin,<sup>2</sup> Putri Arina Megat Mohamed Zainuddin,<sup>2</sup> Chitra Devi Balasubramaniam,<sup>2</sup> Gowri Chandran,<sup>2</sup> Foo Siew Hui<sup>1</sup>

<sup>1</sup>Endocrine Unit, Department of Internal Medicine, Selayang Hospital, Selangor, Malaysia

<sup>2</sup>Department of Internal Medicine, Selayang Hospital, Selangor, Malaysia

#### INTRODUCTION

Both osteoporosis and diabetes mellitus are highly prevalent among postmenopausal women and the elderly in Malaysia. Individuals with diabetes are known to fracture at a relatively higher bone mineral density (BMD). We aimed to describe the demographic, clinical characteristics and treatment regimen among patients screened for osteoporosis at Selayang Hospital and examine the relationship between FRAX score and fracture in subjects with diabetes versus in those without diabetes.

#### METHODOLOGY

This is a cross-sectional review of patients aged 40 to 90 who underwent bone densitometry screening at Selayang Hospital. Subjects who were commenced on osteoporosis medication for more than 12 months at the time of BMD assessment were excluded. Demographic and clinical characteristics were obtained from electronic medical record. The 10-year risk of fracture was estimated using FRAX-Singapore ([www.sheffield.ac.uk/FRAX/tool.aspx](http://www.sheffield.ac.uk/FRAX/tool.aspx)).

#### RESULT

Three hundred thirty-four patients were included. The mean age was  $64 \pm 9.2$  years old, 92% were women. Majority were Chinese (47%) followed by Malay (35%) and Indian (18%). The mean BMI was 25 kg/m<sup>2</sup>. Diabetes was present in 22%. Other common risk factors include rheumatoid arthritis (38%) and glucocorticoid exposure (14%). Forty patients (12%) had a previous fracture. The mean FRAX scores for major osteoporotic and hip fractures were 10.9% and 4.5% respectively. One hundred fifty-six subjects (47%) had FRAX score above the recommended treatment threshold for osteoporosis but only 66% of them were commenced on treatment. Prevalent fracture was positively correlated with FRAX scores for both major osteoporotic and hip fractures ( $p=0.01$ ). This association did not differ significantly among individuals with diabetes versus those without diabetes.

#### CONCLUSION

Osteoporosis is highly prevalent in this cohort with 12% already fractured before BMD evaluation. Forty-seven percent (47%) fulfilled the recommended threshold for treatment, but more than one-third were not offered treatment. High FRAX score was associated with a previous fracture. The presence of diabetes did not negatively impact this association.



## OP\_A007

### FACTORS ASSOCIATED WITH VITAMIN D DEFICIENCY IN PATIENTS WITH TYPE 2 DIABETES MELLITUS

<https://doi.org/10.15605/jafes.038.S2.07>

**Nur Aini Eddy Warman, Fatimah Zaherah Mohamed Shah, Aimi Fadilah Mohamad, Mohd Hazriq Awang, Nur Aisyah Zainordin, Rohana Abdul Ghani**

*Fakulti Perubatan Universiti Teknologi MARA (UiTM), Sungai Buloh, Malaysia*

#### INTRODUCTION

The prevalence of vitamin D deficiency in the general population in Malaysia was estimated to be 67.4%. In other populations, its prevalence was found to be higher in persons with T2DM. However, vitamin D deficiency has not yet been studied among persons with diabetes in Malaysia. Hypovitaminosis D was found to increase the risk of developing T2DM and is associated with an elevated risk of retinopathy and neuropathy.

#### METHODOLOGY

The study aimed to determine the prevalence and factors associated with vitamin D deficiency in patients with T2DM. We conducted a cross-sectional study in patients with T2DM (n=110). The patients were divided into 2 groups; vitamin D deficient (total 25(OH)D<sub>3</sub> <50 nmol/L) and vitamin D non-deficient (total 25(OH)D<sub>3</sub> ≥50 nmol/L). Serum total 25(OH)D<sub>3</sub> was analysed using electrochemiluminescence immunoassay method using Roche Diagnostic laboratory machine.

#### RESULT

The prevalence of vitamin D deficiency in our population with T2DM was 48.2% (53/110). In the remaining non-deficient group, 33.6% (37/110) had levels between 50-75 nmol/L, and 18.2% (20/110) had a level ≥75 nmol/L. The baseline age was 57.8 years, diabetes duration was 12 years, and HbA1c was 7.9%. There were significantly higher BMI (29.54 ± 3.29 vs 28.15 ± 4.11 kg/m<sup>2</sup>, *p*=0.05), HbA1c (8.13±1.19 vs 7.74 ± 0.89%, *p*=0.05), triglycerides (TG) (1.7 (IQR 1.3-2.1) vs 1.3 (IQR 1.15-1.8) mmol/L, *p*=0.05), and LDL-c (2.34 ± 0.96 vs 2.03 ± 0.68 mmol/L, *p*=0.05) in patients with vitamin D deficiency. The vitamin D deficient group showed a larger proportion of patients on insulin ≥0.5 unit/kg/day (58.5 vs 36.8%, *p*=0.02) and triglycerides ≥1.7 mmol/L (58.5 vs 36.8%, *p*=0.02). Insulin ≥0.5 unit/kg/day (OR 2.62; 1.1815-8.17; *p*=0.02) and BMI ≥25 kg/m<sup>2</sup> (OR 4.429; 95%CI 1.311-14.96; *p*=0.02) were independent predictors for developing vitamin D deficiency.

#### CONCLUSION

This study demonstrated a high prevalence of vitamin D deficiency in patients with T2DM. Patients with vitamin D deficiency had a significantly higher BMI, TG, LDL-c, HbA1c, and a higher proportion of patients with insulin ≥0.5 unit/kg. With Insulin ≥0.5 unit/kg and BMI ≥25 kg/m<sup>2</sup>, the odds of having vitamin D deficiency increased by 2-fold and 4-fold respectively.



## Adult Physical Poster Presentation

### PP\_A001

#### A SINGLE-CENTRE EXPERIENCE IN UTILIZATION OF MITOTANE AS AN ADJUVANT THERAPY FOR ADRENOCORTICAL CARCINOMA

<https://doi.org/10.15605/jafes.038.S2.08>

Alyani H,<sup>1</sup> Siti Sanaa WA,<sup>1</sup> Masliza Hanuni MA,<sup>1</sup> Nur Hidayah MM,<sup>1</sup> Hussain M,<sup>2</sup> Nor Hisham M<sup>2</sup>

<sup>1</sup>Endocrinology Division, Medical Department, Hospital Sultanah Nur Zahirah, Kuala Terengganu, Malaysia

<sup>2</sup>Surgical Department, Hospital Sultanah Nur Zahirah, Kuala Terengganu, Malaysia

#### INTRODUCTION

Adrenocortical carcinoma (ACC) is a rare, aggressive tumour with an estimated incidence of ~0.5-2 per million/year. It may present with autonomous adrenal hormone excess or with symptoms caused by an abdominal mass.

#### METHODOLOGY

We report a case of a 55-year-old male who presented with left loin pain for a year, associated with loss of appetite, weight loss and fatigue. There were no symptoms and signs suggestive of cortisol or androgen excess.

#### RESULT

Initial abdominal CT demonstrated a large enhancing solid adrenal mass measuring 13.6 × 12.5 × 16.8 cm. One month following this finding, he was hospitalized for septic shock secondary to infected left adrenal mass and adrenal insufficiency (cortisol on inotropic support was 173 nmol/l). Other functional tests such as 24-hour urine metanephrines and ARR were within normal range. Open left adrenalectomy and left nephrectomy were performed. Intra-operatively, a vascularized left adrenal tumour, size approximately 20 × 15 cm which ruptured with pus was noted. Tumour was seen infiltrating the upper and middle pole of the left kidney extending to the calices. Histopathological examination confirmed ACC with Ki-67 of 1%. The European Network for the Study of Adrenal Tumours (ENSAT) staging was TIII, N0, M0, Rx. After a multidisciplinary discussion, we agreed to initiate adjuvant mitotane therapy with a low threshold for radiotherapy. We started him on mitotane 500 mg TDS and increased this to 1 g TDS after a month. Glucocorticoid replacement with hydrocortisone was increased accordingly from 10 mg TDS to 20/20/10 mg TDS. He tolerated this dosing well with no adverse effects. Laboratory monitoring with FBC, RP, and LFT were all normal. Latest CT staging showed no residual tumour or any evidence of distant metastasis.

#### CONCLUSION

More than half of patients with ACC who have undergone complete removal of the tumour have a relapse risk, often with metastases. The current guideline advocates for the use of adjuvant mitotane therapy in patients without macroscopic residual tumour after surgery, but who have a perceived high risk of recurrence, as in our case.



## PP\_A002

### COMPUTED TOMOGRAPHY AND ADRENAL VEIN SAMPLING CONCORDANCE RATE IN PATIENTS WITH PRIMARY ALDOSTERONISM: A TERTIARY CENTRE EXPERIENCE

<https://doi.org/10.15605/jafes.038.S2.09>

Ee Wen Loh,<sup>1</sup> Ridzuan Abdul Rahim,<sup>2</sup> Azraai Bahari Nasruddin<sup>1</sup>

<sup>1</sup>Endocrinology Unit, Hospital Putrajaya, Putrajaya, Malaysia

<sup>2</sup>Radiology Department, Institut Kanser Negara, Malaysia

#### INTRODUCTION

Primary Aldosteronism (PA) is an important cause of secondary hypertension with increasing incidence worldwide. Subtype classification is essential to determine the mode of treatment. Following an initial computed tomography (CT) imaging, adrenal vein sampling (AVS) is advocated as the next step for subtype classification. We aimed to evaluate the AVS performance in Institut Kanser Negara (IKN)/ Hospital Putrajaya (HPJ) and the diagnostic CT-AVS concordance rate.

#### METHODOLOGY

This is a retrospective cohort study of patients with primary aldosteronism who underwent AVS at IKN/HPJ between January 2016 and December 2022.

#### RESULT

A total of 106 patients with biochemically confirmed PA underwent AVS at IKN/HPJ between 2016 and 2022. This cohort had a more severe phenotype of PA with all but 2 patients requiring potassium replacement. One hundred eighteen AVS were performed within this period with a success rate of 70% (N=82). Of the unsuccessful AVS (N=36), 86% (N=31) were due to cannulation failure of the right adrenal vein. Only 1 patient experienced adrenal vein injury following the procedure but this did not result in any morbidity. The overall concordance rate between CT and AVS was 86.1% and appeared to be higher in patients with unilateral adenoma (90%). Without AVS, 6 patients would have been wrongly subjected to unilateral adrenalectomy while 3 patients would have been denied the opportunity for cure. There was no statistically significant difference between patients' age, gender and race with CT-AVS concordance rate.

#### CONCLUSION

Adrenal vein sampling is a safe procedure with a high success rate when performed at an established centre with an experienced operator. We identified a very high CT-AVS concordance rate for patients with unilateral adenoma and hypokalaemia; however, there still remains a small risk of inaccurate diagnosis without AVS.



## PP\_A003

### LONG-TERM TREATMENT OUTCOMES WITH GLUCAGON-LIKE-PEPTIDE-1 RECEPTOR AGONIST (GLP-1RA): A REAL-LIFE STUDY AT HOSPITAL PUTRAJAYA

<https://doi.org/10.15605/jafes.038.S2.10>

**Vanusha Devaraja, Chee Koon Low, Vijiya Mala Valayatham, Navin Kumar Loganadan, Zanariah Hussein**  
*Endocrine Unit, Department of Medicine, Hospital Putrajaya, Putrajaya, Malaysia*

#### INTRODUCTION

GLP-1 receptor agonists (GLP-1RAs) are reputable for their weight loss and glucose lowering benefits from various clinical trials. However, the extent to which real-world patients with type 2 diabetes (T2D) continue to respond to GLP-1RAs in successive years has not been well characterized.

#### METHODOLOGY

We conducted a retrospective cohort study involving 64 patients with T2D initiated on GLP-1RAs spanning 2011 to 2022. We analysed their weight change, glycaemic control, rate of GLP-1RAs discontinuation and adverse effects.

#### RESULT

The median age of our cohort was 56 years (SD=13.4). Fifty-two patients (81.3%) had T2D longer than 10 years. Forty-two (65%) were on insulin therapy before the initiation of GLP-1RAs. At baseline, mean HbA1c was 8.5% (SD=1.6), with a mean body weight of 97.5 kg (SD=23.6). The largest HbA1c reduction (-0.52%,  $p=0.014$ ) was observed during the first 24 months of treatment but plateaued thereafter. The odds of achieving a better HbA1c reduction was much higher in younger patients ( $p=0.009$ ), T2D less than 10 years ( $p=0.016$ ) and lower baseline HbA1c ( $p<0.001$ ). Substantial weight loss was observed during the first year of treatment (-3.3 kg,  $p<0.001$ ) and the effect persisted beyond 5 years. The proportion of patients continuing GLP-1RA was 62.5% (2 years), 36% (3 years), 15.6% (5 years) and 12.5% beyond 6 years. Twenty-four patients (37.5%) discontinued treatment after an average duration of 36 months, due to lack of clinically meaningful HbA1c and weight reduction. Six patients (9.4%) developed pronounced gastrointestinal side effects, and three necessitated treatment discontinuation. Only one patient was hospitalized for adverse cardiac event within the first year of treatment.

#### CONCLUSION

GLP-1RAs continue to deliver the real-world benefit of weight loss beyond 3 years; however, its glucose-lowering effect diminished after the first 2 years. A personalized approach remains crucial in managing T2D patients on long-term GLP-1RA.



## PP\_A004

### A SINGLE-CENTRE, RETROSPECTIVE STUDY ON THE CLINICAL CHARACTERISTICS OF PATIENT WITH TYPE 3c DIABETES MELLITUS

<https://doi.org/10.15605/jafes.038.S2.11>

Marisa Khatijah Borhan,<sup>1</sup> Florence Tan Hui Sieng,<sup>2</sup> Kuan Yueh Chien,<sup>2</sup> Chan Pei Lin<sup>2</sup>

<sup>1</sup>University Malaya Medical Centre, Malaysia

<sup>2</sup>Sarawak General Hospital, Malaysia

#### INTRODUCTION

Type 3c diabetes (T3cDM) is secondary diabetes due to an exocrine pancreatic disorder. There is little information on the profile of T3cDM locally.

#### METHODOLOGY

This is a retrospective study on adult diabetic patients with prior pancreatic disease who attended the DM clinic in Sarawak General Hospital from 2018 to 2022. Patients with acute pancreatitis (AP), chronic pancreatitis (CP), distal pancreatectomy (DP), and total pancreatectomy (TP) were included.

#### RESULT

Forty-four patients (63.6% male) fulfilled the study criteria. The majority were Iban (31.5%), followed by Malay (29.5%). The mean age at DM diagnosis was  $39 \pm 13.6$  years, with a median time to DM after pancreatic disease of 6 months (IQR4-19). Twenty-one patients had AP prior to DM, 10 had CP, seven underwent DP, and six underwent TP. The main aetiologies for AP were alcohol abuse (N=10) and hypertriglyceridaemia (N=8). Regarding CP, 8 cases were due to alcohol abuse. Reasons for pancreatectomy were pancreatic cancer (N=9) and necrotizing pancreatitis (N=4). Only seven patients were diagnosed with DM through screening, and the remaining 37 (84%) were diagnosed during admission for uncontrolled DM (N=24) and DKA (N=13). Patients with T3cDM were leaner (mean weight  $62.91 \pm 19.10$  kg), with low (N=8) or normal BMI (N=19) at diagnosis. Upon DM diagnosis, 34 patients (77.3%) were initiated and remained on insulin after 12 months. The median HbA1c at diagnosis was 9.8% (IQR7.5-13.0%) and was 8.7% (IQR7.0-10.9%) at the 12 month follow-up. Common symptoms of pancreatic exocrine insufficiency (PEI) include abdominal pain (77.3%), weight loss (43.2%) and steatorrhea (22.7%). Only 15 patients (34%) received pancreatic enzyme replacement therapy (PERT). The use of PERT has no significant effect on HbA1c result ( $p=0.422$ ) and insulin dose ( $p=0.652$ ) at 12 months.

#### CONCLUSION

There is frequently delayed and missed diagnosis of T3cDM locally. T3cDM is associated with high insulin usage, poor glycaemic control, and significant PEI burden.



## PP\_A005

### **GLYCAEMIC CONTROL AND UTILIZATION OF SODIUM-GLUCOSE COTRANSPORTER-2 INHIBITOR AND DIPEPTIDYL PEPTIDASE-4 INHIBITOR THERAPY IN A TERTIARY HOSPITAL DIABETES CLINIC IN PAHANG**

<https://doi.org/10.15605/jafes.038.S2.12>

**Nurbadriah Jasmiad, Ilham Ismail, Mimi Syafiqah Mohd Samsudin, Norhaslinda Shamsudin, Nur Azwani Ramli, Zhe Lan Wong, Eileen Tan, Saiful Shahrizal Shudim, Chee Keong See**

*Hospital Sultan Haji Ahmad Shah Temerloh, Pahang Darul Makmur, Malaysia*

#### **INTRODUCTION**

Holistic Type 2 Diabetes Mellitus (T2DM) management requires a multifactorial approach encompassing targeted lifestyle modification and diabetes education, glycaemic, blood pressure and lipid control and initiation of therapy with cardiovascular and renal benefits. The main aim of this multifactorial approach is to reduce microvascular and macrovascular complications in patients. The prescription of dipeptidyl peptidase-4 inhibitor (DPP4i) and sodium-glucose cotransporter-2 inhibitor (SGLT2i) therapy has been recommended in guidelines. Despite the increasing prescriptions, evaluation is needed to determine the true intended benefits of these drugs.

#### **METHODOLOGY**

This is a cross-sectional study which included all T2DM patients who attended the diabetes follow-up clinic in Hospital Sultan Haji Ahmad Shah Temerloh in 2022. Demographic data, HbA1c control and current diabetes treatments were reviewed and collected from the hospital health information system.

#### **RESULT**

There were 514 T2DM patients who attended the diabetes clinic, accounting for a total of 1346 clinic visits in 2022. Mean age of patients was 53.3 (SD 15.1) years and duration of follow-up in the clinic was 3.7 (SD 2.4) years. There were 52.5% (n=270) enrolled female patients and 81.9% (n=421) were of Malay ethnicity. Analysis of the latest HbA1c results revealed a median of 8.5% (IQR 3.4%). However slightly more than half of the patients had HbA1c more than 8.5% (50.7%, n=257). DPP4i treatment was present in only 17.2% (n=87) of the patients, of which only 39.1% achieved HbA1c levels below 8.5%. SGLT2i treatment was present in 28.6% (n=145) of patients with 51.7% achieving HbA1c level below 8.5%.

#### **CONCLUSION**

This study reflects a huge burden of care in achieving glycaemic control in T2DM patients with varying degrees of complications in a tertiary hospital in Pahang. Prioritizing and maximizing treatment with SGLT2 inhibitors therapy reflect the changing paradigm to achieve glycaemic control in patients with added cardio-renal benefits.



## PP\_A006

### CLINICAL CHARACTERISTICS AND MANAGEMENT OF PATIENTS WITH SEVERE HYPERCALCEMIA IN HOSPITAL PUTRAJAYA

<https://doi.org/10.15605/jafes.038.S2.13>

**Syarifah Syahirah Syed Abas, Yong Shern Siau, Janaardhan Tinakaran, Shireen Lui Siow Leng, Zanariah Hussein**

*Endocrine Unit, Medical Department, Hospital Putrajaya, Putrajaya, Malaysia*

#### INTRODUCTION

Severe hypercalcemia, defined as serum calcium  $>3.5$  mmol/L, is an endocrine emergency. It is associated with high morbidity and mortality especially in those with inappropriate management of hypercalcemia.

#### METHODOLOGY

Retrospective analysis was performed to identify patients with serum-corrected calcium of  $>3.5$  mmol/L based on biochemical test done in Hospital Putrajaya from January 2018 to April 2023. Those with more than 1 abnormally high serum calcium were included and analysed for characteristics, presentation, treatment and outcome of hypercalcemia.

#### RESULT

Forty-three patients with severe hypercalcemia were analyzed. The majority of patients were female (62.8%), with a median age of 62 years (IQR 51-68 years). Thirty-seven out of 43 patients were symptomatic at presentation, with 11 patients presenting with neurologic symptoms. Median corrected calcium at presentation was 3.87 mmol/L (IQR 3.65-4.28 mmol/L), phosphate 1.27 mmol/L (IQR 1.01- 1.66) and eGFR 38 ml/min per 1.73 m<sup>2</sup> (IQR 23.3-60).

Hypercalcemia of malignancy (HCM) accounts for 51.2% of total cases, overmedication with calcium/ Vitamin D supplements (34.9%), parathyroid adenoma (4.7%), tuberculosis (2.3%) and others (6.9%). Sixteen patients received bisphosphonate therapy (mean calcium reduction of 0.89 mmol/L in 5 days), 3 patients received calcitonin alone (mean calcium reduction of 1.9 mmol/L in 5 days), 3 patients treated with bisphosphonate and calcitonin (mean calcium reduction 1.12 mmol/L in 5 days) and 2 treated with denosumab and calcitonin (mean calcium reduction of 0.98 mmol/L in 5 days). Patients with persistent hypercalcemia  $>3$  mmol/L post-therapy were associated with higher mortality ( $p=0.018$ ). There was no difference in presenting symptoms, presentation calcium level, alkaline phosphatase, creatinine and eGFR between patients and their mortality outcome.

#### CONCLUSION

This analysis highlighted the discrepancy in the management of severe hypercalcemia before the release of the recent Endocrine Society Clinical Practice Guideline on the Treatment of Hypercalcemia of Malignancy. In this analysis, only a small proportion of patients received combination therapy of Calcitonin with Bisphosphonate/ Denosumab in managing severe hypercalcemia, resulting in persistent hypercalcemia and higher mortality risk.



## PP\_A007

### PATIENTS' QUALITY OF LIFE AFTER SWITCHING DESMOPRESSIN FROM TABLET TO SUBLINGUAL LYOPHILIZATE (MELT) FORMULATION: A SINGLE-CENTRE EXPERIENCE

<https://doi.org/10.15605/jafes.038.S2.14>

**Chee Koon Low, Vanusha Devaraja, Azraai Bahari Nasruddin, Zanariah Hussein**

*Endocrine Unit, Department of Medicine, Hospital Putrajaya, Putrajaya, Malaysia*

#### INTRODUCTION

The enduring demand for improving the chronic management of central diabetes insipidus (CDI) breeds the need for a variety of formulations of the vasopressin analogue Desmopressin. A new formulation like the sublingual lyophilizate (melt) enhances the bioavailability of desmopressin by nearly 60 percent compared to the tablet.

#### METHODOLOGY

This observational study applied the Nagasaki Diabetes Insipidus Questionnaire (NADIQ) to assess a patient's quality of life (QoL) after switching from a desmopressin tablet to a melt formulation for at least one month. The questionnaire was comprised of 12 questions focusing on three clinical variables, namely thirst control (5 questions), polyuria control (5 questions), and treatment satisfaction (2 questions). The scores from each question were compared to identify any difference in QoL after switching the formulation.

#### RESULT

A total of 13 patients were analysed. The mean age of the patients was  $40.5 \pm 15.7$  years. Six patients (41.6%) acquired CDI after pituitary surgery and/ or radiotherapy, with at least 3 anterior pituitary hormone deficiencies which were adequately replaced. The mean duration of CDI was  $10.5 \pm 7.6$  years. The mean duration of taking melt formulation was  $7.4 \pm 6.6$  months. The mean daily dose of desmopressin was  $350 \pm 193.1$  mcg/day for the tablet formulation and  $180 \pm 91.7$  mcg/day for the melt formulation. Eleven patients (84.6%) reported an improved total QoL score after changing to melt formulations. The median QoL score increased from 29 (tablet formulation group) to 38 (melt formulation group) ( $p=0.012$ ). Among the three clinical variables, melt formulation offered a significantly better QoL score for polyuria control ( $p=0.006$ ).

#### CONCLUSION

Melt formulation confers a better QoL for patients with CDI at a lower daily dose as compared to the tablet formulation.



## PP\_A008

### DOPAMINE AGONIST-INDUCED IMPULSE CONTROL DISORDERS IN PATIENTS WITH PROLACTINOMA: A CROSS-SECTIONAL MULTI-CENTRE STUDY

<https://doi.org/10.15605/jafes.038.S2.15>

Woh Wei Mak,<sup>1</sup> Nurain Mohd Noor,<sup>2</sup> Mohamed Badrulnizam Long Bidin<sup>1</sup>

<sup>1</sup>Hospital Kuala Lumpur, Malaysia

<sup>2</sup>Hospital Putrajaya, Putrajaya, Malaysia

#### INTRODUCTION

Dopamine agonists are the first-line agents in the treatment of symptomatic prolactinomas. One of the rare side effects of dopamine agonists is impulse control disorders (ICDs). The aim of this study is to determine the prevalence and associated risk factors of developing ICDs.

#### METHODOLOGY

This was a cross-sectional study involving 149 patients with prolactinoma in 2 tertiary centres who received at least a month of dopamine agonists. Demographics and blood results were retrieved from medical records. All patients underwent structured interview focused on ICDs using Barratt Impulsiveness Scale-11 (BIS-11) and Questionnaire for Impulsive-Compulsive Disorders in Parkinson's Disease (QUIP). BIS-11 score above 72 is used to classify an individual as impulsive. QUIP has 2 sections: Section 1 assesses four ICDs (gambling, sexual, buying, and eating), Section 2 assess other three other ICDs (punding, hobbyism, and walkabout). Patients were required to answer regarding whether they have behavioural changes at any time after the commencement of dopamine agonists.

#### RESULT

The mean age of the participants was 42, with a majority of them being female 117 (78.5%). The majority (n=93, 62.4%) were of Malay ethnicity. Ninety (61.1%) of the patients had microadenoma with baseline serum prolactin of 3251 uU/ml (IQR 500.6 uU/ml). Most of the participants 120 (80.5%) were on Cabergoline therapy, with median duration of treatment of 145 weeks and median current dose of 1mg weekly. The prevalence of ICDs was 39 (26.2%). The risk factor identified to be associated with ICD development was tertiary education level (Adjusted OR = 5.183, 95% CI [1.460, 18.402],  $p=0.011$ ) after controlling for other confounding factors.

#### CONCLUSION

This study showed that ICDs are not uncommon with a prevalence of 26.2% among prolactinoma patients on dopamine agonists. Tertiary education level was identified as an associated risk factor. We recommend systematically screening for ICDs in all patients on dopamine agonists and providing forewarnings of possible ICD development among patients.



## PP\_A009

### EVALUATION OF HYPOTHYROID STABILISATION AMONG PATIENTS WITH DIFFERENT DOSES OF LEVOTHYROXINE: A RETROSPECTIVE OBSERVATIONAL REVIEW STUDY

<https://doi.org/10.15605/jafes.038.S2.16>

**Basil Lee Choong Lin,<sup>1</sup> Ernieda Md Hatah,<sup>2</sup> Adyani Md Redzuan<sup>2</sup>**

<sup>1</sup>Pharmacy Department, Hospital Kuala Kubu Bharu, Selangor, Malaysia

<sup>2</sup>Faculty of Pharmacy, Universiti Kebangsaan Malaysia, Kuala Lumpur, Malaysia

#### INTRODUCTION

Levothyroxine (LT4) dose ranges have been linked to affect the stability of thyroid stimulating hormone (TSH) values and hypothyroid disease stability in patients who have restored euthyroid state with LT4. This instability can be reflected by the increased need for LT4 dosage adjustments. The American Thyroid Association 2014 Guidelines suggested vaguely that lower doses of LT4 appear to produce more stable TSH values over time than those taking higher doses. Therefore, this study aimed to evaluate disease stabilisation following restoration of euthyroid state among hypothyroid patients with different LT4 doses.

#### METHODOLOGY

This was a retrospective observational study conducted in July 2022 focusing on noncomplicated hypothyroid patients prescribed with LT4 between July 2016 to January 2022 at the Outpatient Clinic Hospital Kuala Kubu Bharu. Disease stability between standard (100-150 mcg/day) versus extreme (<100 and >150 mcg/day) dose LT4 that restored euthyroid state over duration of 12 and 18 months were compared. Multivariate logistic regression was performed to determine factors that may influence disease stability up to 18 months while on the same LT4 regime that restored euthyroid state.

#### RESULT

Seventy-four hypothyroid patients on LT4 who attained stable euthyroid status were reviewed. More patients with extreme-dose LT4 required dosage adjustment compared to those on standard-dose LT4 (40.5% versus 16.2%;  $p=0.010$  at 18-months). The factors identified to be significantly favourable to hypothyroid disease stability following euthyroid attainment include presence of chronically-interacting medication [adjusted odds ratio (AOR) = 0.054; 95% confidence interval (CI) = 0.007-0.453;  $p=0.007$ ], Chinese ethnicity (AOR=0.093; 95% CI=0.009-0.946;  $p=0.045$ ) and higher comorbid burden (AOR=0.555; 95% CI=0.310-0.993;  $p=0.047$ ). Conversely, extreme-dose LT4 (AOR=8.375; 95% CI=2.102-33.559;  $p=0.003$ ) and higher number of co-prescribed medications (AOR=1.643; 95% CI=1.071-2.521;  $p=0.023$ ) were associated with greater odds of requiring LT4 dosage adjustment.

#### CONCLUSION

Extra caution and more frequent monitoring may be considered when treating extreme-dose LT4 patients who have already restored euthyroid state as their hypothyroid disease may still be unstable.



## PP\_A010

### **RADIOACTIVE IODINE THERAPY FOR BENIGN THYROID DISORDERS: EXPERIENCES FROM A TERTIARY CENTRE IN MALAYSIA**

<https://doi.org/10.15605/jafes.038.S2.17>

**Muhammad Faiz Che Ros,<sup>1</sup> Samuel Yee Siew Mun,<sup>2</sup> Noor Rafhati Adyani Abdullah<sup>1</sup>**

<sup>1</sup>*Endocrinology Unit, Department of Internal Medicine, Hospital Sultanah Bahiyah, Kedah, Malaysia*

<sup>2</sup>*Department of Internal Medicine, Hospital Sultanah Bahiyah, Kedah, Malaysia*

#### **INTRODUCTION**

Radioactive iodine (I-131) (RAI) has been used to treat hyperthyroidism since the early 1940s. Its action causes permanent destruction to the thyroid tissue by emitting radiation of two forms, gamma and beta rays. Gamma radiation effects are more useful for diagnostic purposes, whereas beta radiation effects are therapeutic. RAI is indicated as a definitive therapy for benign thyroid diseases (Graves' disease, toxic multinodular goitre (TMNG) and toxic adenoma). The purpose of the study is to evaluate the outcomes of RAI for benign thyroid disorders in our centre.

#### **METHODOLOGY**

We conducted a retrospective analysis of patients with benign thyroid diseases treated with RAI between January 2020 to December 2022. The data was retrieved from our electronic medical records comprised of demographic data, endocrine thyroid data, prior antithyroid drugs, presence of thyroid orbitopathy, frequencies of RAI sessions and complications.

#### **RESULT**

A total of 283 patients received RAI. 76.1% (223/283) were female and the mean age was 46 years (SD 15). Most patients had Graves' disease (77%), followed by TMNG (20%) and toxic adenoma (3%). Thirty-three percent (72/218) of patients with Graves' disease had TSH receptor antibody (TRAb) level measurement with a mean value of 15.8I U/L (SD 28.1). The mean free T4 level prior to RAI was 18.1 pmol/L (SD 8.3). Mild thyroid orbitopathy was documented in 16.1% (35/218) of patients with Graves' disease which was considered low risk for RAI. 79% of the patients were rendered hypothyroid after a single RAI therapy, 19% required a second RAI therapy and 2% had third RAI therapy. Following RAI therapy, there were no episodes of worsening orbitopathy, one patient developed thyroid storm and one patient had a pregnancy within 6 months post RAI.

#### **CONCLUSION**

RAI therapy is a safe and effective treatment for benign thyroid diseases. Most patients achieved cure after a single RAI therapy with a very low complication rate. This study provides a benchmark for further improvement in thyroid patients' care.



## PP\_A011

### OPTIMISING TSH RECEPTOR ANTIBODY (TRAb) TESTING IN PREGNANCY: A SINGLE- CENTRE AUDIT

<https://doi.org/10.15605/jafes.038.S2.18>

**Kausalyaa Krishnabalan and Azraai Bahari Nasruddin**

*Endocrine Unit, Department of Medicine, Hospital Putrajaya, Putrajaya, Malaysia*

#### INTRODUCTION

The course of Graves' disease in pregnant women is variable and there is a risk of fetal/ neonatal thyrotoxicosis as TSH Receptor Antibodies (TRAb) can pass through the placenta. TRAb should be tested in pregnant patients with Grave's thyrotoxicosis or Grave's with a past history of radioiodine or thyroidectomy. The 2017 American Thyroid Association Thyroid Disease in Pregnancy Guideline specified a cut-off TRAb of >5 IU/L (3 times the upper limit of normal) in the first trimester to identify patients with increased risk. Patients with elevated TRAb in the first trimester and/ or requiring anti-thyroid drugs (ATD) mid-pregnancy are recommended for repeat testing in the third trimester. Persistent TRAb >5 IU/L in late pregnancy predicts risk of neonatal hyperthyroidism. We aimed to review the practice of TRAb monitoring in pregnancy in Hospital Putrajaya (HPJ).

#### METHODOLOGY

A retrospective audit of pregnant women with a history of Grave's thyrotoxicosis seen between 2019 to 2022 in HPJ. We identified 23 women with at least 2 TRAb tests in pregnancy.

#### RESULT

Of 23 women, 19 were thyrotoxic on ATD, 3 were euthyroid on thyroxine replacement post-radioiodine therapy and 1 was euthyroid and without treatment. At baseline, 2 had normal TRAb (<1.75 IU/L), 13 had elevated TRAb but below the cut-off (>5 IU/L) and 8 significantly elevated TRAb (>5 IU/L). All 15 patients with initial TRAb below the cut-off, had repeat TRAb that remained either normal or below 5 IU/L. The TRAb level reduced to below 5 IU/L in 3 patients with initial high TRAb.

#### CONCLUSION

One patient had unnecessary initial testing and two-thirds of patients had unnecessary repeat TRAb testing. A TRAb level of <5 IU/L in early pregnancy correlated 100% with TRAb below the cut-off in late pregnancy. Overall, 1 in 5 women (21%) had risk of their fetus developing neonatal thyrotoxicosis. This audit highlights the need to improve awareness of the guidelines. A simple graphical algorithm has been developed as a guide.



## Adult E-Poster Presentation

### EP\_A001

#### **BILATERAL GIANT ADRENAL MYELOLIPOMA**

<https://doi.org/10.15605/jafes.038.S2.19>

Noor Hafis Md Tob, Chin Voon Tong, Melissa Vergis, Siow Ping Lee

*Malacca Hospital, Malaysia*

#### **INTRODUCTION/BACKGROUND**

Adrenal myelolipomas are rare, benign, non-functioning tumours consisting of mature adipose tissue and various hematopoietic components. They are typically small and asymptomatic and are, thus, diagnosed incidentally. We present a case of bilateral giant adrenal myelolipomas, including the results of biochemical laboratory tests and imaging studies.

#### **CASE**

A 45-year-old paraplegic female presented with increasing abdominal distention and pain. She has background diabetes and hypertension. On physical examination, she was normotensive, with a blood pressure of 133/80 mmHg. Abdominal examination revealed large, hard masses more prominent over the right side of the abdomen. Both lower limbs were erythematous and oedematous up to the mid-thigh. In the ward, she developed septic shock secondary to leg cellulitis complicated with acute kidney injury requiring haemodialysis. Contrast-enhanced computerized tomography (CECT) scans showed huge bilateral suprarenal masses with low Hounsfield units (HU): the right 191 x 246 x 344 mm while the left 100x145 x 119 mm. Initial hormonal workup showed non-suppressed cortisol levels on both overnight dexamethasone suppression tests (OnDST) (1086.3 nmol/L) and low-dose dexamethasone suppression tests (LDDST) (398.2 nmol/L). Plasma normetanephrine levels were high (2.8 nmol/L; normal <0.9). Repeated 24-hour urine metanephrines in the outpatient setting were normal. She underwent right adrenalectomy after a multidisciplinary discussion concluded a possibility of malignant transformation. Histopathological examination (HPE) showed Myelolipoma with a weight of 6600 g. Repeated OnDST post-surgery was normal.

Giant adrenal myelolipomas can cause significant compression effects on surrounding structures and exhibit variable biochemical patterns. In this case, it produced false-positive results due to the presence of confounding factors.

#### **CONCLUSION**

This is a case of a bilateral giant myelolipoma with an initial false-positive functioning status biochemically and multiple sequelae. Nevertheless, appropriate hormonal workup is still essential prior to surgical intervention to avoid unnecessary catastrophic crises.

### EP\_A002

#### **FUNCTIONING ADRENOCORTICAL ONCOCYTIC CARCINOMA: A RARE VARIANT**

<https://doi.org/10.15605/jafes.038.S2.20>

Dineash Kumar Kannesan,<sup>1</sup> Teh Roseleen Nadia Roslan,<sup>1</sup> Norhayati Yahaya,<sup>1</sup> Aniza Hassan,<sup>2</sup> Junaidi Awang Isa<sup>2</sup>

<sup>1</sup>Endocrine Unit, Hospital Raja Perempuan Zainab II, Kelantan, Malaysia

<sup>2</sup>Department of Pathology, Hospital Raja Perempuan Zainab II, Kelantan, Malaysia

#### **INTRODUCTION/BACKGROUND**

Adrenocortical oncocytic carcinoma (AOC) is a rare histopathological variant of adrenocortical carcinoma (ACC) that is mostly non-functional that are discovered incidentally or present with vague abdominal pain. Functioning AOCs are extremely rare.

#### **CASE**

We report the case of a 62-year-old Siamese female who presented with progressive left-sided abdominal pain. Computed tomography demonstrated a huge mass over the left upper retroperitoneal region. Biochemically, the patient had possible autonomous cortisol secretion.

Left adrenalectomy was successful with R0 resection, histological examination revealed AOC (based on Lin-Weiss-Biscelgia score) with Ki-67 of 10% and she was staged as ENSAT Stage 2. She is under periodic imaging surveillance. Nearly 3 years after complete resection, there was no evidence of recurrence or metastasis clinically and radiologically and her cortisol status reverted to normal.

#### **CONCLUSION**

In summary, we describe here an extremely rare case of functioning AOC which differs clinically from conventional ACC and showed a more favourable prognosis.



## EP\_A003

### 'AN IMPENDING DOOM:' RARE CASE OF RUPTURED PHEOCHROMOCYTOMA PRESENTING AS PHEOCHROMOCYTOMA CRISIS

<https://doi.org/10.15605/jafes.038.S2.21>

Noor Muhammad Azlan Shah,<sup>1</sup> Prashanya Kannan,<sup>1</sup> Nadia Helena,<sup>1</sup> Dian Noriza,<sup>1</sup> Fadzliana Hanum,<sup>2</sup> Gunavathy Muthusamy<sup>1</sup>

<sup>1</sup>Department of Internal Medicine, Hospital Shah Alam, Malaysia

<sup>2</sup>Department of Radiology, Hospital Shah Alam, Malaysia

#### INTRODUCTION/BACKGROUND

Spontaneously ruptured pheochromocytoma presenting as pheochromocytoma crisis is a rare complication and is associated with high morbidity and mortality.

#### CASE

We present a case of a 46-year-old female with left pheochromocytoma, diagnosed following a total abdominal hysterectomy for uterine leiomyoma. 24-hour urine catecholamines were elevated- norepinephrine: 2.6 x ULN [1241 nmol/L], epinephrine: 12.8 x ULN [1468.3 nmol/L], dopamine <424 nmol/L. Plasma normetanephrine and metanephrines were also elevated. CT scan showed a large adrenal mass measuring 4.98 x 5.4 x 5.5 cm. Medications were oral Prazosin 3 mg five times daily and Labetalol 100 mg twice daily. She presented four weeks later with acute onset of abdominal pain, persistent vomiting, chest discomfort, vasovagal syncope, headache and sweating. She was restless, pale and hypotensive with a BP of 80/40 mmHg and HR 104 beats per minute. Abdominal examination revealed generalised tenderness, guarding and a palpable mass over the left lower quadrant. Blood pressure increased subsequently ranging from systolic 150 to 200 mmHg and diastolic 90 to 100 mmHg. ECG showed widespread deep T inversion suggestive of Wellen syndrome with raised Troponin I (1950 ng/mL). Abdominal CT revealed a ruptured left pheochromocytoma measuring 5.0 x 6.6 x 7.1 cm with a large intra-abdominal hematoma. She was started on Prazosin 2 mg three times daily and Labetalol 100 mg three times daily for blood pressure control. She was given an insulin infusion for hyperglycemia. Packed cells were also transfused. She underwent laparotomy and adrenalectomy following adequate alpha- and beta-blockade. The postoperative course was uneventful. HPE of the left adrenal mass confirmed pheochromocytoma.

#### CONCLUSION

Pheochromocytoma crisis resulting from a large release of catecholamines from a ruptured pheochromocytoma is associated with high mortality. Prompt resuscitation and

blood pressure control are the mainstays of treatment prior to surgical intervention.

## EP\_A004

### UNMASKING PRIMARY ALDOSTERONISM IN A PATIENT WITH END STAGE RENAL DISEASE: A CASE REPORT

<https://doi.org/10.15605/jafes.038.S2.22>

Nurbadriah Jasmiad, Chee Keong See, Saiful Shahrizal Shudim, Ilham Ismail, Zhe Lan Wong, Eileen Tan

Hospital Sultan Haji Ahmad Shah Temerloh, Pahang Darul Makmur, Malaysia

#### INTRODUCTION/BACKGROUND

Managing hypertension in a patient with end-stage renal disease (ESRD) requires a combination of antihypertensive medications and volume control. It is common to encounter refractory hypertension in ESRD. Investigation of primary aldosteronism (PA) as a cause of refractory hypertension in ESRD is potentially difficult. These patients are on multiple antihypertensive medications that cannot be discontinued, thus complicating the interpretation of aldosterone-renin ratio.

#### CASE

We present a patient with ESRD on peritoneal dialysis with refractory hypertension and hypokalaemia investigated for primary aldosteronism.

The patient is a 72-year-old male, known hypertensive for 40 years, with poorly controlled blood pressure for the past 20 years. The presence of refractory hypertension and hypokalaemia prompted an investigation for primary aldosteronism ten years ago, where the patient tested negative. Over the next ten years, his eGFR deteriorated, and he was initiated on peritoneal dialysis a year ago. Despite peritoneal dialysis, his BP remained poorly controlled while on six antihypertensive medications, including furosemide and spironolactone.

Despite being on six confounding antihypertensive medications, his plasma aldosterone was not suppressed and instead, elevated at 1229 pmol/L with a normal direct renin level (9 mU/L). Adrenal CT revealed bilateral adrenal adenomas. Further assessment with adrenal vein sampling was done. Surgery was explored, but the patient was not keen. Spironolactone dose was optimized which led to improvement of blood pressure control and reduction of other antihypertensive medication doses without occurrence of hyperkalemia.



## CONCLUSION

In a highly suspicious case of primary aldosteronism, a repeat screening test is warranted to prevent missing the diagnosis. Performing screening tests for PA in ESRD can be attempted but expect complexity in interpretation. Spironolactone can be given with caution in ESRD patients with PA.

## EP\_A005

### DIABETIC KETOACIDOSIS (DKA) AS A RARE PRESENTATION OF PHEOCHROMOCYTOMA

<https://doi.org/10.15605/jafes.038.S2.23>

**Marisa Masera Marzukie and Norhaliza Mohd Ali**  
 Medical Department, Hospital Sultanah Aminah, Johor Bahru, Malaysia

#### INTRODUCTION/BACKGROUND

Pheochromocytoma commonly presents with hypertension. Diabetes mellitus is one of the extremely rare metabolic complications of pheochromocytoma and is seen in a third of patients with pheochromocytoma. We present a patient with pheochromocytoma whose initial presentation was DKA.

#### CASE

A 39-year-old Indian female presented with abdominal pain and fever and was diagnosed with DKA. Her weight was 40kg with BMI of 17kg/m<sup>2</sup>. Her blood pressure was 90/60 mmHg. Underlying sepsis was suspected in the presence of leucocytosis (WBC 22x10<sup>9</sup>/L). Abdominal ultrasound showed a solitary liver lesion at segment V/V1. The CECT revealed a well-defined capsulated right suprarenal mass measuring 5.4 x 6.2 x 7.8 cm. Urine epinephrine level was elevated, 117.8 ug/day (0.5-2 ug/day), while both metanephrine and dopamine levels were normal. A diagnosis of right adrenal pheochromocytoma was made.

She was lost to follow-up but continued her diabetes management in the primary care clinic and remained on basal-bolus insulin. Four years later, she presented again with right-sided abdominal discomfort, with episodes of headache, palpitations and sweating. She also developed hypertensive crisis during this admission. CECT showed a large heterogeneously enhancing right suprarenal mass measuring 7.7 x 8.1 x 10.4 cm with mass effect to the inferior border of the liver and displacement of the right kidney with no evidence of distant metastasis. Urine metanephrine level was elevated at 82.2umol/day (0-1.62 umol/day) while urine normetanephrine level was 10.0 umol/day (0-2.13 umol/day)

She underwent right adrenalectomy. Post-operatively, she was euglycemic and normotensive and was discharged without any antihypertensives and insulin.

## CONCLUSION

Pheochromocytoma rarely presents with DKA. The presence of DM in a young, lean patient might be the clue. Hypertension might not be present in the beginning as in this patient. Close glucose monitoring intra- and post-operatively is important as hypoglycaemia may occur after tumour resection.

## EP\_A006

### MAX AND HIS FURY SPELLS: A CASE OF BILATERAL PHEOCHROMOCYTOMA WITH MAX-ASSOCIATED PATHOGENIC GENE MUTATION

<https://doi.org/10.15605/jafes.038.S2.24>

**Chee Koon Low, Kausalyaa Krishnabalan, Azraai Bahari Nasruddin, Zanariah Hussein**

Endocrine Unit, Department of Medicine, Hospital Putrajaya, Putrajaya, Malaysia

#### INTRODUCTION/BACKGROUND

Understanding of the genetic pathophysiology of pheochromocytomas and paragangliomas (PPGLs) syndrome has advanced significantly over the past two decades. PPGLs entail three specific disease clusters based on their underlying genetic alterations. Pathogenic variants affecting the Myelocytomatosis-Associated factor X (MAX) gene predispose to PPGLs occurring at a younger age. More than half develop bilateral pheochromocytomas with metastatic disease seen in 20 percent of patients.

#### CASE

This is the first case report in Malaysia describing a young male with bilateral pheochromocytoma secondary to a novel pathogenic variant identified in the MAX gene.

A 28-year-old male was found to be hypertensive during a dental procedure. Four months later, he was hospitalized due to palpitations and treated for rhabdomyolysis with non-ST-elevation myocardial infarction. Echocardiography did not show cardiomyopathy and coronary angiography was normal. Endocrine evaluation showed an elevated 24-hour urine metanephrine level of 38.8 micromol/day (24 times ULN), urine normetanephrine level of 30.8 micromol/day (14.5 times ULN), and urine methoxytyramine level of 6.5 micromol/day (3.6 times ULN). Adrenal CT revealed bilateral lipid-poor adrenal masses (Left: 7.1 x 7.5 x 7.4 cm; and right: 2.0 x 1.1 x 1.8 cm). There was no family history of multiple endocrine neoplasia or Von-Hippel



Lindau syndrome. Thyroid ultrasonography and retinal examination were normal. Our clinical dilemma was whether both adrenal lesions were pheochromocytomas. Gallium-68 PET/CT showed significant uptake in the left adrenal mass, indeterminate on the right. A genetic study identified a pathogenic variant c.234\_235dup in exon 4 of the MAX gene. Henceforth, bilateral pheochromocytoma was highly considered. Because of the metastatic potential of the disease, he underwent bilateral adrenalectomy.

#### CONCLUSION

Each PPGLs cluster has a unique clinical, biochemical and imaging phenotype which can help clinicians deliver a personalized treatment strategy for patients with PPGLs. Precision medicine approach to PPGLs should be more widely available and become the standard of care in our nation.

### EP\_A007

#### LATERAL APPROACH RETROPERITONEOSCOPIC ADRENALECTOMY: A SINGLE-CENTRE MALAYSIAN EXPERIENCE

<https://doi.org/10.15605/jafes.038.S2.25>

**Loh Chit Sin, Leslie Lai, Faridah Ismail, Saiful Kassim, Lee Chiang Heng, Liao Chee Ming, Thashvinatini Mohanavel**

*Urology Department, Gleneagles Hospital, Kuala Lumpur, Malaysia*

#### INTRODUCTION

Laparoscopic or retroperitoneoscopic adrenalectomy is now the preferred approach when adrenalectomy is indicated. We report the first series of Lateral Approach Retroperitoneoscopic Adrenalectomy.

#### METHODOLOGY

Between 2013 and 2023, a total of 46 patients (28 males, 18 females; mean age 48.4 years) were referred for minimally invasive adrenalectomy. The surgeon, a urologist, was trained in minimally invasive surgery and is a proponent of the lateral approach retroperitoneoscopic technique. Twenty-six cases involved the left side and 20 cases involved the right. The size of the lesions ranged from 6 to 80 mm (mean = 30).

#### RESULT

Mean surgery time was 90.8 minutes and mean hospital stay was 2.8 days. Two cases were converted to transperitoneal lateral approach due to the need to perform lymph node dissection. Two patients received blood transfusion.

#### CONCLUSION

Lateral approach retroperitoneoscopic adrenalectomy is safe and suitable for a wide range of adrenal pathologies and offers consistent clinical outcomes. When paracaval/paraortic lymph node dissection is necessary, it can also be converted to a transperitoneal approach. Incidentalomas are common in the private sector due to ready access to axial imaging.

### EP\_A008

#### GERIATRIC ONSET OF PHEOCHROMOCYTOMA

<https://doi.org/10.15605/jafes.038.S2.26>

**Dorothy Maria Anthony Bernard, Yi Jiang Chua, Poh Shean Wong, Zanariah Hussein**

*Hospital Putrajaya, Putrajaya, Malaysia*

#### INTRODUCTION/BACKGROUND

Elderly pheochromocytoma (age  $\geq 65$  years) is a rare phenomenon, however, there have been increased detection rates because of advances in imaging and longer life expectancy. At Putrajaya Hospital, there was a total of 60 cases of pheochromocytoma between 2013 to 2023, with only 10% (6 cases) being in the elderly category.

#### CASE

We present two cases of pheochromocytoma in the elderly who presented as adrenal incidentalomas.

An 84-year-old Malay female with hypertension, type 2 diabetes mellitus (T2DM), and chronic kidney disease (CKD) stage 2 initially presented with palpitations, and was noted incidentally to have a right adrenal mass on abdominal ultrasound. Workup revealed elevated 24-hour urinary metanephrine 14.3  $\mu\text{mol}$  (0.33-1.53) and 24-hour urinary normetanephrine 4.6  $\mu\text{mol}$  (0.88-2.88). Adrenal CT revealed a well-defined right adrenal lesion measuring (3.5 x 3.2 x 3.4 cm) with plain HU +35. Patient underwent an uneventful open right adrenalectomy which revealed an adrenal tumour measuring 6.5 x 4 x 5 cm with capsular breach. She was discharged well after 6 days. Histopathology confirmed right adrenal pheochromocytoma with vascular and capsular invasion. Postoperatively, blood pressure was controlled on two antihypertensives with normal 24-hour urinary metanephrine and normetanephrine.

A 71-year-old Chinese female with T2DM, hypertension, and CKD stage 5 presented with incidental findings of a right adrenal mass on abdominal ultrasound during CKD workup. 24-hour urinary metanephrine revealed elevated urinary metanephrine 19.56  $\mu\text{mol}$  (0.33-1.53) and 24-hour urinary normetanephrine 55.66  $\mu\text{mol}$  (0.88-2.88).



Adrenal CT revealed a right adrenal lesion measuring 5.1 x 5 x 5.7 cm with plain HU +24. The patient underwent an uneventful right open adrenalectomy and was hospitalized for 4 days. Histopathology confirmed right adrenal pheochromocytoma measuring 6 x 5 x 5.5 cm with no capsular breach. Postoperatively, blood pressure was controlled on one antihypertensive with normal 24-hour urinary metanephrine and normetanephrine.

#### CONCLUSION

Screening for elderly pheochromocytoma should not be missed and these patients should be managed in high-volume endocrine surgery centres to minimize operative complication rates.

### EP\_A009

#### PRIMARY ADRENAL LYMPHOMA WITH PRIMARY ADRENAL INSUFFICIENCY: A CASE REPORT

<https://doi.org/10.15605/jafes.038.S2.27>

Farhana Ismail,<sup>1,2</sup> Shamila Sutharsan,<sup>1</sup> Sarah Hani Johari How,<sup>1</sup> Siti Nazifah Md Rozi,<sup>1</sup> Norlaila Mustafa,<sup>1</sup> Norasyikin A. Wahab<sup>1</sup>

<sup>1</sup>Endocrine Unit, Department of Medicine, Hospital Canselor Tuanku Muhriz, Universiti Kebangsaan Malaysia, Kuala Lumpur, Malaysia

<sup>2</sup>Department of Internal Medicine, International Islamic University, Malaysia

#### INTRODUCTION/BACKGROUND

Primary adrenal lymphoma is a rare form of lymphoma and affects bilateral adrenal glands in most cases. This condition is often associated with adrenal insufficiency. We hereby report a case of bilateral primary adrenal lymphoma presenting with adrenal insufficiency in our centre.

#### CASE

A 58-year-old male with underlying hypertension presented with a 3-month history of dull lower abdominal pain, nausea, anorexia, postural giddiness, tiredness and weight loss of 5 kg. He denied any history of fever or night sweats.

At presentation, his blood pressure was 116/70 mmHg despite not taking his three antihypertensive medications for the past few days. Abdominal examination revealed bilateral flank fullness. Blood investigations showed hyponatraemia and hyperkalaemia. On clinical suspicion, early morning cortisol was sent and came back at 322 nmol/L, which was considered low in an ill patient. He was managed as adrenal insufficiency and was started on hydrocortisone replacement. Subsequently, a computed

tomography (CT) of the thorax, abdomen and pelvis with adrenal protocol was performed which revealed bilateral suprarenal masses with locoregional invasion.

Further workup showed elevated Lactate Dehydrogenase (LDH). Tuberculosis workup and fungal culture and sensitivity were all negative.

Biopsy and histopathological examination of the left suprarenal lesion revealed diffuse large B-cell lymphoma. Chemotherapy was initiated during the admission. Unfortunately, his stay was complicated with septic shock secondary to pneumonia post-induction of chemotherapy. He completed a 10-day course of antibiotics and inotropes were weaned off prior to discharge. He was advised to follow up for reassessment prior to commencing the subsequent chemotherapy cycles.

#### CONCLUSION

Primary adrenal lymphoma is rare. However, this diagnosis should be considered in a patient presenting with bilateral adrenal masses and adrenal insufficiency. In such cases, an early adrenal biopsy is crucial to confirm the diagnosis.

### EP\_A010

#### USE OF PLASMAPHERESIS IN THE MANAGEMENT OF SEVERE HYPERTRIGLYCERIDEMIA IN A PATIENT PRESENTING WITH DKA AND NSTEMI: A CASE REPORT

<https://doi.org/10.15605/jafes.038.S2.28>

Jie En Tan,<sup>1</sup> Lin Hsin Yong,<sup>2</sup> Huong Yew Ting,<sup>3</sup> Yueh Chien Kuan<sup>4</sup>

<sup>1</sup>Medical Department, Hospital Miri, Malaysia

<sup>2</sup>Dietetics and Food Services Department, Hospital Umum Sarawak, Malaysia

<sup>3</sup>Biochemistry Unit of Pathology Department, Hospital Miri, Malaysia

<sup>4</sup>Endocrinology Unit, Medical Department, Hospital Umum Sarawak, Malaysia

#### INTRODUCTION/BACKGROUND

Severe hypertriglyceridemia is defined as triglyceride level >11.3 mmol/L and is associated with significant morbidities including pancreatitis and atherosclerotic cardiovascular disease. A commonly acquired cause is insulin resistance associated with obesity and type 2 diabetes.

#### CASE

We report a case of a 49-year-old male with underlying diabetes mellitus, fatty liver and class II obesity (BMI 37) who was admitted for severe diabetic ketoacidosis



complicated with severe hypertriglyceridemia. His lipid profile was as follows: triglyceride 129.6 mmol/L, total cholesterol 24.5 mmol/L and HDL 2.90 mmol/L, with his plasma having a milky appearance. His HbA1c was 12.5%.

He was admitted to the Intensive Care Unit and was started on fixed-rate insulin infusion and intravenous fluids. He was kept nil by mouth and given pharmacotherapy (statin and fenofibrate). He had no evidence of acute pancreatitis, however, required dialysis for oliguric acute kidney injury. He later suffered from non-ST elevation myocardial infarction with transaminitis requiring discontinuation of lipid-lowering drugs. His repeated triglyceride level remained elevated at 45.2 mmol/L on day 4 of admission. He underwent one session of plasmapheresis uneventfully, with a significant reduction in triglyceride to 5.7 mmol/L. Before discharge, his treatment for DM was intensified and lipid-lowering therapy was re-commenced following normalization of liver enzymes.

Further history revealed his dietary habits consisted of a calorie-dense, high glycaemic load diet (estimated 3417 kcal/day, carbohydrates 50% of total calorie intake, protein 14.6% and fats 35%). He had no significant family history nor stigmata of hyperlipidaemia.

#### CONCLUSION

Despite the availability of effective lipid-lowering drugs, plasmapheresis remains a treatment option in severe hypertriglyceridemia, particularly in patients unresponsive or intolerant to pharmacotherapy. The rapid reduction of plasma triglyceride through plasmapheresis is effective in preventing hypertriglyceridemia-associated complications and can improve clinical outcomes in critically ill patients.

### EP\_A011

#### CONFRONTING THE CHALLENGE OF DIABETIC CYSTOPATHY WITH ESBL KLEBSIELLA PNEUMONIAE UROSEPSIS: A COMPLEX CLINICAL CONUNDRUM

<https://doi.org/10.15605/jafes.038.S2.29>

**Siti Nabihah Mohamed Hatta and Mohd Fyza Bahrudin**

Medical Department, Hospital Sultan Abdul Aziz Shah, Universiti Putra Malaysia

#### INTRODUCTION/BACKGROUND

The multisystemic nature of diabetes mellitus (DM) also affects the bladder causing diabetic cystopathy (DC), especially in middle-aged or elderly patients with long-standing poorly controlled disease, and it carries an increased risk of urinary tract infections (UTI).

#### CASE

A 54-year-old female with a background of poorly controlled DM Type 2 (HbA1c 14%) and multiple target organ damage including HF, IHD and retinopathy, presented with chronic urinary frequency and a 3-day history of fever and dysuria. Upon arrival at the hospital, she was in septic shock. Investigations revealed leukocytosis with CRP of 104 mg/L and procalcitonin of 2.24ng/ml. Her urinalysis revealed UTI, but the urine culture was negative. Subsequently, blood culture revealed growth of extended-spectrum beta-lactamase (ESBL) *Klebsiella pneumoniae*. Abdominal ultrasound revealed thickened and trabeculated urinary bladder wall. She was referred to urology and uroflow done showed a low average flow of 7.7ml/s and a high post-void residual of 180 ml suggestive of DC. In the ward, she improved after receiving intravenous Ceftriaxone for 3 days followed by Augmentin for 14 days.

The pathogenesis of DC is multifactorial. It may be secondary to autonomic neuropathy beginning with impaired bladder sensation and progressing to impaired contractility and urinary retention. Other theories involve alterations in detrusor muscle physiology and urothelial dysfunction. Those patients may be asymptomatic or may have variable voiding complaints such as overactive bladder, urge incontinence and overflow incontinence. Urodynamic evaluation is the cornerstone of diagnosis characterized by lower flow rates and higher post-void residual volumes. Patients with DM are at an increased risk of developing UTI due to impaired immune function and poor metabolic control aggravated by DC which can be further complicated by the emergence of resistant pathogens and lead to poor outcomes.

#### CONCLUSION

Proper management of DM is crucial in preventing complications such as DC and improving overall health outcomes.

### EP\_A012

#### USE OF SGLT2 INHIBITOR IN ALPELISIB-INDUCED HYPERGLYCAEMIA

<https://doi.org/10.15605/jafes.038.S2.30>

**Hidayatil Alimi Bin Keya Nordin, Lavanya Jeevaraj, Ijaz Bt Hallaj Rahmatullah**

Hospital Raja Permaisuri Bainun, Malaysia

#### INTRODUCTION/BACKGROUND

Hormone receptor-positive (HR+) and human epidermal growth factor receptor 2-negative (HER2-) breast cancer constitutes the most common form of breast cancer. Forty percent of patients with HR+/HER2- breast cancer have



mutations in phosphatidylinositol-4,5-bisphosphate 3-kinase catalytic subunit alpha, which induce hyperactivation of phosphatidylinositol 3-kinase (PI3K) contributing to resistance to endocrine therapy. The use of PI3K inhibitor (alpelisib) in combination with fulvestrant has been approved for the treatment of postmenopausal women with HR+/HER2-, PIK3CA- mutated advanced breast cancer. Hyperglycemia is the most common side effect of Alpelisib.

#### CASE

We describe a 54-year-old female with diabetes who developed uncontrolled hyperglycaemia after initiation of Alpelisib despite taking Vildagliptin and basal-bolus insulin (total daily dose: 52 units per day). Before alpelisib initiation, this patient had good glycaemic control with HbA1c of 6.7% while on Metformin 500 mg BD. Her oncologist discontinued Metformin and started the patient on Vildagliptin 50 mg OD due to renal impairment. Her blood glucose levels (monitored by a continuous glucose monitoring device) significantly worsened once alpelisib was started. On day 1 of treatment, her sugar increased to more than 10 mmol/L, thus basal-bolus insulin was started. Despite basal-bolus insulin (S/C Glulisine 12 units TDS, S/C Insulatard 16 units ON), her glucose remained in the range of 10 to 17 mmol/L. Empagliflozin was started on day 8 of Alpelisib treatment. With Empagliflozin, blood glucose levels improved, ranging between 6 to 10 mmol/L, and we were able to discontinue insulin therapy.

#### CONCLUSION

We report the successful management of alpelisib-induced hyperglycaemia with the use of SGLT-2 inhibitor.

### EP\_A013

#### SEVERE HYPERTRIGLYCERIDEMIA IN A NEWLY DIAGNOSED TYPE 1 DIABETES PATIENT WITH DIABETIC KETOACIDOSIS

<https://doi.org/10.15605/jafes.038.S2.31>

**Sherlyn Lai Hui Ern and Eunice Lau Yi Chwen**

*Hospital Sibul, Sarawak, Malaysia*

#### INTRODUCTION/BACKGROUND

Elevated triglycerides are often noticed during periods of insulin deficiency. Severe hypertriglyceridemia (Triglyceride >10 mmol/L) is an uncommon complication of diabetic ketoacidosis (DKA) and is associated with an increased risk of acute pancreatitis.

#### CASE

A 14-year-old female student with a history of COVID-19, one month prior, presented with a one-day history of severe

abdominal pain and breathlessness. This was preceded by a 2-month history of weight loss of 5 kg. She had severe metabolic acidosis and was intubated due to respiratory distress.

Laboratory results showed blood glucose of 19.8 mmol/L, serum ketones of 6.2 mmol/L, pH 6.99 and serum bicarbonate of 5.6 mmol/L. Serum amylase and urine diastase were normal. Her plasma had a "milky" appearance, and her total cholesterol level was 41 mmol/L with a triglyceride (TG) of 199 mmol/L. She was managed in the intensive care unit with fluid resuscitation, dietary restriction, fenofibrate and high-dose insulin infusion of up to 0.2 U/kg/hour. She responded well with TG levels reduced to 7.37 mmol/L on day 2 of admission. Subsequently, she was transitioned to subcutaneous insulin. Her HbA1c reduced from 15.8% to 7.3% over four months, and her TG improved to 0.5 mmol/L. Her anti-islet cell, anti-GAD and anti-insulin IA2 autoantibodies were strongly positive. Thyroid function test and screening for diabetic complications were negative.

#### CONCLUSION

Severe hypertriglyceridemia can be effectively managed in the acute situation with high-dose insulin to bring down the triglyceride level. Optimal glycaemic control also plays an important role in maintaining suppressed triglyceride levels.

### EP\_A014

#### EUGLYCAEMIC DIABETIC KETOACIDOSIS AS A CAUSE OF REFRACTORY METABOLIC ACIDOSIS IN A PREGNANT PATIENT

<https://doi.org/10.15605/jafes.038.S2.32>

**Siti Sanaa WA, Masliza Hanuni MA, Firdaus MK**

*Endocrinology Division, Medical Department, Hospital Sultanah Nur Zahirah, Kuala Terengganu, Malaysia*

#### INTRODUCTION/BACKGROUND

Euglycemic diabetic ketoacidosis (DKA) in pregnancy is a rare obstetric emergency that may lead to substantial morbidity and mortality to both the mother and foetus. Prompt recognition is challenging due to misleading euglycemic state. The risk for euglycaemic DKA increases during the second half of pregnancy due to the higher levels of hormones with anti-insulin effects, increase in insulin demand, combined with exhausted glycogen stores.

#### CASE

We report a case of a 33-year-old female G3P2 at 33 weeks AOG, admitted for fever, cough, vomiting and poor oral intake for three days. Antenatally, she had GDM and was well-controlled on metformin. On arrival she was



tachycardic with HR of 106 bpm, and tachypnoeic with RR 28/min, requiring 5 L oxygen. There were coarse crepitations over the right lower and mid-lung field.

Her laboratory results showed TWBC of  $6.5 \times 10^9/L$ , hypokalaemia (3.0 mmol/l) and mild metabolic acidosis (pH 7.43,  $HCO_3^-$  18.8 mmol/l). CXR revealed consolidation over the right lower zone. CTPA excluded pulmonary embolism. Her clinical condition deteriorated with serial blood gases in the ward showing worsening and persistent metabolic acidosis (pH 7.284,  $HCO_3^-$  12.9 mmol/l,  $pCO_2$  20.5, lactate 1.1 mmol/l) with an anion gap of 12. Her glucose readings were within the normal range, 5.3-5.9 mmol/L. We arrived at a diagnosis of euglycaemic DKA only when the urine ketone came back as ++ and blood ketone was 3.5 mmol/L. From here, IV Dextrose 10% boluses were given with 104 ml/hour maintenance over 24 hours. Concurrently, she was started on fixed-dose insulin infusion which was intensified accordingly. Ketoacidosis resolved and she was discharged well with SC levemir 8 units ON.

#### CONCLUSION

Our case highlights that it is imperative for the treating physician to have a high index of suspicion of this condition, so as to not delay lifesaving management.

## EP\_A015

### COMPARISON DIABETIC KETOACIDOSIS (DKA) ADMISSION AMONG TYPE 2 DIABETIC MELLITUS (T2DM) PATIENTS DURING PRE RAMADAN AND RAMADAN: ASSOCIATED FACTORS, OUTCOME AND SEVERITY

<https://doi.org/10.15605/jafes.038.S2.33>

Fakruradzi Z,<sup>1</sup> Wan Mohd Izani WM,<sup>2</sup> Najib Majdi Y,<sup>3</sup> Masliza Hanuni MA<sup>1</sup>

<sup>1</sup>Medical Department Hospital Sultanah Nur Zahirah Kuala Terengganu, Malaysia

<sup>2</sup>Medical Department Hospital Universiti Sains Malaysia, Kubang Kerian Kelantan, Malaysia

<sup>3</sup>Biostatistics Department Hospital Universiti Sains Malaysia, Kubang Kerian Kelantan, Malaysia

#### INTRODUCTION

Risk for DKA was increased during Ramadan in patients with advanced micro- and macrovascular complications and renal insufficiency. Associated factors are non-compliance to insulin and infections. DKA admission in Ramadan leads to prolonged hospital stay and is associated with higher mortality.

#### METHODOLOGY

This is a retrospective study conducted in a tertiary hospital in Terengganu. All DKA admissions during Ramadan and 3 months pre-Ramadan from January 2015 to December 2019 were identified. Patients with T2DM who fasted during Ramadan were included in this study. Associated factors, outcomes (length of hospital stay and mortality) and severity of DKA in Ramadan and pre-Ramadan periods were compared. This study obtained ethical approval from 2 local ethical committees.

#### RESULT

There were 117 patients included in the study. The majority of admissions were males (54.2% pre-Ramadan, 61.8% Ramadan). The mean age was 47 years (pre-Ramadan) and 40 years (Ramadan). A majority had pre-existing T2DM pre-Ramadan (96.4%) and during Ramadan (97.1%), with most patients on insulin treatment: 66.3% and 94.1%, respectively. Mean HbA1c was 12.4% for pre-Ramadan and 12.0% for Ramadan. A majority had poor compliance with treatment at 83.1% and 100% in pre-Ramadan and Ramadan, respectively. Diabetes-related complications were present in 59% (pre-Ramadan) and 85.3% (Ramadan) of patients. Insulin treatment and diabetes-related complications were significantly associated with DKA during Ramadan (adjusted odd ratio [OR] 8.00, [2.16 – 52.48],  $p$  0.007) (adjusted [OR] 3.97, [1.45 – 12.89],  $p$  0.012), respectively. No significant difference was observed in length of stay (5 days vs. 4 days) and mortality rate (7.7% vs. 8.8%). The severity of DKA pre-Ramadan was similar (30.1% mild, 38.6% moderate, 31.3% severe). During Ramadan, the majority of patients were admitted as moderately severe (76.5%).

#### CONCLUSION

Insulin treatment and diabetes-related complications were associated with DKA admission in Ramadan. There was no observed difference in length of hospital stay and mortality between groups. Majority of patients presented with moderately severe DKA during Ramadan.



## EP\_A016

### CAN ARTIFICIAL INTELLIGENCE (CHATGPT) REPLACE HEALTHCARE PROVIDERS' WORKLOAD IN MANAGING TYPE 2 DIABETES?

<https://doi.org/10.15605/jafes.038.S2.34>

**Goh Kian Guan, Mohd Syazwan Mohd Amin, Raja Nurazni Raja Azwan**

*Hospital Tengku Ampuan Afzan, Kuantan, Malaysia*

#### INTRODUCTION

ChatGPT is a large language model developed by OpenAI. It provides human-like responses to questions and solves cognitive problems by reinforcing learning via data from online human responses. Diabetes is a chronic illness and information found online can be misleading. This study aims to explore potentials of ChatGPT in providing accurate and patient-friendly diabetes knowledge.

#### METHODOLOGY

Open-ended questions pertaining to diabetes pathophysiology, complications, treatment and cure were input into ChatGPT via chat.openai.com platform. Responses were recorded and performance of ChatGPT was graded by two endocrinologists to assess the accuracy of the information.

#### RESULT

Overall, artificial intelligence performed well in delivering facts regarding general diabetes knowledge. AI explained in detail the pathophysiology of diabetes, emphasizing the role of insulin in hyperglycaemia. Complications of diabetes were laid out systematically and divided according to the organs involved, though explanations were oversimplified. The approach to treatment of diabetes was clear, where AI explained lifestyle modification followed by differentiating types of medications, including insulin and oral anti-diabetic agents. Errors were detected, such as AI mislabelling SGLT2 inhibitors as injectable medications. Monitoring and follow-up were included. Responses to inquiries regarding diabetes cure were interesting, as AI emphasized the chronic nature of diabetes. It also explored pancreatic transplantation and immunotherapy in type 1 diabetes.

#### CONCLUSION

Artificial intelligence has come a long way to provide humanoid responses to questions. It provides accurate information on most diabetes topics with nuances of diabetes educators. There was no inclusion of misinformation rampantly found in social media and web-based platforms. In conclusion, AI can assist healthcare providers in diabetic counselling and education.

## EP\_A017

### CASE SERIES OF SEVERE INSULIN RESISTANCE IN HOSPITALIZED PATIENTS

<https://doi.org/10.15605/jafes.038.S2.35>

**Wan Mohd Hafez WH,<sup>1</sup> Norhayati Yahaya,<sup>1</sup> Teh Roseleen Nadia Roslan,<sup>1</sup> Masliza Hanuni MA<sup>2</sup>**

*<sup>1</sup>Endocrinology Unit, Medical Department, Hospital Raja Perempuan Zainab 2, Kelantan, Malaysia*

*<sup>2</sup>Endocrinology Unit, Medical Department, Hospital Sultanah Nur Zahirah, Kuala Terengganu, Malaysia*

#### INTRODUCTION/BACKGROUND

Hyperglycaemia is common in hospitalized patients and is associated with poorer clinical outcomes. Multiple factors contribute to hyperglycaemia in hospitalized patients, such as underlying medical conditions, pathophysiological stress and medications. The development of transient insulin resistance is a known cause of hyperglycaemia in patients with and without diabetes, but we rarely see severe cases. Here we report 2 cases of severe insulin resistance in hospitalized patients to illustrate the challenge of managing these cases.

#### CASE

The first case is a 34-year-old male with type 2 diabetes mellitus, morbid obesity (BMI 44 kg/m<sup>2</sup>), hypertension, hyperlipidaemia and right knee arthrofibrosis. He developed severe diabetic ketoacidosis with severe insulin resistance secondary to severe pneumonia, steroid therapy and morbid obesity five days after knee surgery.

The second case is a 57-year-old female with type 2 diabetes mellitus and obesity (BMI 33 kg/m<sup>2</sup>) who developed severe insulin resistance secondary to severe pneumonia.

Both cases were treated in an intensive care unit (ICU) with high-dose insulin infusion of up to 47 units/hour and guided by Nebraska Medical Centre insulin protocol. There were good outcomes for both patients, and insulin resistance resolved after treatment of sepsis.

#### CONCLUSION

Severe insulin resistance in hospitalized patients is a challenging condition to treat. Besides using high doses of insulin, we also need to treat the underlying medical condition which can precipitate insulin resistance.



## EP\_A018

### ACQUIRED HYPOALDOSTERONISM WITH RENAL TUBULAR ACIDOSIS TYPE 4 IN A DIABETIC PATIENT

<https://doi.org/10.15605/jafes.038.S2.36>

**Calvin Ooi Gim Seong and Sivasangkari Mugilarasan**

*Department of Medicine, Hospital Taiping, Malaysia*

#### INTRODUCTION/BACKGROUND

Renal tubular acidosis (RTA) type 4 is an uncommon cause of hyperkalaemia with non-anion gap acidosis. Here we present a case of acquired hypoaldosteronism.

#### CASE

A 60-year-old female with poorly controlled diabetes (HbA1c 9.3%) and hypertension presented with a two-year history of multiple episodes of asymptomatic hyperkalaemia. She was not on RAAS blockade or drugs causing hypoaldosteronism. There was no family history of RTA. Physical examination was unremarkable. Laboratory investigations revealed hyperkalaemia (5.9 mmol/L), normal sodium (136 mmol/L), metabolic acidosis (pH 7.27; HCO<sub>3</sub> 17.8) and impaired renal function (creatinine 118 mmol/L; eGFR 43 ml/min/1.73m<sup>2</sup>). Serum cortisol was normal (517.7 nmol/L) and serum aldosterone was low (<103 pmol/L), with serum renin mildly elevated (125.60 mU/L; supine 4.2-59.7; upright 5.399.1). There was no sonographic evidence of any suprarenal mass. She was commenced on frusemide 20 mg daily. However, due to persistent hyperkalaemia, fludrocortisone 50 mcg daily was added.

RTA type 4 results from aldosterone deficiency or resistance and is associated with diabetes in 50% of cases. Hypoaldosteronism can be due to reduced stimulus to release (hyporeninaemic) or reduced synthesis or secretion (drugs like heparin, NSAIDs, ciclosporin; congenital adrenal hypoplasia); whereas aldosterone resistance can develop in target organs (pseudohypoaldosteronism) due to tubulointerstitial disease or diabetic nephropathy. Chronic hyperglycaemia can lead to diabetic and autonomic nephropathy resulting in juxtaglomerular apparatus injury or deficiency in the conversion of prorenin to active renin. However, renin levels were unexpectedly normal in our patient. Initial treatment includes a low-potassium diet, diuretics, ion-exchange resins, and in persistent cases, fludrocortisone.

#### CONCLUSION

Acquired hypoaldosteronism should be considered in the diabetic patient with mild non-anion gap metabolic acidosis and hyperkalemia, especially if disproportionate to the degree of renal impairment.

## EP\_A019

### AN AUDIT OF PATIENTS WITH TYPE 1 DIABETES MELLITUS IN RELATION TO GLYCAEMIC CONTROL AND METABOLIC PROFILE IN A TERTIARY CENTRE

<https://doi.org/10.15605/jafes.038.S2.37>

**Shireen Lui Siow Leng, Tishanti Periasamy, Shamharini A/P Nagaratnam, Nurain Binti Mohd Noor, Zanariah Hussein**

*Endocrinology Unit, Endocrine Institute, Hospital Putrajaya, Putrajaya, Malaysia*

#### INTRODUCTION

Type 1 diabetes (T1D) is a chronic disease affecting children and young adults which poses challenges to healthcare systems due to its associated microvascular and macrovascular complications. There is currently very little data focusing on this issue in Malaysia.

We aim to review the glycaemic control, metabolic profile and prevalence of acute and chronic complications of patients with T1D at the Endocrine Institute.

#### METHODOLOGY

A retrospective review was conducted using electronic medical records of patients who consulted in outpatient clinics at the Endocrine Institute between 1<sup>st</sup> December 2021 to 30<sup>th</sup> November 2022. A descriptive analysis exploring the association between glycaemic control, metabolic profile, complications treatment regimens and patient characteristics was done using SPSS version 21.

#### RESULT

A total of 143 patients were included. Glycaemic control and metabolic profiles were notably poor in this population with mean HbA1c and FBS of 9.0% and 10.0 mmol/L, respectively. LDL were elevated (>2.6 mmol/L) in nearly 80% of patients and 57.4% of patients were overweight or obese. Microvascular complications were predominant, with at least one-third of patients experiencing diabetic nephropathy or retinopathy.

#### CONCLUSION

This study found that these patients had poor overall glycaemic control and metabolic profiles, resulting in high incidence rates of chronic complications. This warrants a review of the management of T1D with emphasis on multidisciplinary specialised care and support required by these patients to improve outcomes.



## EP\_A020

### SAFETY AND EFFICACY OF DIFFERENT BASAL INSULINS IN TYPE 2 DIABETES MELLITUS WITH CHRONIC KIDNEY DISEASE DURING RAMADAN

<https://doi.org/10.15605/jafes.038.S2.38>

**Nur Haziqah Baharum, Sharifah Faradila Wan Muhamad Hatta, Nur Aisyah Zainordin, Rohana Abd Ghani**

*Department of Internal Medicine, Faculty of Medicine, University Technology MARA, Sungai Buloh, Selangor, Malaysia*

#### INTRODUCTION

Diabetic kidney disease in the Muslim population confers a high-risk for fasting in Ramadan due to various potential fasting-related complications. Basal insulin analogues, when used in place of human insulin, have shown better outcomes in terms of incidence of hypoglycaemia and glycaemic variability. There is insufficient literature comparing the safety and efficacy of the different types of basal insulins in the Malaysian setting. This study aimed to evaluate the safety and efficacy of three different basal insulins (Glargine U100, Levemir and Human Isophane Insulin) among patients with Type 2 Diabetes Mellitus and Chronic Kidney Disease stage 2 and 3 during Ramadan.

#### METHODOLOGY

This was a cross-sectional, comparative study conducted among Type 2 Diabetes Mellitus with concomitant Chronic Kidney Disease stage 2 and 3 who fasted during Ramadan in the year 2022. The primary endpoint was glycaemic variability and incidence of hypoglycaemia measured using the Abbott Freestyle Libre. Changes in glycated haemoglobin (HbA1c), fasting plasma glucose (FPG), renal profile, body weight and waist circumference were also evaluated.

#### RESULT

A total of 46 participants on three different types of basal insulin were enrolled. Glycaemic variability was highest among participants on Human Isophane Insulin with a median (IQR) of 37.2% (33) compared with Levemir 34.4% (32.4) versus Glargine U-100 36.8% (30.6),  $p=NS$ . The Levemir group registered the lowest incidence of hypoglycaemia (2%) compared to the Human Isophane Insulin and Glargine groups which had 4% respectively. When comparing pre and post Ramadan parameters, there were no statistically significant changes in glycated haemoglobin (HbA1c), fasting plasma glucose (FPG), creatinine level, body weight, body mass index, and waist circumference.

#### CONCLUSION

Basal insulin analogues offered better safety and efficacy profiles among patients with diabetic kidney disease during fasting, with insulin Levemir having the lowest incidence of hypoglycemia.

## EP\_A021

### HEMICHOREA IN A NEWLY DIAGNOSED TYPE 2 DIABETIC PATIENT

<https://doi.org/10.15605/jafes.038.S2.39>

**Nur Haziqah Baharum, Nur Aisyah Zainordin, Nur'Aini Eddy Warman, Mohd Hazriq Awang, Aimi Fadilah Mohamad, Fatimah Zaherah Mohamed Shah, Rohana Abd Ghani**

*Department of Internal Medicine, Faculty of Medicine, University Technology MARA, Sungai Buloh, Selangor, Malaysia*

#### INTRODUCTION/BACKGROUND

Chorea is a rare neurologic complication of uncontrolled Type 2 Diabetes Mellitus (T2DM). We report the case of an elderly female with newly diagnosed T2DM, presenting with hyperglycaemia-induced right unilateral hemichorea.

#### CASE

A 78-year-old female with hypertension and dyslipidaemia presented with one month history of right upper and lower limb involuntary choreiform movements which decreased during sleep. There was no history of fever, neck stiffness, limb weakness, seizure, head trauma, thyrotoxicosis, or a family history of movement disorder. There was no history of intake of medications that can cause chorea. Upon neurological assessment, there was unilateral right hemichorea involving the upper and lower limbs. The examination of higher mental function, cranial nerve, motor, and sensory system were normal.

Her plasma glucose on presentation was 22 mmol/L with no evidence of diabetic ketoacidosis or hyperglycaemic hyperosmolar state. Her glycated haemoglobin (HbA1c) was 15.9%. A non-contrast computed tomography of her brain showed a contralateral hyperdensity at the left caudate nucleus. The patient was treated with intravenous insulin and mild improvement in the choreiform movement was seen after initiation of treatment.

#### CONCLUSION

Hemichorea is a rare complication of hyperglycaemia-induced involuntary movements. High suspicion of chorea-hyperglycaemia-basal ganglia syndrome should prompt early diagnosis and treatment for diabetes mellitus as delay in recognition and treatment can lead to persistent symptoms and prolonged disability.



## EP\_A022

### A RARE CASE OF HYPERGLYCAEMIA HEMICHOREA IN A NEWLY DIAGNOSED TYPE 1 DIABETES MELLITUS PATIENT

<https://doi.org/10.15605/jafes.038.S2.40>

**Yi Jiang Chua, Zanariah Hussein**

*Division of Endocrinology, Department of Internal Medicine, Hospital Putrajaya, Putrajaya, Malaysia*

#### INTRODUCTION/BACKGROUND

Hemichorea is an uncommon presentation of hyperglycaemia. Reported cases are usually among elderly women with poorly controlled Type 2 Diabetes Mellitus in the Asian population. The difficulty of management of such cases is often due to unfamiliarity hemichorea as an associated symptom of hyperglycaemia. We report the case of a 39-year-old female, who presented with left hemichorea associated with hyperglycaemia.

#### CASE

A 39-year-old female, with history of Grave's Disease, presented with 1-week history of hemichoreoform movement of the left upper limb and lower limb. Upon presentation, her vital signs were normal and Glasgow Coma Scale (GCS) was 15. Bedside capillary blood glucose (CBG) was 21.8 mmol/L and serum plasma ketone was 2.8mmol/L, however venous blood gas was normal. Computed tomography (CT) of the brain was done revealing unilateral right caudate nucleus and putamen calcification. This patient was managed with variable rate insulin infusion initially, and overlapped with basal bolus insulin when she was more stable. Her hemichoreoform movement did not improve despite normalization of the sugar levels. Clonazepam was added to control her symptoms but only yielded partial improvement. After 1-week of benzodiazepine treatment, haloperidol was added to further control the symptoms. She was discharged with insulin therapy and 2 months upon review in the outpatient clinic, her symptoms were well-controlled and she was able to ambulate independently. Even though phenotypically she appeared to have Type 2 Diabetes Mellitus, her diabetes autoantibodies (anti-islet cell and anti-glutamic acid decarboxylase) were strongly positive. Her HbA1c had improved from 17.0% to 6.8% within 3 months' time.

#### CONCLUSION

Hemichorea is a rare presentation of hyperglycaemia. However, it is important to recognize it, as prompt glycaemic control can alleviate the symptoms alongside with symptomatic control medications such as benzodiazepine and dopamine receptor antagonist.

## EP\_A023

### ZAPPING THE ELUSIVE CULPRIT

<https://doi.org/10.15605/jafes.038.S2.41>

**Herng Pin Yam, Siow Ping Lee, Chin Voon Tong**

*Hospital Melaka, Malaysia*

#### INTRODUCTION/BACKGROUND

Hypoglycaemia among patients without diabetes is uncommon and warrants further investigation especially when Whipple's triad is fulfilled. Endocrine causes of hypoglycaemia include cortisol deficiency and endogenous hyperinsulinemia. We report the case of a 69-year-old female whose insulinoma was unmasked after cessation of glucocorticoids and subsequent management.

#### CASE

Our patient is a 69-year-old Malay female who has long standing pemphigus vulgaris (PV) since 1994 treated with oral Prednisolone. With her PV controlled, prednisolone was gradually tapered to 5 mg per week. While on weekly prednisolone, she started to experience severe symptoms of hypoglycaemia. Cosyntropin stimulation test showed a good response which excluded adrenal insufficiency as the cause of hypoglycaemia. Prolonged fasting test showed that she had endogenous hyperinsulinaemic hypoglycaemia. C-peptide was 348 pmol/l with insulin of 3 miu/l while fasting blood sugar was 1.7 mmol/l. Liver function tests and renal profile were normal.

Computed Tomography (CT) Scan and Magnetic Resonance Imaging (MRI) of the pancreas, and Endoscopic ultrasound (EUS) and Gallium-68 Dotatate PET/CT scan showed the presence of two pancreatic lesions at the head and tail of the pancreas. Fine needle aspiration cytology (FNAC) during EUS showed that the tail lesion was a Grade 1 neuroendocrine tumour. However, samples from the head lesion were unsatisfactory. Arterial stimulation and venous sampling (ASVS) confirmed that the lesion at the pancreatic tail was an insulin-secreting lesion. Oral diazoxide 100 mg twice daily was not tolerated due to bothersome leg oedema. Subsequently, hypoglycaemia resolved with successful RFA (Radio frequency ablation) of both lesions.

#### CONCLUSION

Hypoglycaemia caused by insulinoma can be masked with the use of glucocorticoids. Localization of insulinoma often requires multiple imaging, dynamic studies, and a multidisciplinary approach. RFA via EUS is a safe, minimally invasive, and effective technique for the treatment of insulinoma.



## EP\_A024

### PROBIOTICS AND INSULIN AUTOIMMUNE SYNDROME

<https://doi.org/10.15605/jafes.038.S2.42>

**Yong Siang Ng, Qing Ci Goh, Woh Wei Mak, Gayathri Devi Krishnan, Yoke Mui Ng, Shazatul Reza Mohd Redzuan, Subashini Rajoo, Mohamed Badrunizam Long Bidin**

*Hospital Kuala Lumpur, Malaysia*

#### INTRODUCTION/BACKGROUND

Insulin autoimmune syndrome (IAS) is characterized by positive insulin autoantibodies and recurrent hyperinsulinaemic hypoglycaemia in someone without diabetes as well as no prior insulin exposure. The association between probiotics and IAS has not been reported in literature. Here we describe a case of IAS induced by a probiotic supplement.

#### CASE

A 74-year-old female presented with reduced consciousness and low blood glucose (2.1 mmol/L) after taking molasses drinks the night before. She had no diabetes. During hospitalization, she experienced multiple episodes of hypoglycaemia (usually occurring postprandially) and a thorough workup revealed inappropriately elevated serum insulin levels, serum C-peptide, and the presence of insulin autoantibodies. The molasses drink tested negative for sulfonyleureas. There were no identified risk factors for IAS except she had been taking one type of probiotic pills for 2 months prior to the hospitalization. The probiotic was discontinued, and she was managed conservatively with the advice of taking a small, frequent, and low carbohydrate diet. She returned for a follow-up visit later with no more hypoglycaemia events.

IAS is a rare hypoglycaemic disorder with hypoglycaemia episodes that occur mainly postprandially. It is frequently reported in the East Asian population and its incidence is mounting due to increased awareness of the condition. IAS is commonly triggered by drugs (e.g., methimazole, alpha lipoic acid), and most cases have coexisting autoimmune disorders (e.g., Graves' disease, systemic lupus erythematosus, rheumatoid arthritis). Fortunately, IAS is usually self-limiting with good outcomes after discontinuing the offending agents or stabilizing the coexisting autoimmune diseases.

#### CONCLUSION

To our knowledge, this is the first case that highlighted the association between probiotic supplementation and IAS. Further studies to underpin the association and mechanisms are required.

## EP\_A025

### COVID-19 PANDEMIC AND VIRTUAL CLINIC FOR DIABETES CARE: A SINGLE-CENTRE EXPERIENCE

<https://doi.org/10.15605/jafes.038.S2.43>

**Sazuan S, Ida IA, Yusniza Y**

*Endocrine Unit, Hospital Sungai Buloh, Malaysia*

#### INTRODUCTION

The COVID-19 pandemic and increasing prevalence of diabetes combined with a growing shortage of new healthcare professionals presented an opportunity to digitalize diabetes care and rapidly implement virtual diabetes clinics with the aim of optimizing diabetes management and well-being while keeping patients safe, improve efficiency and reduce disease burden. We present our experience in managing our own virtual diabetes clinic in Hospital Sungai Buloh during the COVID-19 pandemic.

#### METHODOLOGY

We conducted a quantitative real time data collection between July 2020 until October 2022 from patients who attended the virtual diabetes educator clinic in Hospital Sungai Buloh. All patients received usual diabetes care along with the virtual clinic follow-up. The primary objective was to evaluate the effectiveness of a virtual diabetes clinic on HbA1c reduction, frequency of SMBG and patient satisfaction.

#### RESULT

Twenty nine (29) patients were seen in 2020, while 155 patients and 202 patients were seen in 2021 and 2022 respectively, demonstrating an increase of about 47 patients in a year. HbA1c levels before the virtual clinics ranged 8-12% and was reduced to a lower range of <6.5% to 10% after the virtual clinic sessions. Twenty eight (28) patients were able to achieve HbA1c of <6.5% within 8 months. All patients were able to comply with a self-blood glucose monitoring regimen (pre-meals and fasting) and were monitored every three weeks. We also saw an increase in the number of referrals from other departments such as obstetrics, paediatric and surgical based units, from 2 to 29 patients.

#### CONCLUSION

Virtual consultations, especially following the COVID-19 pandemic have proven to be crucial in maintaining a line of communication with people with diabetes, encouraging self-management remotely and reducing treatment burden. The virtual diabetes clinics in Hospital Sungai Buloh ensured better glucose control and implementation of good lifestyle modification despite COVID-19 restrictions.



## EP\_A026

### A GRIM TURN OF OBESITY-RELATED SURGERY: WERNICKE'S ENCEPHALOPATHY, SLEEVE GASTRECTOMY GONE WRONG

<https://doi.org/10.15605/jafes.038.S2.44>

**Mohd Fyza Bahrudin and Sanusi Zulkifli**  
*Medical Department, Hospital Sultan Abdul Aziz Shah, Universiti Putra Malaysia*

#### INTRODUCTION/BACKGROUND

Wernicke's encephalopathy (WE) is a devastating neurologic syndrome resulting from thiamine deficiency, typically affecting those with chronic alcoholism or poor nutrition, and post-bariatric surgery patients. We present a case of WE that developed after 3 months after laparoscopic sleeve gastrectomy.

#### CASE

A 38-year-old male with morbid obesity (BMI 44 kg/m<sup>2</sup>) who underwent laparoscopic sleeve gastrectomy in December 2022, was admitted due to development of a gastrocutaneous fistula and resultant intraabdominal sepsis. He was on prolonged nil by mouth and nutritional support was given through total parenteral nutrition. After one month of admission, he developed unsteadiness and blurring of vision. Physical examination noted he appeared confused, with ophthalmoplegia, bilateral horizontal nystagmus, and ataxic gait. Basic blood exams showed hypochromic microcytic anaemia with haemoglobin of 8.3 g/dL. Unfortunately, our centre was unable to provide a test for serum thiamine. Brain MRI showed symmetric hyperintensities in the thalami, mamillary bodies, tectum of the midbrain, and periventricular region, indicating Wernicke's encephalopathy. Thus, parenteral thiamine replacement was given followed by oral therapy upon discharge. A follow up visit after one month noted complete resolution of symptoms and signs.

Sleeve gastrectomy, an intervention for morbid obesity, may result to macro-micronutrient deficiency due to reduced nutrient absorption from gut alterations and reduced food intake post-surgery. Thiamine deficiency can impact the cardiovascular and nervous system, causing dry or wet beriberi. In severe cases, WE or Wernicke's Korsakoff Syndrome (WKS) may develop, and the mainstay treatment for this is to administer thiamine to reverse mental changes and prevent disease progression. Despite thiamine replacement, WE and WKS is associated with high morbidity and mortality. Our patient is fortunate to have responded well to treatment.

#### CONCLUSION

Thiamine deficiency after sleeve gastrectomy may lead to severe neurological impairments. Proactive prophylactic thiamine supplementation can significantly decrease the likelihood of WE and WKS.

## EP\_A027

### BASELINE CHARACTERISTICS OF PARTICIPANTS IN THE MOLECULAR, METABOLIC AND NUTRITIONAL CHANGES AFTER METABOLIC SURGERY IN OBESE DIABETIC PATIENTS (MOMEN) STUDY

<https://doi.org/10.15605/jafes.038.S2.45>

**Liyana Ahmad Zamri,<sup>1,2</sup> Nur Azlin Zainal Abidin,<sup>1</sup> Farah Huda Mohkiar,<sup>2,3</sup> You Zhuan Tan,<sup>2,3</sup> Fazliana Mansor,<sup>1</sup> Poh Yue Tsen,<sup>4</sup> Shu Yu Lim,<sup>4,5,6</sup> Gee Tikfu<sup>4,5,6</sup>**

<sup>1</sup>Endocrine and Metabolic Unit, Nutrition, Metabolism and Cardiovascular Research Centre, Malaysia

<sup>2</sup>Institute for Medical Research, National Institute of Health, Ministry of Health Malaysia

<sup>3</sup>Cardiovascular Unit, Nutrition, Metabolism & Cardiovascular Research Centre, Malaysia

<sup>4</sup>Sunway Medical Centre, Bandar Sunway, Petaling Jaya, Selangor, Malaysia

<sup>5</sup>iHeal Medical Centre, Mid Valley City, Kuala Lumpur, Malaysia

<sup>6</sup>Sunway Velocity Medical Centre, Sunway Velocity, Kuala Lumpur, Malaysia

#### INTRODUCTION

Metabolic surgery is proven to be effective in treating obesity-related conditions, including type 2 diabetes mellitus (T2DM). However, its impact on obese diabetic patients in Malaysia is not well understood. The MOMEN study aims to examine the molecular and metabolomic changes associated with diabetes remission in obese individuals with T2DM who undergo metabolic surgery. This paper presents the baseline anthropometric and cardiometabolic profiles of patients enrolled in the study.

#### METHODOLOGY

This study included 75 patients who underwent metabolic surgery in multiple hospitals and had a body mass index (BMI) of  $\geq 25$  kg/m<sup>2</sup> (obesity criteria defined by WHO/IASO/IOTF, 2000). Weight, height, and waist circumference (WC) measurements were obtained using a digital scale (SECA 813), a stadiometer (SECA 213), and a measuring tape (SECA 201), respectively. Fasting venous blood samples were analysed for HbA1c, uric acid, lipid, and liver profiles. Participants were categorised into three groups based on their HbA1c values (Malaysia Clinical



Practice Guidelines for the Management of T2DM, 2020): non-diabetes, pre-diabetes, and diabetes.

## RESULT

The mean age of the participants was  $37.8 \pm 8.1$  years, with a majority being female (69.3%) and Malay (65.3%). The median BMI and WC were  $38.1$  ( $16.6$ )  $\text{kg/m}^2$  and  $123.5$  ( $25.3$ ) cm, respectively. The non-diabetes group exhibited significantly lower median values for weight, BMI, WC, triglycerides, alanine aminotransferase, and aspartate aminotransferase, and higher median values for HDL-C, compared to both the pre-diabetes and diabetes groups ( $p$ -value for all comparisons  $<0.01$ ). Despite these differences, most variables, particularly lipid profiles, were elevated across all study groups and a gradual increase was observed from the non-diabetes to the diabetes group.

## CONCLUSION

The baseline characteristics of the participants revealed elevated cardiovascular risk despite the absence of diabetes. The differences between study groups in selected variables at baseline will be considered when analysing the study's future results. Follow-up data collection for 6- and 12-month post-surgery is ongoing.

## EP\_A028

### BASELINE BODY COMPOSITION OF OBESE INDIVIDUALS ACCORDING TO DIABETES STATUS IN MALAYSIA

<https://doi.org/10.15605/jafes.038.S2.46>

Nur Azlin Zainal Abidin,<sup>1</sup> Farah Huda Mohkiar,<sup>1</sup> Liyana Ahmad Zamri,<sup>1</sup> You Zhuan Tan,<sup>1</sup> Fazliana Mansor,<sup>1</sup> Poh Yue Tsen,<sup>2</sup> Shu Yu Lim,<sup>2,3,4</sup> Gee Tikfu<sup>2,3,4</sup>

<sup>1</sup>Nutrition, Metabolism and Cardiovascular Research Centre, Institute for Medical Research, National Institute of Health, Ministry of Health Malaysia

<sup>2</sup>Sunway Medical Centre, Bandar Sunway, Petaling Jaya, Selangor, Malaysia

<sup>3</sup>iHeal Medical Centre, Menara IGB, Mid Valley City, Kuala Lumpur, Malaysia

<sup>4</sup>Sunway Velocity Medical Centre, Sunway Velocity, Kuala Lumpur, Malaysia

## INTRODUCTION

Measurement of human body composition plays an important role in characterizing health status, as well monitoring treatment or intervention outcomes especially in individuals with obesity. In Malaysia, however, there is insufficient evidence of body composition among obesity with and without diabetes. This study aimed to describe the baseline body composition of obese individuals according to their diabetes status.

## METHODOLOGY

This is the baseline data of a multicentre intervention study involving obese patients undergoing metabolic surgery in Malaysia. Patients were recruited from obesity clinics and weight management centres. Patients with a body mass index (BMI)  $\geq 25$   $\text{kg/m}^2$  were categorized into 3 groups: non-diabetes, prediabetes, and diabetes. Body composition components including skeletal muscle mass (SMM), body fat mass (BFM), percentage body fat (PBF) and visceral fat area (VFA) were measured using a bioimpedance analyzer (Inbody S10). Statistical analysis was done using SPSS version 28.

## RESULT

A total of 75 patients were included in this baseline recruitment. Most participants were female ( $n=69.3\%$ ), with an overall mean age of  $37.8$  ( $\pm 8.1$ ) years. In view of major ethnicity distribution, majority of the patients are Malay (65.3%), followed by Chinese (10.7%) and Indian (10.7%). The median BMI was  $38.1$   $\text{kg/m}^2$  (IQR:  $32.7$ – $49.3$   $\text{kg/m}^2$ ). There is a significant difference in SMM, BFM, PBF and VFA between patients without diabetes and prediabetes ( $p<0.05$ ). Similarly, there was a significant difference in parameters above between patients without diabetes, and those with diabetes ( $p<0.05$ ). However, no significant difference was observed between prediabetes and diabetes group.

## CASE

Our baseline data showed there was a significant difference in body composition between obese patients with diabetes and obese patients without diabetes. It is important to investigate how metabolic surgery may influence the changes in body composition according to the diabetes risk among obese patients.

## EP\_A029

### THE PREVALENCE OF THYROID DISORDERS AMONG OVERWEIGHT AND OBESE PATIENTS IN A SINGLE-CENTRE

<https://doi.org/10.15605/jafes.038.S2.47>

Mohd Fyzal Bahrudin<sup>1</sup> and Ooi Chuan Ng<sup>2</sup>

<sup>1</sup>Department of Internal Medicine, Hospital Sultan Abdul Aziz Shah, University Putra Malaysia, Selangor, Malaysia

<sup>2</sup>Faculty of Medicine and Health Sciences, University Putra Malaysia, Selangor, Malaysia

## INTRODUCTION

Hypothyroidism can cause weight gain. While the prevalence of hypothyroidism among Malaysians is 2.1% (0.5% overt and 1.6% subclinical hypothyroidism), its prevalence among those who are overweight and obese is still unknown.



## METHODOLOGY

This is a cross-sectional cohort study among participants of the Weight Loss Journey Program in Hospital Sultan Abdul Aziz Shah, University Putra Malaysia in March 2023. Overweight is defined as BMI  $\geq 23.0$  kg/m<sup>2</sup> and obese is defined as BMI  $\geq 27.5$  kg/m<sup>2</sup>. Participants who agreed to do baseline blood exams were investigated for thyroid abnormalities.

## RESULT

There were 151 participants in the weight loss challenge. The mean age was 33 years old and majority were female (n = 124). The mean weight 80.9 kg (51.1-158.1 kg) with mean BMI of 31.6 kg/m<sup>2</sup> (23.0 – 57.5 kg/m<sup>2</sup>). A total of 72 participants consented to blood exam for serum thyroid stimulating hormone (TSH) and free thyroxine (T4) levels. The mean TSH was 1.39 uIU/mL (0.2- 3.49 uIU/mL), while the mean fT4 was 13.04 pmol/L (10.6-17.1 pmol/L). There were no participants with subclinical nor overt hypothyroidism. Paradoxically, there was a patient who had subclinical hyperthyroidism with TSH and T4 values of 0.2 uIU/mL and 15.5 pmol/L, respectively.

## CONCLUSION

Subclinical or overt hypothyroidism did not seem to be an important cause of obesity locally. Hence, we recommend that thyroid function test only be required for those who have additional clinical features of thyroid disorder.

## EP\_A030

### THE PREVALENCE OF PRE-DIABETES AND DIABETES AMONG OVERWEIGHT AND OBESE PATIENTS IN A SINGLE-CENTRE

<https://doi.org/10.15605/jafes.038.S2.48>

**Mohd Fyzal Bahrudin<sup>1</sup> and Ooi Chuan Ng<sup>2</sup>**

<sup>1</sup>Department of Internal Medicine, Hospital Sultan Abdul Aziz Shah, University Putra Malaysia, Selangor, Malaysia

<sup>2</sup>Faculty of Medicine and Health Sciences, University Putra Malaysia, Selangor, Malaysia

## INTRODUCTION

Overweight and obesity increase the risk of diabetes mellitus, and 84% of Malaysians with Type 2 Diabetes Mellitus (T2DM) are obese. While the local prevalence of prediabetes and diabetes are 11.62% and 18.3% respectively, there is paucity of data on its prevalence among those who are overweight and obese.

## METHODOLOGY

This is a cross-sectional cohort study among participants of the Weight Loss Journey Program in Hospital Sultan Abdul Aziz Shah, University Putra Malaysia in March 2023. Overweight is defined as BMI  $\geq 23.0$  kg/m<sup>2</sup> and obese

is defined as BMI  $\geq 27.5$  kg/m<sup>2</sup>. Participants who agreed to do baseline blood exams were investigated for prediabetes and diabetes by measuring their baseline fasting blood glucose (FBS) and HbA1c.

## RESULT

There were 151 participants in the weight loss challenge. The mean age was 33 years old and majority were female (n=124). Mean weight was 80.9 kg (51.1 – 158.1 kg) with mean BMI of 31.6 kg/m<sup>2</sup> (23.0- 57.5 kg/m<sup>2</sup>). Six patients were excluded as they were known to have DM. A total of 68 participants agreed to undergo screening for diabetes by measuring FBS and HbA1c. The mean FBS and HbA1c were 4.66 mmol/L (3.8- 5.9 mmol/L) and 5.5% (4.5-6.5%), respectively. Interestingly, 39.7% (27 out of 68 subjects) had prediabetes, and only 6% (4 out of 68 subjects) met the criteria for diabetes.

## CONCLUSION

Higher than normal BMI appear to pose a 3.3-fold increased risk of prediabetes compared to the general population. This is worrying given their relatively young age and only moderately high BMI levels. Nevertheless, the noted small proportion of undiagnosed DM in this patient population may reflect recent improvements in screening and detection of DM.

## EP\_A031

### LOCAL EXPERIENCE OF TOLVAPTAN IN THE MANAGEMENT OF INPATIENTS WITH SIADH

<https://doi.org/10.15605/jafes.038.S2.49>

**Jia Miin Sun and Azraai Bahari Nasruddin**

Endocrinology Unit, Hospital Putrajaya, Putrajaya, Malaysia

## INTRODUCTION

Hyponatraemia with sodium (Na) levels of less than 135 mmol/L is the most common electrolyte imbalance in clinical practice. Syndrome of inappropriate antidiuretic hormone secretion (SIADH) is a frequent cause of hyponatraemia, especially in patients with malignancy and can result in prolonged hospitalisation. Tolvaptan, an ADH-receptor antagonist, is a useful option to treat hyponatraemia in patients with SIADH and reduce inpatient stay. We developed a local treatment protocol in 2019 for the use of Tolvaptan in Hospital Putrajaya (HPJ).

## METHODOLOGY

This was retrospective study of inpatient use of tolvaptan in the treatment of SIADH-related hyponatremia in HPJ from January 2020 to March 2023. The criteria for inpatient tolvaptan use were according to the HPJ tolvaptan local guideline.



## RESULT

Data was available for 10 patients. Most of them had malignancy related SIADH. Based on our protocol, all patients were given an initial dose of Tolvaptan 7.5 mg (compared to manufacture recommendation of 15 mg) to avoid the risk of Na overcorrection. The mean baseline Na was 118 mmol/L (range 110-123 mmol/L). The mean rise in Na at 24 hours was 7 mmol/L (range 1-11 mmol/L). 9 patients had Na increment of at least 5 mmol/L at 24 hours. The remaining 1 patient had increment of Na level of only more than 1 mmol/L at 24 hours but responded to Tolvaptan 15 mg subsequently. None of the patients had overcorrection of Na (more than 12 mmol/day over 24 hours) or development of osmotic demyelination syndrome.

## CONCLUSION

This study demonstrated that inpatient tolvaptan use resulted in favourable outcomes. Our local Tolvaptan protocol is safe and effective in the treatment of SIADH-related hyponatraemia.

## EP\_A032

### ENDOCRINOPATHIES IN ADULT PATIENTS WITH TRANSFUSION-DEPENDENT THALASSEMIA IN HOSPITAL SULTANAH BAHYAH

<https://doi.org/10.15605/jafes.038.S2.50>

LW Wong, Nor Shaffinaz Yusoff Azmi Merican, Noor Rafhati Adyani Abdullah, Norasmidar Aziz, Shartiyah Ismail

*Hospital Sultanah Bahiyah, Malaysia*

## INTRODUCTION

Thalassaemia is the most common hereditary haematological disorder in Malaysia. Patients with transfusion-dependent thalassaemia (TDT) treated with frequent blood transfusion are typically at risk for developing multiple complications like endocrinopathies. Our primary objective is to determine the screening rate of endocrinopathies among our TDT patients. We also aimed to determine the prevalence of endocrinopathies and factors correlated with endocrinopathies.

## METHODOLOGY

This was a retrospective evaluation of all 113 patients with TDT who were under the care of the Haematology clinic, Hospital Sultanah Bahiyah with follow-up 6 months prior to data collection. Relevant data were retrieved from electronic medical records. Data collection was done in April 2023. Statistical analyses were performed using SPSS version 11.0.

## RESULT

Median age of our cohort is 31 years (Interquartile range 18 years), and 50.4% of the patients were female. Majority of the patients (92%) received at least one endocrinopathy screening. The most commonly screened endocrinopathies were hypothyroidism (82%), followed by diabetes mellitus (66%) and hypoparathyroidism (53%). About 39% of our patients have at least one endocrine complication. Of these, 24% had one endocrinopathy, 11.5% had two endocrinopathies while 3.6% had 3 or more endocrinopathies. Growth failure (58%) was the most prevalent endocrinopathy among our cohort, followed by hypocortisolism (50%) and osteopenia (48%) while prevalence of hypothyroidism was 15%. There were significant correlations between ferritin level and liver iron concentration (LIC) [ $p < 0.01$ ] and cardiac iron concentration (CIC) [ $p < 0.01$ ]. No significant correlation was found between ferritin level and the presence of endocrinopathies, or between LIC and CIC with the presence of endocrinopathies.

## CONCLUSION

There was a low screening rate for endocrinopathies among our patients, particularly for osteoporosis, growth failure, hypocortisolism and hypogonadism. This audit shall serve to raise the awareness of healthcare practitioners to screen for endocrinopathies among patients with TDT.

## EP\_A033

### SUCCESSFUL PREGNANCY IN A HOMOZYGOUS FAMILIAL HYPERCHOLESTEROLEMIA PATIENT REQUIRING LIPID APHERESIS AND MULTIDISCIPLINARY TEAM MANAGEMENT

<https://doi.org/10.15605/jafes.038.S2.51>

Siau Chenn Khong, Ashcwiniswarie Gunasegaran, Nurul Atikah Hamza, Hazwani Aziz, Sadanah Aqashiah Mazlan, Elliyyin Katiman

*Hospital Kajang, Malaysia*

## INTRODUCTION/BACKGROUND

Familial hypercholesterolemia (FH) is an inherited disorder of lipid metabolism mainly due to the mutation of the low-density lipoprotein (LDL)-receptor gene (LDLR). The more severe homozygous form of the disease is characterised by premature atherosclerotic disease before 20 years old. Pregnancy in women with homozygous familial hypercholesterolemia (HoFH) can be fatal to both mother and foetus. Since Lipid Apheresis (LA) is scarce in Asia and statin generally is contraindicated in pregnancy, treatment to keep low-density lipoprotein-cholesterol (LDL-C) at low levels remain challenging during pregnancy, necessitating a multidisciplinary team approach. We illustrate the case



of a 24-year-old primigravida with HoFH who underwent LA and successfully delivered her baby at 35 weeks age of gestation.

#### CASE

A 24-year-old female diagnosed with HoFH at 7 years old, presented at 7 weeks pregnancy with hyperemesis gravidarum. She previously required regular plasma exchange from the age of 8 but subsequently defaulted treatment at 16 years old. Clinical examination revealed widespread multiple xanthomata over both hands, feet and elbows. Her baseline total cholesterol was 15 mmol/L and LDL-C was 13.2 mmol/L. She was initiated on bi-weekly plasma exchange. However, she developed intradialytic hypotension complicated by fistula failure following a second exchange, which necessitate double filtration plasmapheresis (DFPP), which is more specific for lipid apheresis. The LDL-C levels were reduced by an average of 46% following each treatment. Her pregnancy was complicated by two hospitalisations for suspected Acute Coronary Syndrome. Cardiology referral was made for re-assessment of coronary arteries. Fortunately, echocardiography and dobutamine stress test both showed normal findings. At 35 weeks of gestation, the patient successfully delivered a healthy baby boy weighing 1.6 kg via emergency caesarean section for foetal complication with good Apgar score.

#### CONCLUSION

This case demonstrated a favourable pregnancy outcome when LA along with good multidisciplinary support was utilized in a pregnant patient with HoFH.

### EP\_A034

#### THE USE OF THERAPEUTIC PLASMA EXCHANGE IN A PATIENT WITH RECURRENT SEVERE HYPERTRIGLYCERIDEMIA-INDUCED ACUTE PANCREATITIS

<https://doi.org/10.15605/jafes.038.S2.52>

**Wei Wei Ng and Wai Leong Liew**

*Hospital Raja Permaisuri Bainun, Ipoh, Malaysia*

#### INTRODUCTION/BACKGROUND

Severe hypertriglyceridemia (HTG)-induced acute pancreatitis is defined by clinical, laboratory and radiographic evidence of acute pancreatitis with triglyceride (TG) levels of >11.2 mmol/L in the absence of other causative factors. We report a case of therapeutic plasma exchange (TPE) used in recurrent severe HTG-induced acute pancreatitis who failed conventional treatment.

#### CASE

The patient is a 28-year-old female with poorly controlled Type 2 diabetes mellitus diagnosed 4 years ago with HbA1c range of 10-13% despite on Insulin Actrapid 30 u three times daily, Insulin glargine 36 u daily and Metformin 1g twice daily. Her TG levels remained elevated despite being on daily 145 mg of Fenofibrate, 40 mg of Rosuvastatin, and 4 gm of Omega-3-free fatty acid. Xanthelasma, tuberous or tendon xanthomata were absent. She denied a family history of hypertriglyceridemia. She was non-alcoholic and her thyroid screen was normal. Obesity and poor compliance with lifestyle changes and medications alongside poorly controlled diabetes contributed to severe hypertriglyceridemia. She had recurrent admissions for severe HTG-induced acute pancreatitis within the past 2 years. During each admission, she was given supportive treatment including fasting with bowel rest, analgesia, intravenous hydration, and insulin infusion. She failed to respond to conservative measures and required TPE for 3 of her 6 admissions. Her TG level was >64 mmol/L during these 3 admissions with persistent severe abdominal pain lasting more than 48-72 hours despite fentanyl infusion. Fresh frozen plasma was used as replacement fluid during each TPE session. TG levels dropped by 80-85% after a single TPE with TG levels on discharge decreased to a range of 2.3-5.5 mmol/L.

#### CONCLUSION

This case highlights the potential utility of TPE during acute pancreatitis by rapidly decreasing TG levels and reducing inflammatory cytokines. However, the TPE effect is transient and the patient requires adequate lipid-lowering treatment to achieve lasting effects.

### EP\_A035

#### HEPATOMA-ASSOCIATED NON-ISLET CELL TUMOR HYPOGLYCEMIA: A CASE REPORT

<https://doi.org/10.15605/jafes.038.S2.53>

**Jen Hoong Oon, Yon Li Ho, Chin Voon Tong, Noor Hafis Md Tob, Siow Ping Lee, Melissa Vergis**

*Department of Medicine, Hospital Melaka, Malaysia*

#### INTRODUCTION/BACKGROUND

Non-islet cell tumour hypoglycaemia (NICTH) is a rare condition due to excessive secretion of insulin-like growth factor-2 (IGF-2) or pro-IGF-2. NICTH is commonly associated with hepatocellular carcinomas.

#### CASE

We reviewed case notes, investigation results, imaging studies and discussed treatment options based on literature review.



A 73-year-old Chinese male with a history of type 2 diabetes mellitus, hypertension and stage IV chronic kidney disease presented to emergency department with syncope attack and capillary blood glucose of 1.9 mmol/L. Initial examination revealed massive hepatomegaly. A 4-phase CT scan of the liver showed multicentric hepatocellular carcinoma. Biochemical investigations revealed hypoinsulinaemic hypoglycaemia, elevated alpha-fetoprotein (AFP) at 135,937 IU/mL, markedly suppressed insulin-like growth factor-1 (IGF-1) and normal IGF-2 level. The IGF-2: IGF-1 ratio was 50:1. He was started on oral prednisolone, titrated up to 25mg twice daily to maintain euglycemia. After discussion with surgical and oncology teams, patient opted for conservative management.

Elevated IGF-2 or pro-IGF-2 exerts insulin mimicking effects leading to hypoglycaemia. The diagnosis of NICTH is based on the IGF-2: IGF-1 ratio, which is higher than 10:1, along with inappropriately suppressed IGF-1. Curative treatment for NICTH is complete resection of the tumour. Glucocorticoids is important to maintain euglycemia on top of nutritional support and glucose infusion. Glucagon has a limited role as adjunct therapy. Diazoxide and octreotide were found ineffective.

#### CONCLUSION

This is a case of hepatoma-associated NICTH, which was managed with oral prednisolone to maintain euglycemia. Due to advanced disease, we were unable to deliver definitive treatment. High level of suspicion of NICTH is crucial in patients with recurrent hypoglycaemia on a background of malignancy.

### EP\_A036

#### RENINOMA: A SURGICALLY CURABLE CAUSE OF HYPERTENSION

<https://doi.org/10.15605/jafes.038.S2.54>

**Gaayathri Krishnan**

*Endocrinology, Ministry of Health, Malaysia (KKM)*

#### INTRODUCTION/BACKGROUND

Reninoma is an extremely rare cause of hypertension. It is a tumour of the juxtaglomerular apparatus which secretes renin, leading to secondary hyperaldosteronism, ultimately causing hypertension. This disease is commonly seen in adolescents and young adults and has a female preponderance. Patients with reninoma mostly present with hypokalaemia although they can also be normokalaemic. Most reninomas are benign and surgical resection can render the patient normotensive. Here we report a case of reninoma in a young female who presented with hypertension and palpitations.

#### CASE

We describe a 23-year-old female who was referred for evaluation of hypertension in the young. She was found to have a BP ranging between 130-180 mmHg (systolic) and 85-120 mmHg (diastolic). She was diagnosed with hypertension and started on oral doxazosin. She complained of paroxysms of sweating with palpitations. On examination, she was a moderately built female with a body mass index of 20.4kg/m<sup>2</sup>. Her pulse rate was 100 beats per minute and her BP was 153/100 mmHg.

Her renin levels were elevated at 518 mU/L (NV: 4.4- 46.1 mU/L) with elevated aldosterone at 998 pmol/L (NV: 61.2- 997.8 pmol/L). Computed tomography of abdomen and pelvis revealed the presence of a well encapsulated heterogeneously enhancing mass on the upper pole of the right kidney measuring 2.7 x 3.0 x 3.3 cm. A biopsy of the lesion was suggestive of a reninoma. The patient underwent a nephron-sparing surgery. Histopathological examination revealed an encapsulated lesion that stained positive for CD 34, CD 177 and vimentin, confirming the diagnosis. Following surgery, the patient was normotensive and all anti-hypertensive medications were withheld.

#### CONCLUSION

Reninomas are mostly benign neoplasms that can lead to hypertension and severe end-organ damage. High clinical suspicion is required to diagnose this disease, and nephron-sparing surgery can render the patient normotensive.

### EP\_A037

#### A BONY PREDICAMENT: CATCHING THE CULPRIT IN THE CHEST

<https://doi.org/10.15605/jafes.038.S2.55>

**Quan Hziung Lim, Nicholas Ken Yong Hee, Ken Seng Chiew, Marisa Khatijah Borhan, Katherine Khor, Ee Wen Loh, Tharsini Sarvanandan, Sharmila Paramasivam, Lee Ling Lim, Jeyakantha Ratnasingam, Siew Pheng Chan, Shireene Ratna Vethakkan**

*Endocrinology Unit, Department of Medicine, Universiti Malaya Medical Centre, Kuala Lumpur, Malaysia*

#### INTRODUCTION/BACKGROUND

We report a case of mediastinal parathyroid adenoma as a rare cause of severe hypercalcemia and bone deformities.

#### CASE

A 19-year-old male presented with progressively worsening scoliosis and restrictive chest wall deformity over 4 years. He underwent chest wall reconstruction surgery with insertion of a titanium plate. Hypercalcemia was incidentally



diagnosed perioperatively. He had polydipsia and weight loss but denied other symptoms. Past medical history and family history were unremarkable. He was small in stature with a body mass index (BMI) of 12.6 kg/m<sup>2</sup>, severely scoliotic spine and pectus excavatum and no palpable neck masses.

Skeletal survey showed multiple malunited fractures and lytic bone lesions. Biochemical investigations revealed severe hypercalcemia with a peak level of 4.38 mmol/L and a markedly elevated intact PTH (iPTH) level of 695.3 pmol/L. Initial technetium-99m-sestamibi (MIBI) parathyroid scintigraphy showed no uptake over the neck and neck ultrasound revealed no masses. A subsequent whole-body MIBI with SPECT-CT showed avid uptake at the anterosuperior mediastinum, corresponding to a contrast-enhancing mass seen on CT-scan, measuring 17 x 30 x 18 mm. Genetic screening was negative for mutations in CASR, MEN1, MEN2 and MEN4 genes.

Hypercalcemia was controlled with subcutaneous denosumab and oral cinacalcet before subsequent surgical resection. The mediastinal mass removed measured 55 mm in diameter and weighed 12.5 grams. Histopathological examination revealed tissue predominantly comprising chief cells, confirming an ectopic PTH adenoma. Post-operatively, his iPTH levels normalized and he required high doses of alfacalcidol.

#### CONCLUSION

Mediastinal adenomas are ectopic parathyroid adenomas that form because of aberrant embryological migration of inferior parathyroid glands. They may pose a diagnostic challenge leading to unnecessary surgical explorations. MIBI scans can improve diagnostic accuracy. Ectopic parathyroid adenomas make up 16-22% of parathyroid adenomas, of which 6-13% are mediastinal adenomas. Patients with primary hyperparathyroidism and initial negative neck imaging should prompt suspicion and work-up for mediastinal parathyroid adenoma.

## EP\_A038

### PRIMARY HYPERPARATHYROIDISM IN PREGNANCY, INITIAL PRESENTATION WITH HYPOCALCAEMIA SECONDARY TO ACUTE PANCREATITIS AND SEPSIS

<https://doi.org/10.15605/jafes.038.S2.56>

**Alvin Gnanasegaran and Sivasangkari Mugilarasan**

*Endocrine Unit, Department of Medicine Hospital Taiping, Malaysia*

#### INTRODUCTION/BACKGROUND

Diagnosis of primary hyperparathyroidism is challenging during pregnancy and requires special care to prevent complications such as nephrolithiasis, pancreatitis, preterm delivery and foetal demise. We are reporting a rare case of primary hyperparathyroidism initially presenting with severe hypocalcaemia.

#### CASE

A 25-year-old primigravida at 24 weeks of gestation was admitted to intensive care unit with decompensated septic shock and acute kidney injury requiring ventilatory support. Subsequently, she had chorioamnionitis and non-viable foetus resulting in premature delivery. CECT of the abdomen showed acute pancreatitis in the absence of gallstone and caecal perforation with extensive peritonitis. She then underwent laparotomy. Other laboratory results showed elevated white blood count (29.7 g/d) and serum creatinine (173 micromol/L) with reduced eGFR (35 ml/mol/1.73 m<sup>2</sup>), hypocalcaemia (1.79 mmol/L (corrected)), hypoalbuminemia (21 g/L), with normal phosphate (0.91 mmol/L). She required multiple intravenous calcium corrections for the first 3 days. The serum calcium showed gradual increment from 2.4 mmol/l to 4.07 mmol/L within 10 days without calcium or vitamin D supplementation and adequate hydration. Intact parathyroid hormone (iPTH) was 43 pmol/L but repeat test was elevated at 148 pmol/L. She required intravenous zoledronate 4 mg with bridging calcitonin given 3 weeks apart. She had severe vitamin D deficiency of <5 ng/mL for which she was started on replacement. Patient denied familial hypercalcaemia or MEN syndrome. Ultrasound of the neck did not locate a parathyroid adenoma. Therefore, she is awaiting sestamibi scan and genetic testing to rule out familial causes of primary hyperparathyroidism is being considered.

#### CONCLUSION

Hypocalcaemia is a common finding in acute pancreatitis due to mesenteric calcium salt formation. It is also present in critically ill patients with sepsis which is a marker of severity with increased mortality and hospital stay.



Hypercalcaemia was unmasked later in this case upon the resolution of the above-mentioned conditions. During pregnancy, surgery is the treatment of choice during the second trimester in cases of severe hypercalcaemia (calcium >3.0 mmol/L) because medical therapy options are unsafe.

## EP\_A039

### A CHALLENGING CASE OF FAMILIAL HYPOCALCIURIC HYPERCALCEMIA CONCEALED BY CONCOMITANT VITAMIN D DEFICIENCY AND PAPILLARY THYROID CARCINOMA

<https://doi.org/10.15605/jafes.038.S2.57>

**Vanusha Devaraja, Shazatul Reza Mohd Redzuan, Subashini Rajoo**

*Endocrine Unit, Medical Department, Hospital Kuala Lumpur, Malaysia*

#### INTRODUCTION/BACKGROUND

Familial hypocalciuric hypercalcaemia (FHH) is a rare autosomal-dominant disorder resulting from an inactivating mutation in the calcium-sensing receptor (CASR) gene. It is generally benign and characterized by longstanding parathyroid hormone (PTH) - dependent hypercalcaemia. Resection of the parathyroid tissue does not normalize serum calcium.

#### CASE

We report a case of FHH with evaluation confounded by vitamin D deficiency and newly diagnosed papillary thyroid carcinoma.

A 63-year-old female was incidentally noted to have hypercalcaemia with elevated PTH during admission for pneumonia. She had completed antituberculosis therapy for gastrointestinal tuberculosis 2 years ago. The baseline vitamin D level was 24nmol/L (NV: 75-100), and the 24-hour urine calcium creatinine ratio was 0.01. Bone mineral density revealed an osteopenic spine. Focused parathyroidectomy was performed after technetium (<sup>99m</sup>Tc) sestamibi SPECT scan which revealed a left superior parathyroid adenoma. However, the calcium levels remained elevated. Histopathological examination of the postoperative sample revealed a metastatic papillary thyroid carcinoma in the lymph node. Hence, she underwent total thyroidectomy, left modified neck dissection, and total parathyroidectomy with auto-transplantation of parathyroid tissue into the presternal space. Albeit that, the serum calcium and PTH remained elevated. PTH-related protein (PTHrP) and 1,25 hydroxy vitamin D levels were within normal range. Opportunistic screening of her daughter revealed that she had raised calcium levels with inappropriately normal

PTH and 24-hour urinary calcium creatinine ratio of less than 0.01. The patient's repeated 24-hour urinary calcium creatinine ratio after repletion of vitamin D was also less than 0.01. We diagnosed her with FHH based on positive family screening and longstanding asymptomatic PTH-dependent hypercalcaemia refractory to parathyroidectomy.

#### CONCLUSION

Our case highlights the diagnostic dilemmas in hypercalcaemia, the importance of screening family members and the repetition of 24-hour urine calcium creatinine ratio after correction of vitamin D deficiency.

## EP\_A040

### TERIPARATIDE [HUMAN PARATHYROID HORMONE (PTH) 1-34] FOR THE MANAGEMENT OF POST-THYROIDECTOMY HYPOCALCEMIA EXACERBATED BY CHYLE LEAK

<https://doi.org/10.15605/jafes.038.S2.58>

**Ken Seng Chiew, Quan Hziung Lim, Nicholas Ken Yoong Hee, Sharmila Paramasivam, Lee Ling Lim, Jeyakantha Ratnasingam, Shireene Vethakkan**

*Endocrine Unit, Department of Medicine, University of Malaya Medical Centre, Malaysia*

#### INTRODUCTION/BACKGROUND

Hypocalcaemia secondary to hypoparathyroidism is a common complication of thyroidectomy. Another less common but serious complication is chyle leak which may also lead to electrolyte abnormalities, including hypocalcaemia. We report a case of refractory hypocalcaemia following thyroidectomy complicated by chyle leak which was successfully managed with teriparatide.

#### CASE

A 37-year-old male had undergone total thyroidectomy with central and left lateral neck dissection for papillary thyroid carcinoma. After the surgery, up to 200 cc/day of milky fluid were noted in his neck drain. Biochemical analysis showed high triglyceride content (2.3 mmol/L), consistent with chyle. He was initially treated conservatively with total parenteral nutrition, pressure dressing and subcutaneous octreotide.

On postoperative day (POD) 3, he had symptomatic hypocalcaemia (corrected calcium 1.95 mmol/L). PTH was undetectable (<0.5 pmol/L). However, despite intravenous calcium gluconate infusion, high doses of activated vitamin D and calcium supplements (calcitriol 4.5 mcg/day, alphacalcidol 2 mcg/day and calcium carbonate 6 g/day), his calcium level remained as low as 1.9 mmol/L by POD



10. Subcutaneous teriparatide was then started, titrated up to 20 mcg, bid. This stabilized his corrected calcium at 2.1 mmol/L.

On POD 16, the chyle leak was successfully sealed surgically. By POD 19, his calcium level improved to 2.34 mol/L. Subcutaneous teriparatide was discontinued after a course of 14 days. To date, 5 months after his surgery, he is normocalcaemic while on alphacalcidol 2.5 mcg/day and calcium carbonate 3 g/day. His PTH remains undetectable.

Chyle leak occurs in 0.5-1.4% of thyroidectomies and 2-8% of neck dissections. As the thoracic duct ends at the junction of the left subclavian and jugular veins, most chyle leaks occur following left neck dissection. About 70% of chyle consist of dietary fats. Hence, asides from calcium, chyle leak also results in loss of dietary fat-soluble vitamins, including vitamin D.

#### CONCLUSION

Post-thyroidectomy hypocalcaemia due to hypoparathyroidism can be exacerbated by chyle leak, thus necessitating use of parenteral therapy with teriparatide.

### EP\_A041

#### OSTEOMALACIA SECONDARY TO RENAL TUBULAR ACIDOSIS TYPE 1 WITH VITAMIN D DEFICIENCY

<https://doi.org/10.15605/jafes.038.S2.59>

**Lavanya Jeevaraj, Anilah AR Rahman, Ijaz Hallaj Rahmatullah**

*Hospital Raja Permaisuri Bainun Ipoh, Malaysia*

#### INTRODUCTION/BACKGROUND

Osteomalacia is a disease of inadequate bone mineralization. The true incidence of osteomalacia is largely underestimated. Patients may develop bone pain, muscle weakness and fractures and in severe untreated cases may become bed-bound. Osteomalacia is known to be associated with RTA types 1 and 2.

#### CASE

We report a 41-year-old female with RTA type 1 who had presented to us after applying for disability pension. She has been having muscle weakness and bone pain which progressed to gait abnormalities and had become bedridden and dependent on activities of daily living. She previously defaulted all her follow-ups and was found to have severe vitamin D deficiency with untreated acidosis. Neuromuscular dystrophy was excluded. Her initial BMD showed a hip Z-score of -3.9 and T-score of -4.0 (April 2019). She was treated with vitamin D<sub>3</sub> 7,000 units/day

(50,000 units weekly), calcium lactate 300 mg od and Shol's solution 20 ml qid. Subsequent follow up showed gradual improvement in muscle strength with normalized BMD within 3 years and resulting in patient being independent.

#### CONCLUSION

We report the successful recognition and management of osteomalacia with RTA type 1 and Vitamin D deficiency.

### EP\_A042

#### A RARE CASE OF PREGNANCY LACTATION-INDUCED OSTEOPOROSIS

<https://doi.org/10.15605/jafes.038.S2.60>

**Wan Mohd Hafez Wan Hamzah, Norhayati Yahaya, Teh Roseleen Nadia Roslan**

*Endocrinology Unit, Medical Department, Hospital Raja Perempuan Zainab 2, Kelantan, Malaysia*

#### INTRODUCTION/BACKGROUND

Pregnancy and lactation-induced osteoporosis (PLO) is a rare condition occurring for the first time in pregnancy or postpartum period while breastfeeding. Here, we report a rare case of PLO which presented during postpartum of first pregnancy.

#### CASE

A 27-year-old female presented with low back pain 4 months postpartum of her first pregnancy and worsening during her second pregnancy. It was associated with kyphotic lordosis. PLO was diagnosed based on clinical symptoms and low bone mineral density (BMD).

#### CONCLUSION

PLO should be considered in patients who complain of back pain during late pregnancy and postpartum period. Weaning off breastfeeding and supplementation of calcium/vitamin D should be the first recommendation as conventional treatment after the diagnosis of PLO. Bisphosphonate, teriparatide and denosumab can be added on as specific pharmacological therapy if conservative treatment fails.



## EP\_A043

### THE CURIOUS CASE OF THE HIDDEN PARATHYROID GLAND: TWO CASE SERIES

<https://doi.org/10.15605/jafes.038.S2.61>

Nur Hidayah MM, Masliza Hanuni MA, Siti Sanaa WA

*Endocrine Unit, Hospital Sultanah Nur Zahirah, Terengganu, Malaysia*

#### INTRODUCTION/BACKGROUND

The main challenge in managing primary hyperparathyroidism is localization of hyperfunctioning parathyroid gland. This step is crucial prior to parathyroidectomy to ensure effectiveness of surgical treatment and reducing the risk of re-operation.

#### CASE

We encountered 2 cases with difficulty in localizing the parathyroid gland. The first case, 34-year-old female, presented with renal colic and noted to have bilateral renal calculi and hypercalcemia (calcium 2.94 mmol/L, phosphate 0.64 mmol/L). The second case, 46-year-old female, presented with body weakness and incidental finding of hypercalcemia (calcium: 2.84 mmol/L, phosphate: 0.52 mmol/L). Both have high serum iPTH of 98.5 pg/ml and 83.9 pg/mL, respectively. Bone mineral density revealed total Z-score of - 0.7 and - 2.1, respectively. Their kidney ultrasound showed bilateral medullary nephrocalcinosis. Both cases were diagnosed with primary hyperparathyroidism.

For the first case, initial neck ultrasound and sestamibi scan failed to localize any parathyroid adenoma. FDG-PET scan showed no evidence of uptake elsewhere. CT of the neck with delayed venous phase revealed single nodule seen at the upper border of left thyroid gland. A repeat neck ultrasound showed a single hyperechoic nodule in concordance with findings in the CT of the neck.

In the second case, neck ultrasound revealed 2 intrathyroidal lesions at bilateral lower pole of the thyroid gland. Sestamibi scan showed no evidence of hyperfunctioning parathyroid tissue. CT of the neck with delay venous phase revealed similar intrathyroidal nodular lesion seen in the ultrasound. However, no hypodensity was seen in delayed venous phase which was not a suggestive feature of parathyroid adenoma.

Left superior parathyroidectomy was planned for the first patient. Meanwhile, an exploratory bilateral inferior neck surgery is scheduled for the second patient.

#### CONCLUSION

There are few reasons contributing to a false-negative sestamibi scan. In addition, neck ultrasound is operator-dependant. Hence, alternative imaging modalities are important to help with parathyroid gland localization.

## EP\_A044

### PARATHYROID CARCINOMA PRESENTING AS PRIMARY HYPERPARATHYROIDISM IN ADOLESCENCE

<https://doi.org/10.15605/jafes.038.S2.62>

Thamarai Supramaniam<sup>1</sup> and Siti Aishah Mahamad Dom<sup>2</sup>

<sup>1</sup>*Department of Internal Medicine, Hospital Shah Alam, Malaysia*

<sup>2</sup>*Hospital Shah Alam, Malaysia*

#### INTRODUCTION/BACKGROUND

Parathyroid carcinoma is an extremely rare cause of primary hyperparathyroidism in adolescence. Despite being malignant in nature, the diagnosis is often delayed and is already severe at presentation.

#### CASE

We present a 16-year-old male with background of delayed developmental milestones presenting with recurrent seizures. On physical examination, there were no syndromic features, bony deformities or neurological deficits. Laboratory examination revealed severe hypercalcaemia (3.64 mmol/L), low serum phosphate (0.4 mmol/L), elevated serum ALP (2121 U/L), normal range for 16-year-old male: 68-430 U/L) and a normal renal profile. Serum intact parathyroid hormone (iPTH) was elevated (186 pg/ml, normal range: 15-57 pg/ml). The 25-hydroxy vitamin D was normal (75.59 nmol/L). Thyroid function test was also normal. Ultrasound of the neck revealed a hypoechoic lesion posterior to the right thyroid gland measuring 1.6 x 2.5 x 2.9 cm. Neck CT confirmed an enlarged right parathyroid gland measuring 1.9 x 3.0 x 2.6 cm with no evidence of adjacent organ infiltration. The 99mTechnetium (Tc) sestamibi scan was not performed due to patient's poor cooperation. Hypercalcaemia was managed with intravenous saline, iv pamidronate 90 mg and sc denosumab 60 mg. He underwent right parathyroidectomy and hemithyroidectomy with central lymph node dissection. Intra-operatively, the right inferior parathyroid was grossly enlarged and adhered to the right thyroid lobe and distal part of the right recurrent laryngeal nerve. Histopathology examination of the parathyroid gland confirmed a nodular mass weighing 5 g and measuring 30x28x9 mm with central cervical lymph node infiltration. The cytomorphological features with increased mitotic activity (11 per 50 hpf) and the presence of vascular invasion strongly favoured



the diagnosis of parathyroid carcinoma. Post operatively, the course was complicated with hungry bone syndrome. At discharge, the patient's iPTH and calcium level was reduced to 6.66 pg/ml and 2.20 mmol/L, respectively.

#### CONCLUSION

Size of parathyroid lesion, severe hypercalcaemia, significantly raised ALP and iPTH levels are clues to indicate parathyroid carcinoma as the cause of primary hyperparathyroidism.

### EP\_A045

#### COVID-19 MOVEMENT CONTROL ORDER RELATED OSTEOPOROTIC FRACTURE AND VITAMIN D DEFICIENCY IN AN ADOLESCENT MALE

<https://doi.org/10.15605/jafes.038.S2.63>

Suhasheni Rajendran,<sup>1</sup> Chu Ee Seow,<sup>1</sup> Jerri Chiu Yun Ling,<sup>2</sup> Hui Chin Wong<sup>3</sup>

<sup>1</sup>Department of Internal Medicine, Hospital Banting, Malaysia

<sup>2</sup>Sports Medicine Unit, Department of Orthopaedic, Hospital Tengku Ampuan Rahimah Klang, Malaysia

<sup>3</sup>Endocrinology Unit, Department of Internal Medicine, Hospital Tengku Ampuan Rahimah Klang, Malaysia

#### INTRODUCTION/BACKGROUND

COVID-19 pandemic had caused major impacts on various aspects of our life. In Malaysia, Movement Control Order was imposed in March 2020. For almost 2 years, school-going children and adolescents were not able to attend schools physically and their physical activity was confined to their room or house on most days.

#### CASE

We describe a case of a 14-year-old male, previously active in sports, who sustained a low trauma fracture at the right femoral neck in November 2021 following a prolonged period of extreme sedentary life along with poor dietary intake during the COVID-19 pandemic period. He underwent open reduction and screw fixation for the fracture. Postoperatively, he was initially treated with suboptimal physiotherapy due to worry of fragility fracture. He was thin with a low BMI (15.62 kg/m<sup>2</sup>) and significant loss of muscle bulk in all limbs. Further laboratory tests showed vitamin D deficiency (15.3 nmol/L) and the dual energy x-ray absorptiometry (DXA) showed low Z-score for total spine (-2.2) and total hip (-3.9). He was treated with activated vitamin D and vitamin D<sub>3</sub> replacement. He was later referred to a sports physician for individualized post-operative rehabilitation. By then, he had a 2 cm shortening of the affected limb, which required a customized shoe for correction of the limb length discrepancy. With the

customized shoe, he was able to progress his physical activities gradually, from brisk walking to slow jog then later running and cycling outdoors. Successive clinic visits showed remarkable improvement in physical fitness, sports participation and normalization of vitamin D levels. With guidance from a sports physician, he was able to resume sports activities eventually without limitation or difficulty. Repeated DXA scans within one year showed significant improvement.

#### CONCLUSION

Physical activity and vitamin D are important essentials in bone growth and bone health in adolescents.

### EP\_A046

#### A RARE CASE OF NONFUNCTIONING APPENDICEAL NEUROENDOCRINE TUMOUR (ANET) WITH BASE INVOLVEMENT NEEDING HEMICOLECTOMY

<https://doi.org/10.15605/jafes.038.S2.64>

Abdullah Shamshir Abd Mokti<sup>1</sup> and Raja Nurazni Raja Azwan<sup>2</sup>

<sup>1</sup>Endocrine Unit, Medical Department, Hospital Selayang, Malaysia

<sup>2</sup>Endocrine Unit, Medical Department, Hospital Tengku Ampuan Afzan, Kuantan, Malaysia

#### INTRODUCTION/BACKGROUND

Appendiceal neuroendocrine tumour (ANET) is the commonest appendiceal tumour found in 0.2–0.7% of surgical resections for suspected appendicitis. Peak incidence is at age 40–50 years with slight female preponderance. If diagnosed at a lower stage, survival is extremely good; local disease has 5-year survival rate (5-YSR) of between 95–100% and regional disease has between 85–100% 5-YSR. However, cases with distant metastasis present with relatively poor survival figures with 5-YSR less than 25%.

We report a rare case of a patient with ANET with involvement of the base of the appendix needing further anatomical and functional imaging and right hemicolectomy.

#### CASE

A 45-year-old female presented with acute right iliac fossa pain of less than 24 hours of duration with vomiting which led to a diagnosis of presumed appendicitis. She underwent laparoscopic appendectomy and intraoperatively was found to have adhesions with the abdominal wall and the appendix was only mildly inflamed. Histologic examination confirmed neuroendocrine tumour of the



appendix with base of appendix involvement. Contrast-enhanced CT showed suspicious nodule in both upper and lower lobes of the lungs. Gallium dotatate PET Scan showed no dotatate-avid lesions in the bowels, lymph nodes and lung metastases. Due to involvement of appendiceal base, a decision of hemicolectomy was made. Histopathology showed no evidence of tumour involvement in bowel.

#### CONCLUSION

Although ANETs are usually benign, non-functional and have good prognosis, it is important to identify features needing further anatomical and functional imaging which would determine whether right hemicolectomy is needed to prevent metastases or recurrence.

### EP\_A047

#### PEMBROLIZUMAB-INDUCED HYPOPHISITIS IN A PATIENT WITH UNDERLYING HYPOTHYROIDISM PRESENTING AS ADRENAL CRISIS: A CASE REPORT

<https://doi.org/10.15605/jafes.038.S2.65>

Abdullah Shamshir Abd Mokti<sup>1</sup> and Raja Nurazni Raja Azwan<sup>2</sup>

<sup>1</sup>Endocrine Unit, Medical Department, Hospital Selayang, Malaysia

<sup>2</sup>Endocrine Unit, Medical Department, Hospital Tengku Ampuan Afzan, Kuantan, Malaysia

#### INTRODUCTION/BACKGROUND

Pembrolizumab is a checkpoint inhibitor recently used to treat various types of malignancies. It is an analogue of programme-cell-death-1 (PD1) protein analogue involving immune T-cells and has been shown to cause immune-related adverse events including endocrinopathies. Most reports related to pembrolizumab were on thyroiditis.

We report a case of a patient presenting with adrenal crisis due to hypophysitis after after he was started on treatment with pembrolizumab.

#### CASE

A 73-year-old female with underlying hypothyroidism and hepatitis-B was diagnosed in 2019 with hepatocellular carcinoma stage C (T2N1M0). Post-lobectomy with lymph-node clearance, she was started on pembrolizumab and planned for 28 cycles. She presented to casualty department after the fourth cycle of chemotherapy with vomiting, diarrhoea, abdominal discomfort and reduced oral intake. There was no hypotension or hypoglycaemia but she had hyponatraemia (Na:125 mmol/l) with normokalaemia. She was treated with intravenous fluid and discharged after 2 days. However, she presented 5 days later with

hypotension, hypoglycaemia and severe hyponatraemia (Na: 117 mmol/l) and hyperkalaemia (K 5.8 mmol/l). She was diagnosed with an adrenal crisis and treated with intravenous hydrocortisone. Further hormonal workout revealed low serum cortisol (15 nmol/l) and undetectable ACTH due to hypophysitis. She made remarkable recovery and parenteral hydrocortisone was tapered and shifted to tablet.

#### CONCLUSION

High index of suspicion for hypophysitis and hormonal deficiencies in patients treated with pembrolizumab is vital to prevent delay in diagnosis of endocrine emergencies such as adrenal crisis. Furthermore, patients not previously diagnosed should be screened and periodically followed-up to detect hormonal deficiencies from treatment with immune checkpoint inhibitors.

### EP\_A048

#### HYPONATREMIA AND TSHoma: THE ODD COUPLE

<https://doi.org/10.15605/jafes.038.S2.66>

Quan Hziung Lim, Nicholas Ken Yong Hee, Ken Seng Chiew, Marisa Khatijah Borhan, Katherine Khor, Ee Wen Loh, Tharsini Sarvanandan, Sharmila Paramasivam, Lee Ling Lim, Jeyakantha Ratnasingam, Siew Pheng Chan, Shireene Ratna Vethakkan

Endocrinology Unit, Department of Medicine, Universiti Malaya Medical Centre, Kuala Lumpur, Malaysia

#### INTRODUCTION/BACKGROUND

We present a case of syndrome of inappropriate anti-diuresis (SIAD) as a rare presentation of TSH-secreting pituitary macroadenoma.

#### CASE

A 57-year-old postmenopausal female with no prior medical illness presented with recurrent admissions for symptomatic hyponatremia associated with abdominal pain and vomiting. She denied symptoms of hypothyroidism or hyperthyroidism. There was no history of medication intake. Family history was unremarkable. She was clinically euvolemic, and never exhibited clinical signs of hypo- or hyperthyroidism. There was no goitre.

Serial investigations showed hyponatremia (nadir of 114 mmol/L) and hypoosmolality (nadir of 257 mmol/kg), with elevated urine sodium (90-153 mmol/L) and urine osmolality (360-600 mmol/kg). Copeptin was elevated at 55.7 pmol/L (normal range: <13.1). Further investigations showed a persistently discordant thyroid function test



(TFT), with elevated free-T4 (range: 24.3-34.3 pmol/L) and non-suppressed thyroid stimulating hormone (TSH) (range: 1.19-4.07 mIU/L), similar across different laboratory platforms. Serum alpha-subunit of TSH was 0.6 IU/L, with TSH molar ratio of 3.1. Morning cortisol level was normal (598 nmol/L). Other pituitary hormones were appropriate for age and postmenopausal status. Whole body CT-scan was negative for malignancy, but incidentally showed a sellar mass. MRI confirmed a sellar mass measuring 1.1 x 2.1 x 2.1 cm, with suprasellar and cavernous extension, and chiasmal compression, with no features of apoplexy. Posterior pituitary T1 bright spot was present and displaced posteriorly.

Her hyponatremia improved with fluid restriction and rescue doses of tolvaptan. The sellar tumour was resected trans-sphenoidally. Histopathological examination confirmed a diagnosis of pituitary adenoma, which stained negative for ACTH, GH and PRL. TSH-staining was unavailable. Postoperatively, her TFT and sodium levels normalized.

#### CONCLUSION

Hyponatremia is a rare presentation for pituitary adenomas, especially in the absence of hypocortisolism or hypothyroidism. SIAD has been reported in non-functioning pituitary adenomas, pituitary apoplexy and central hypothyroidism and hypocortisolism. This is postulated to be due to exaggerated arginine-vasopressin (AVP) secretion due to local mass effect.

### EP\_A049

#### GIANT PITUITARY MACROADENOMA MASKED BY BILATERAL RETINAL DETACHMENT

<https://doi.org/10.15605/jafes.038.S2.67>

**Joel Xiang Loong Lee, Jen Hoong Oon, Noor Hafis Md Tob, Chin Voon Tong, Melissa Verghis, Siow Ping Lee**

*Hospital Melaka, Malaysia*

#### INTRODUCTION/BACKGROUND

Pituitary adenomas are benign tumours that encompass 10-20% of intracranial neoplasms. About 25-35% are clinically non-functioning pituitary adenomas (NFPA). Giant pituitary adenomas (diameter  $\geq 4$  cm) comprise approximately 5% of all pituitary tumours and usually present with mass effects on the neighbouring structures causing visual impairments, headaches and cranial nerve dysfunction. We present a case of giant pituitary macroadenoma with late presentation, being masked by bilateral retinal detachment.

#### CASE

A 39-year-old male with past history of bilateral retinal detachment following motor vehicle accident presented with progressive deteriorating vision for the past 3 years. This was initially attributed to retinal detachment/retinal scar. He then had frequent falls and headaches for the past 2 months. Cranial MRI showed a large pituitary adenoma measuring 6.3 x 5.7 x 5.9 cm with compression to the frontal and parietal lobes, optic chiasm and lateral ventricles bilaterally. He underwent two debulking surgeries. Post-surgery imaging showed minimal changes in tumour size. Histopathology examination showed pituitary adenoma with low ki67. Clinically and biochemically, he had panhypopituitarism with thyroid stimulating hormone (TSH), adrenocorticotrophic hormone (ACTH) and gonadotrophins insufficiency. He is now on thyroxine, hydrocortisone and testosterone replacement. A multidisciplinary team meeting discussion concluded that a third debulking surgery by a high-volume surgeon followed by radiotherapy is the best option for the patient.

#### CONCLUSION

This is a case of NFPA complicated by progressive visual impairment which was masked by bilateral retinal detachment. We highlight the difficulty of detecting NFPA early in this patient in view of his visual history.

### EP\_A050

#### RESOLUTION OF CYSTIC MACROPROLACTINOMA WITH DOPAMINE AGONIST THERAPY

<https://doi.org/10.15605/jafes.038.S2.68>

**Qing Ci Goh, Yee Wen Loh, Yong Siang Ng, Woh Wei Mak, Gayathri Devi Krishnan, Yoke Mui Ng, Shazatul Reza Mohd Redzuan, Subashini Rajoo, Mohamed Badrulnizam Long Bidin**

*Hospital Kuala Lumpur, Malaysia*

#### INTRODUCTION/BACKGROUND

Cystic prolactinomas are prolactinomas that harbor cystic regions, usually occupying  $\geq 50\%$  of the tumour volume. It is hypothesized that dopamine agonists are ineffective in reducing cystic tumour mass due to the absence of dopamine receptors in the cystic portion of the tumour. We present a case of a patient with a cystic prolactinoma for which the cyst disappears following treatment with dopamine agonist.

#### CASE

A 23-year-old Malay female first presented with secondary amenorrhoea. She attained menarche at 15 years of age and had regular menses since then until 2019. She is otherwise



well with no galactorrhoea, headache or visual deficit. The hormonal evaluation revealed hyperprolactinemia (11,131 mIU/L) and hypogonadotropic hypogonadism (estradiol: 64.9 pmol/L, FSH: 7.2 mIU/L). Magnetic resonance imaging (MRI) demonstrated a cystic lesion occupying the pituitary fossa and extending into the suprasellar region; likely Rathke's cleft cyst with possible concomitant presence of pituitary adenoma. The lesion is abutting the optic chiasm with a height of 15.8 mm. She was treated with cabergoline 0.5mg twice per week. Her prolactin level normalized 3 months later with the resumption of a normal menstrual cycle. However, she defaulted to subsequent follow-up for 1 year before presenting to the endocrine clinic again for galactorrhoea and irregular menstruation. Prolactin level was 2,861 mIU/L. Cabergoline was re-initiated at 0.5 mg twice per week and her symptoms resolved 6 months later with the prolactin level of 311 mIU/L. Repeat MRI showed a right pituitary gland lesion measuring 0.4 x 0.3 x 0.3 cm with no cystic lesion identified.

#### CONCLUSION

Initial management strategies for cystic prolactinomas have been debated. In a recent review of cystic prolactinoma patients, 80% with compression of the optic chiasm evident on MRI (mostly without visual field defect) at presentation achieved resolution of chiasm compression with medical treatment. This case highlighted the effectiveness of cabergoline in treating cystic prolactinomas.

### EP\_A051

#### ENDOSCOPIC ULTRASOUND-GUIDED RADIOFREQUENCY ABLATION USED IN THE TREATMENT OF INSULINOMA

<https://doi.org/10.15605/jafes.038.S2.69>

Wei Wei Ng,<sup>1</sup> Xe Hui Lee,<sup>1</sup> Anilah Abdul Rahim,<sup>2</sup> Ijaz Hallaj Rahmatullah<sup>2</sup>

<sup>1</sup>Hospital Pulau Pinang, Malaysia

<sup>2</sup>Hospital Raja Permaisuri Bainun, Ipoh, Malaysia

#### INTRODUCTION/BACKGROUND

Surgical excision used to be the mainstay of curative treatment for insulinoma. In recent years, endoscopic ultrasound-guided radiofrequency ablation (EUS-guided RFA) has been used as a curative technique for insulinoma. Here, we report 2 cases of insulinoma with solitary lesions which showed clinical improvement following treatment with EUS-guided RFA.

#### CASE

The first case involved a 43-year-old Malay male, non-diabetic, who came with reduced consciousness during the fasting month of Ramadan. A low random blood sugar

of 1.4 mmol/L was accompanied by elevated insulin (8.3 mIU/L) and C-peptide (427 pmol/L). Contrast-enhanced CT showed a pancreatic lesion in the body measuring 1.4 x 1.6 cm. EUS confirmed the presence of a 1.5 cm hypoechoic lesion at the same location. He underwent 3 cycles of EUS-guided RFA without any complications. After the second cycle of RFA, diazoxide was discontinued and there was no recurrence of hypoglycaemia.

The second case involved a 59-year-old male who presented with recurrent episodes of giddiness and sweating for the past 1 year. Each episode resolved with food intake. A 72-hour prolonged fast revealed hyperinsulinaemic hypoglycaemia (RBS 2.3 mmol/L, elevated insulin 1064 pmol/L and elevated C-peptide 94.7 pmol/L). Insulin autoantibody was negative. Initial imaging with contrast-enhanced CT and <sup>68</sup>Gallium-DOTATATE scan failed to localize any pancreatic lesion. However, subsequent EUS detected a lesion at the pancreatic neck measuring 1.0 x 1.2 cm. Fine needle aspiration reported a pancreatic neuroendocrine tumour with positive staining for chromogranin and synaptophysin. He underwent 3 cycles of EUS-guided RFA without complications. His hypoglycaemia symptoms resolved after the 3<sup>rd</sup> cycle of RFA.

#### CONCLUSION

EUS-guided RFA can be a potential consideration in treating insulinoma with solitary lesions <2 cm with no evidence of metastasis. It is minimally invasive with low periprocedural complication risk. Longer follow-up is needed in both patients to assess long-term clinical effectiveness and recurrence.

### EP\_A052

#### SUCCESSFUL RESOLUTION OF THYROID STORM FROM TSHoma WITH SOMATOSTATIN RECEPTOR LIGAND

<https://doi.org/10.15605/jafes.038.S2.70>

Ken Seng Chiew, Quan Hziung Lim, Nicholas Ken Yoong Hee, Sharmila Paramasivam, Lee Ling Lim, Shireene Vethakkan, Jeyakantha Ratnasingam  
*Endocrine Unit, Department of Medicine, University Malaya, Malaysia*

#### INTRODUCTION/BACKGROUND

Thyroid-stimulating hormone (TSH)-secreting pituitary adenomas (TSHomas) account for 2% of all pituitary adenomas. Symptoms of hyperthyroidism are common but thyroid storm is extremely rare. We report a case of TSHoma complicated by thyroid storm that was managed with somatostatin-receptor-ligand (SRL).



## CASE

A 76-year-old male with TSHoma measuring 15 mm x 15 mm x 14 mm was conservatively managed for 5 years with cabergoline as he refused surgery. He presented early this year with fever, atrial fibrillation with rapid ventricular response and pneumonia requiring non-invasive ventilation. Burch-Wartofsky score was 60, consistent with thyroid storm. His fT4 and fT3 were 69.8 pmol/L (11.5-22.7 pmol/L) and 21.7 pmol/L (3.5-6.5 pmol/L) respectively. TSH was inappropriately normal at 3.74 mIU/L (0.55-4.78 mIU/L). In intensive care, intravenous octreotide infusion at 50 mcg/hour was commenced. After 48 hours, fT4, fT3 and TSH reduced to 46 pmol/L, 6.8 pmol/L and 0.52 mIU/L, respectively. Intravenous octreotide was converted to subcutaneous short-acting octreotide, titrated up to 100 mcg TDS. Glucocorticoids, carbimazole and betablockers were also used. After 5 days, his fT4, fT3 and TSH markedly reduced to 18.7 pmol/L, 4.2 pmol/L and 0.32 mIU/L, respectively. He was then overlapped with subcutaneous long-acting lanreotide. Repeat imaging showed unchanged size and extent of the macroadenoma. Despite re-counselling for surgery, he opted for long-term lanreotide and remains controlled to date.

Only three cases of TSHoma complicated by thyroid storm have been reported. In all cases, thyroid storm occurred after transsphenoidal surgery. Thionamides and betablockers were the mainstay of therapy. To our knowledge, our case is the first to use intravenous octreotide infusion in the acute management of thyroid storm. As TSHomas express somatostatin receptors (SSTR), especially SSTR 2 and SSTR 5, SRLs target these receptors to reduce TSH secretion.

## CONCLUSION

Thyroid storm is an extremely rare complication of TSHoma. In this case, the use of short-acting SRL in conjunction with short-term antithyroid drugs, glucocorticoids and betablockers were efficacious in the acute management of this emergency.

## EP\_A053

### PITUITARY METASTASIS: A RARE PRESENTATION OF SMALL CELL LUNG CANCER

<https://doi.org/10.15605/jafes.038.S2.71>

**Meng Loong Mok,<sup>1</sup> Shu Teng Chai,<sup>1</sup> Vivithirah K. Arjunan Roy,<sup>1</sup> Norsarah Shamsudin<sup>2</sup>**

<sup>1</sup>Endocrine Unit, Department of Medicine, Hospital Sultanah Aminah, Johor Bahru, Johor, Malaysia

<sup>2</sup>Department of Radiology, Hospital Sultanah Aminah, Johor Bahru, Johor, Malaysia

## INTRODUCTION/BACKGROUND

The pituitary gland is a rare site for metastasis, with breast and lung cancers being the most common primary malignancies implicated in such instance. Most pituitary metastasis are clinically silent and diagnosed incidentally during radiological evaluation of brain metastasis.

## CASE

We describe an elderly male, who had advanced small cell lung carcinoma diagnosed after his initial presentation of left cerebellar and pituitary metastatic lesions.

A 77-year-old ex-smoker complained of headache and vomiting for six months. Brain MRI showed a left cerebellar cystic lesion (3.9 x 4.6 x 3.3 cm) with mass effect. Additionally, a lobulated pituitary mass with posterior pituitary involvement and suprasellar extension was seen (1.3 x 1.3 x 1.0 cm and 1.2 x 1.4 x 1.0 cm for sellar and suprasellar components respectively). Following excision of the left cerebellar lesion, the patient was discharged. Ten days later, he was readmitted for hospital-acquired infection with transient hypotension. Stress dose of hydrocortisone was commenced for a low morning cortisol of 81.8 nmol/L. Both subnormal TSH (0.047 mIU/L; Normal: 0.35 – 4.94) and free T4 (8.59 pmol/L; Normal: 9.01 – 19.05) were attributed to sick euthyroidism. Prolactin was slightly elevated. There was no diabetes insipidus. A right upper lobe lung mass with mediastinal and right hilar lymphadenopathy were evident from contrast-enhanced CT thorax, abdomen, and pelvis. Endoscopic ultrasound guided fine-needle biopsy of aortopulmonary node was performed. Histopathological examinations of both specimens (aortopulmonary node and cerebellar mass) were consistent with small cell lung carcinoma. He subsequently underwent whole brain radiotherapy. Unfortunately, he passed away during the treatment course.

## CONCLUSION

Pituitary metastasis is rare and exhibits a predilection for the posterior pituitary. Clinical manifestations of pituitary metastasis, if present, include visual field defects, cranial



diabetes insipidus, anterior pituitary hormone deficiency, and headache. Its presence should be suspected when a pituitary tumour involves the posterior pituitary, especially in an elderly patient.

## EP\_A054

### METYRAPONE AS A BRIDGING THERAPY IN FLORID CUSHING'S DISEASE PATIENT PRIOR TO PITUITARY ADENOMECTOMY

<https://doi.org/10.15605/jafes.038.S2.72>

**Muhamad Shafiq MY, Siti Sanaa WA, Masliza Hanuni MA, Nur Hidayah MM**

*Endocrinology Division, Medical Department, Hospital Sultanah Nur Zahirah, Kuala Terengganu, Malaysia*

#### INTRODUCTION/BACKGROUND

Florid Cushing's disease gives rise to high morbidity and mortality due to its metabolic abnormalities and the risk of infection. Preoperative medical therapy with steroidogenesis inhibitors such as metyrapone, an 11 $\beta$ -hydroxylase inhibitor, may be considered if surgery is delayed or rapid reduction of cortisol is needed in patients with severe Cushing's who have potentially life-threatening metabolic, infectious or thromboembolic cardiovascular complications.

#### CASE

We describe a 31-year-old female who presented with lethargy and a short history of body acne, proximal muscle weakness, and hair loss for a month. She had missed her menses for two months. Upon examination, she was hypertensive (BP 190/112 mmHg), BMI was 26 kg/m<sup>2</sup>. She had hirsutism, hyperpigmentation over her lips, knuckles, and nail folds, facial and body acnes, alopecia, proximal muscle weakness, acanthosis nigricans, dorsocervical and supraclavicular fat pads and purplish striae over her abdomen.

Initial blood results revealed severe hypokalaemia (1.9 mmol/l), metabolic alkalosis (HCO<sub>3</sub> 41.3 mmol/l), HbA1c 9.2% and transaminitis (ALT 324 U/L, AST 130 U/L) which precludes initiation of ketoconazole. ODST was not suppressed with a cortisol level of 1406 nmol/l, and HDDST showed 50% reduction of cortisol from baseline (baseline 1059 nmol/l, post 530 nmol/l). 24-hour urine cortisol was markedly elevated at 10,352 nmol/day. ACTH level was raised at 38.4 pmol/L. Pituitary MRI demonstrated a bulky left pituitary gland measuring 0.6 cm x 0.7 cm x 0.4 cm. CT TAP showed no evidence of a suspicious lesion/mass suggestive of ectopic Cushing's. She initially required high doses of basal-bolus insulin and potassium replacement together with four antihypertensives. We

commenced her on Metyrapone 250 mg TDS and this was titrated to 500 mg TDS based on serial cortisol levels. We attained a cortisol level of 531 nmol/l with better control of her blood pressure and glucose level prior to pituitary adenomectomy with TSS.

#### CONCLUSION

This case illustrates the effectiveness of metyrapone in achieving normal biochemical clinical parameters pre-operatively before undergoing pituitary surgery.

## EP\_A055

### UNCOMMON CAUSE OF SECONDARY EMPTY SELLA SYNDROME

<https://doi.org/10.15605/jafes.038.S2.73>

**Sharifah Noor Adrilla Long Mohd Noor Affendi, Mohd Sofi Hafizi Sarip @ Ma'arof, Noor Lita Adam, Nor Afidah Karim**

*Endocrine Unit, Department of Medicine, Hospital Tuanku Jaafar, Seremban, Malaysia*

#### INTRODUCTION/BACKGROUND

The severe acute respiratory syndrome coronavirus 2 (SARS-CoV-2) pandemic has led to detrimental outcomes worldwide, leading to millions of deaths. SARS-CoV-2 vaccines are a critical step for many countries in battling with this infection. Recently, there are increasing cases of endocrinopathy, including hypophysitis, associated with SARS-CoV-2 vaccination.

#### CASE

We describe a patient with hypophysitis as a sequelae of COVID-19 vaccination.

A 48-year-old male, with a history of pulmonary tuberculosis who completed treatment in 2016, presented with fever, chills, postural hypotension and left upper limb weakness. The symptoms appeared 2 weeks after his 1<sup>st</sup> dose of SARS-CoV-2 vaccination.

He was initially treated as acute disseminated encephalomyelitis (ADEM) and meningoencephalitis. During admission, he developed septic shock with multiorgan involvement. He remained hypotensive despite improvement of septic parameters. Hence, short synacthen test was done which revealed inadequate cortisol response.

Inpatient cerebrospinal fluid (CSF) investigations were normal. Cranial MRI showed asymmetrical white matter hyperdensities; possible aetiology included infectious and inflammatory causes. He was discharged well with oral hydrocortisone 10 mg bd.



Evaluation in an endocrine clinic showed that he had low cortisol with low ACTH levels. Moreover, insulin tolerance test done confirms inadequate ACTH and growth hormone response. Other anterior hormonal profile results were normal. In view of the evidence of hypothalamic-pituitary-adrenal (HPA) axis suppression, coupled with the pituitary MRI findings, the diagnosis of SARS-CoV-2 vaccination-induced hypophysitis was established.

#### CONCLUSION

SARS-CoV-2 vaccination-induced hypophysitis is a rare but significant adverse effect that needs to be recognised. Prompt diagnosis is crucial, as treatment with steroid is lifesaving. In light of our experience, diagnosis of hypophysitis should be considered when patients present with pituitary dysfunction with a history of recent COVID-19 vaccination.

### EP\_A056

#### USTEKINUMAB-INDUCED HYPOPHYSITIS IN CROHN'S DISEASE: A CASE REPORT

<https://doi.org/10.15605/jafes.038.S2.74>

**Tharsini Sarvanandan, Ken Seng Chiew, Shireene Vethakkan, R. Jeyakantha Ratnasingam, Lee-Ling Lim, Quan Hziung Lim, Nicholas Ken Yoong Hee, Sharmila Paramasivam**

*Unit of Endocrinology, Department of Medicine, University Malaya Medical Centre, Malaysia*

#### INTRODUCTION/BACKGROUND

Ustekinumab is a monoclonal antibody targeting IL-2 and IL-23 that has been used to treat psoriasis and more recently, inflammatory bowel disease. With the increased use of immunotherapy, immune-related adverse events are being reported more frequently. Ustekinumab has been reported to cause hypophysitis in a patient with psoriasis.

#### CASE

We report a case of a 29-year-old female with difficult-to-treat Crohn's disease since 2008. She has received azathioprine, methotrexate, infliximab, and adalimumab without favorable response. She subsequently underwent a right hemicolectomy and terminal ileal resection in 2017. She had previously been on prednisolone in 2012. She was started on ustekinumab in May 2020 and showed good clinical response. Twenty-seven months after starting ustekinumab, on routine investigation, she had a fasting blood glucose of 1.9 mmol/L. There were also some home capillary glucose readings of <3.5 mmol/L. She reported no signs of hypoglycemia and denied taking other medications or traditional supplements. She had been off all steroids for more than 10 years. She was clinically euthyroid with

no history of polyuria or visual field defects. She had transient oligomenorrhea due to significant weight loss in 2020. Her BMI was 16.2. She had no signs of Cushing's. Further workup revealed low cortisol level of 43 nmol/L with ACTH of 11 pg/ml. TFT was discordant with elevated FT4 of 34 pmol/L and normal TSH of 2.69 mIU/L, with no assay interference confirmed. Her prolactin level was normal at 374 mIU/L. Pituitary MRI showed loss of posterior pituitary bright spot, slightly thickened stalk with heterogeneity within the pituitary suggesting possible hypophysitis. She started hydrocortisone replacement and her hypoglycemia resolved. As she is currently responding well to the ustekinumab for her Crohn's, she will be monitored periodically for progression of her hypophysitis.

#### CONCLUSION

Patients treated with ustekinumab should be monitored periodically for autoimmune endocrinopathies such as hypophysitis and thyroiditis.

### EP\_A057

#### A RARE CASE OF MICROPROLACTINOMA AND GRANULOMATOUS MASTITIS

<https://doi.org/10.15605/jafes.038.S2.75>

**Kai Xuan Teh,<sup>1</sup> Joon Hi Tham,<sup>2</sup> Ann Feng Pan,<sup>2</sup> Hwee Ching Tee,<sup>1</sup> Jin Hui Ho<sup>1</sup>**

*<sup>1</sup>Endocrinology Unit, Department of Internal Medicine, Hospital Queen Elizabeth II, Kota Kinabalu, Sabah, Malaysia*

*<sup>2</sup>Department of Pathology, Hospital Queen Elizabeth, Kota Kinabalu, Sabah, Malaysia*

#### INTRODUCTION/BACKGROUND

Idiopathic granulomatous mastitis (IGM) is a benign and rare chronic inflammatory disease of the breast. However, its clinical presentation can mimic a breast malignancy or abscess. The aetiology is often unknown but several predisposing factors were identified, including patients with autoimmune disorders, hyperprolactinemia secondary to pregnancy, lactation, dopamine antagonist usage or pituitary adenoma.

#### CASE

We report a rare case of IGM in a patient with hyperprolactinemia secondary to microprolactinoma.

A 45-year-old, para 2, premenopausal female presented to a surgical clinic with a 2-year history of intermittent bilateral galactorrhoea and right breast swelling with pus discharge. There was no menstrual irregularity. Ultrasound of the right breast demonstrated multiloculated hypoechoic collections with internal echogenicities. She was treated with antibiotics; however, there was no clinical



improvement, and she underwent biopsy of the lesion which revealed chronic granulomatous inflammation, confirming the diagnosis of IGM. She was also found to have hyperprolactinemia at 125.9 ng/ml secondary to a microprolactinoma and was started on cabergoline. Two weeks post treatment, the prolactin level normalized with resolution of galactorrhoea.

#### CONCLUSION

Hyperprolactinemia is one of the predisposing factors for the development of IGM by increasing inflammation of the breast tissue. When evaluating for IGM, serum prolactin should always be measured to exclude elevated prolactin levels. The cause of hyperprolactinemia should be further investigated and addressed, and treatment with dopamine receptor agonist could reduce recurrence of IGM.

### EP\_A058

#### FASTING AND POSTPRANDIAL HYPOGLYCEMIA IN AN ADOLESCENT PRESENTING WITH ENDOGENOUS HYPERINSULINEMIC HYPOGLYCEMIA LIKELY INSULINOMA: A CASE REPORT

<https://doi.org/10.15605/jafes.038.S2.76>

**Nashriq Khan Adam Khan and Noor Rafhati Adyani Abdullah**

*Endocrinology Unit, Department of Internal Medicine, Hospital Sultanah Bahiyah, Kedah, Malaysia*

#### INTRODUCTION/BACKGROUND

Hypoglycaemia is an uncommon clinical problem in individuals without diabetes mellitus. It is a clinical syndrome with various causes in which low plasma glucose leads to hypoglycaemic symptoms and signs that resolve when the plasma glucose is raised. The diagnosis of a true hypoglycaemic disorder requires fulfilment of these specific criteria (Whipple's triad). Once the presence of a hypoglycaemic disorder is verified, a detailed clinical history often suggests a specific underlying cause. Insulinoma is a type of functional neuroendocrine tumour characterized by hypersecretion of insulin, causing hypoglycaemia, characteristically fasting hypoglycaemia. We describe a patient with insulinoma with both fasting and postprandial hypoglycaemia.

#### CASE

A pre-morbidly healthy 12-year-old male presented with recurrent hypoglycaemia for 3 months. He experienced a severe episode of hypoglycaemia manifesting as seizure with blood glucose of 1.4 mmol/L. Symptoms resolved after glucose administration. He developed progressive weight gain over the course of 4 years. His

BP was 120/72, PR 98, BMI 30 with absence of acanthosis nigricans. Blood investigation during clinic visit revealed asymptomatic hypoglycaemia mediated by endogenous hyperinsulinemia, with random blood glucose of 1.7 mmol/L (<3 mmol/L), serum insulin 364.8 pmol/L (>20 pmol/L) and C-peptide 1495 pmol/L (>200 pmol/L). Mixed meal test confirmed fasting hypoglycaemia, with RBS of 2.5 mmol/L, insulin 300 pmol/L, C-peptide of 1145 pmol/L. At 120 minutes (postprandial) following the test, RBS was 2.3 mmol/L, insulin 557 pmol/L, C-Peptide 2282 pmol/L. Prolonged supervised fasting test revealed hypoglycaemia after 4 hours with RBS 2 mmol/L, insulin 286.8 pmol/L and C-peptide 1459 pmol/L. Beta-Hydroxybutyrate remained suppressed at 0.1 mmol/L following fasting. Sulphonylureas screening was negative. HbA1c was 4.2% and serum Ca (corrected) was 2.22 mmol. CT pancreatic protocol revealed a hypervascular lesion (1.9 x 2.0 x 2.9cm) at the pancreatic head. Diazoxide was initiated to prevent hypoglycaemia and it was well tolerated. The patient is planned for surgical resection of the pancreatic lesion which is likely to be an insulinoma.

#### CONCLUSION

Recurrent hypoglycaemia requires careful and comprehensive assessment to diagnose a patient. Around 20% of insulinoma patients have both fasting and postprandial hypoglycaemia needing clinical suspicion and prompt assessment to improve outcomes for these patients.

### EP\_A059

#### LONG-STANDING ACROMEGALY WITH PERSISTENT DISEASE RESPONSIVE TO PASIREOTIDE: A CASE REPORT

<https://doi.org/10.15605/jafes.038.S2.77>

**Eileen Tan,<sup>1</sup> Chee Keong See,<sup>1</sup> Saiful Shahrizal Shudim,<sup>1</sup> Ilham Ismail,<sup>1</sup> Nurbadriah Jasmiad,<sup>1</sup> Zhe Lan Wong,<sup>1</sup> Subashini Rajoo,<sup>2</sup> Mohamad Badrulnizam Long Bidin,<sup>2</sup> Xin-Yi Ooi<sup>2</sup>**

<sup>1</sup>Hospital Sultan Haji Ahmad Shah Temerloh, Malaysia

<sup>2</sup>Hospital Kuala Lumpur, Malaysia

#### INTRODUCTION/BACKGROUND

In acromegaly patients, chronic hypersecretion of growth hormone from pituitary adenoma results in significant morbidity and mortality. Achieving biochemical control can be challenging, requiring a combination of pituitary surgery, radiotherapy and medical therapy. Pasireotide, a new multireceptor-targeted somatostatin receptor ligand, has a broader binding profile and an increased affinity for SSTR1, 2, 3, and 5 that has demonstrated superiority compared to Octreotide LAR.



## CASE

We report a case of long-standing acromegaly with persistent disease despite pituitary surgery, radiotherapy and Octreotide LAR treatment being switched to pasireotide treatment.

A 63-year-old female was diagnosed with acromegaly 12 years ago with an initial pituitary tumour size of 2.6 x 2.7 x 3.8 cm. She underwent initial transsphenoidal resection of the pituitary tumour but post-operatively she still had a residual tumour of 1.0 x 0.9 x 1.4cm. She received initial medical therapy (Octreotide LAR). However, due to persistent disease and residual tumour, she was then subjected to 11 cycles of radiotherapy. Despite radiotherapy, her serum IGF-1 levels remained elevated and she also developed uncontrolled diabetes. At this juncture, she also refused further pituitary surgery and refused an MRI scan due to claustrophobia. Over the next few years, she would be maintained on Octreotide LAR 40 mg. Her IGF-1 levels would fluctuate slightly but never achieved control. Pasireotide treatment was subsequently started for the patient 1 year ago. After initiation of pasireotide, she had shown significant improvement of serum IGF-1 levels from 628.5 ng/ml to 203.4 ng/ml after 4 months of treatment. She also finally agreed to a repeat MRI pituitary which showed minimal residual tumour.

## CONCLUSION

This case demonstrated the difficulty in achieving remission in an acromegaly patient despite surgery and radiotherapy. Despite long standing acromegaly disease and long duration of Octreotide LAR treatment, initiation of pasireotide has benefit to bring patient into biochemical and symptom control.

## EP\_A060

### ATYPICAL PRESENTATION OF FUNCTIONING MALIGNANT METASTATIC PARAGANGLIOMA WITH RECURRENT MYASTHENIA CRISIS

<https://doi.org/10.15605/jafes.038.S2.78>

**Nur Hidayah MM,<sup>1</sup> Masliza Hanuni MA,<sup>1</sup> Siti Sanaa WA,<sup>1</sup> Khairul Azmi,<sup>2</sup> Hadzfadzila MU,<sup>2</sup> Mohd Noor I<sup>2</sup>**

<sup>1</sup>Endocrine Unit, Hospital Sultanah Nur Zahirah, Terengganu, Malaysia

<sup>2</sup>Neuromedical Unit, Hospital Sultanah Nur Zahirah, Terengganu, Malaysia

## INTRODUCTION/BACKGROUND

The crude prevalence of paraganglioma is 2 per 100,000 persons/year. Roughly 10% of paragangliomas are malignant, resulting in a rare occurrence of 90-95 cases per 400 million people. The usual symptom of paraganglioma is related to catecholamine hypersecretion. However, we report an intra-abdominal paraganglioma presenting as recurrent myasthenia crisis without symptoms of catecholamine hypersecretion.

## CASE

We report a case of a 34-year-old female who presented with abdominal pain. On work-up, CT scan revealed a 20-cm intraabdominal mass. Inguinal lymph nodes biopsy revealed reactive tissue. She was then lost to follow-up. She had recurrent admission for myasthenia crisis after 6 months of initial presentation. She received regular plasma exchange during the crisis to which she responded well. Further work-up of the abdominal mass revealed a functioning abdominal paraganglioma. Throughout her hospitalization, patient was normotensive with no symptoms to suggest paroxysm.

CT of the thorax-abdomen-pelvis revealed a 27-cm intra-abdominal multilobulated mass encasing major abdominal vessels and causing mass effect to adjacent organs. There was also compression fracture with lytic lesions of L3 and L4 vertebra. No mediastinal mass was seen. 24-hr urine metanephrines (umol/day): normetanephrine 21.9 (0.0-2.13), metanephrine 200.0 (0.0-1.62), 3-methoxytyramine 251.40 (0.10-1.79). Cervical lymph nodes tissue-biopsy revealed histological features and immunohistochemistry staining in favour of paraganglioma with necrosis and high mitotic figures.

A multi-disciplinary-team discussion was done with surgical, oncology and radio-nuclear for direction of therapy. Unfortunately, debulking surgery was not feasible



in view of the large functioning mass encasing major vessels. Chemo- and radio-nuclear therapy is not suitable in view of baseline ECOG-4. Decision for best supportive care was made with family members.

#### CONCLUSION

Due to its low prevalence, there is a low index of suspicion when it comes to diagnosing paraganglioma. Adding atypical presentation to this, this may lead to delay diagnosis and treatment. Early diagnosis is utmost important in a case of malignant paraganglioma since the treatment is by surgical removal.

### EP\_A061

#### APOPLEXY IN MICROPROLACTINOMA

<https://doi.org/10.15605/jafes.038.S2.79>

**Zhe Lan Wong, Eileen Tan, Ilham Ismail, Nurbadriah Jasmiad, Chee Keong See, Saiful Shahrizal Shudim**  
*Hospital Sultan Haji Ahmad Shah, Temerloh, Malaysia*

#### INTRODUCTION/BACKGROUND

Pituitary adenoma apoplexy is uncommon and often occurs spontaneously as a result of infarction, haemorrhage or a combination of both. Pituitary apoplexy is potentially life threatening and has long term consequences resulting in permanent hormonal deficiencies. It is often associated with pituitary macroadenoma and occurrence with pituitary microadenoma is rare.

#### CASE

We report a case of micro-prolactinoma with pituitary apoplexy on follow-up pituitary MRI.

A 29-year-old female who presented with secondary oligomenorrhea in December 2021 was subsequently diagnosed with micro-prolactinoma. Cabergoline therapy was initiated promptly. However, her serial prolactin level while on treatment would fluctuate between normal range and up to three times the upper limit. During her initial few months of treatment, she would develop intermittent headache which subsequently subsided. A repeat pituitary MRI was initially planned due to this complaint to exclude pituitary apoplexy, but MRI was postponed due to patient's claustrophobia. The repeat pituitary MRI was only performed in early 2023 revealing the presence of pituitary apoplexy with intratumoral haemorrhage. At the same time, she would also be diagnosed with hypocortisolism and hypothyroidism. Hydrocortisone and thyroxine replacement therapy were initiated and cabergoline therapy was stopped. During her follow-up she did not exhibit overt symptoms of hypocortisolism, hypothyroidism, or visual field defects.

#### CONCLUSION

This case illustrated that pituitary apoplexy could present in pituitary microadenoma and may present with subtle symptoms. Without a high index of suspicion, pituitary apoplexy can be overlooked leading to delay or missing diagnosis. Pituitary apoplexy requires prompt diagnosis with imaging and treatment can improve the clinical outcomes of patients.

### EP\_A062

#### A RARE CASE OF TOTAL LEFT ANTERIOR CIRCULATION INFARCT (TACI) SECONDARY TO THYROTROPINOMA (TSHoma) TREATED WITH OCTREOTIDE MEDICAL THERAPY

<https://doi.org/10.15605/jafes.038.S2.80>

**Yi Jiang Chua, Choon Peng Sun, Zanariah Hussein**  
*Division of Endocrinology, Department of Internal Medicine, Hospital Putrajaya, Putrajaya, Malaysia*

#### INTRODUCTION/BACKGROUND

TSHoma is a rare cause of functioning pituitary adenoma. Patients with TSHoma have a biochemical derangement of elevated free thyroid hormones with unsuppressed TSH. They are usually misdiagnosed and treated for primary hyperthyroidism at the initial diagnosis. Most common symptoms upon presentations are hyperthyroidism, goitre and visual field defects. We reported an asymptomatic middle-aged female who presented acutely with left TACI secondary to atrial fibrillation due to a large functioning TSHoma.

#### CASE

A 53-year-old female, with no known medical diseases, presented with sudden-onset aphasia and right-sided body weakness. She presented to the emergency department with hypertension and tachycardia and ECG showed fast atrial fibrillation. Thyroid function test (TFT) showed that patient had a discordant hyperthyroid result [FT4 51.1 pmol/L (reference range 7.9-14.4) and TSH 4.825 mU/L (reference range 0.34-5.60)]. Repeated TFT on another platform had similar results. MRI of the brain revealed a heterogeneous mass occupying the sellar region with suprasellar extension 1.8 x 2.6 x 3.7 cm (AP x W x CC). TRH stimulation testing confirmed a functioning TSHoma and the patient was started on IM Octreotide LAR with rapid improvement of the TFT and resolution of the atrial fibrillation within 2 months. As this patient was not fit for surgical operation during the acute presentation, she was treated with medical therapy of Octreotide LAR and the patient achieved good improvement in 6 months' time where she was able to function independently. A repeat MRI after 6 months showed a smaller sellar mass (1.6 x 2.3 x 3.5 cm).



## CONCLUSION

TSHoma with acute stroke as an initial manifestation is uncommon. Interpretation of discordant TFT needs to be done and investigated carefully as TSHoma can be cured by surgical removal. In inoperable cases, medical therapy can control the disease well.

## EP\_A063

### A CASE OF GIANT INVASIVE MACROPROLACTINOMA PRESENTING AS A NASOPHARYNGEAL MASS

<https://doi.org/10.15605/jafes.038.S2.81>

**Li Sin Yeh, Chan Pei Lin, Florence Tan Hui Sieng**

*Endocrinology Unit, Medical Department, Sarawak General Hospital, Malaysia*

#### INTRODUCTION/BACKGROUND

Giant prolactinomas are rare and can invade the surrounding structure. Invasion tends to involve the suprasellar and cavernous sinus region with a minority invading the base of the skull.

#### CASE

We describe a rare presentation of giant invasive prolactinoma masquerading as nasopharyngeal tumour.

A 33-year-old female presented to the ENT clinic with nasal congestion, blocked ear, progressive right-sided hearing loss for 4 months and epistaxis and headache for 2 weeks. Nasopharyngeal scope showed a large mass protruding from the nasopharynx into the nasal cavity. Biopsy taken reported a neuroendocrine tumour with diffusely positive immunohistochemistry for synaptophysin, chromogranin and vimentin. Ki67 was 10%. MRI of the brain showed a large nasopharyngeal mass (7.1 x 9.8 x 6.3 cm) with complete obliteration of the nasopharynx and erosion of the sphenoid bone and clivus. There was also extensive multidirectional invasion of the surrounding tissue. The patient was referred to the neurosurgery and oncology team. Further history found that the patient had oligomenorrhoea for many years and became amenorrhoeic past 2 years. She denied galactorrhoea. Visual field testing showed left inferior quadrantanopia. Prolactin level was 625,740 uIU/mL. She was then referred to our endocrine service. Thyroid function and 8 am cortisol were normal. Further histopathology staining showed positivity for prolactin and ACTH. She was initiated on cabergoline 0.5 mg 3x/week. She developed a CSF leak after 2 weeks; after tumour debulking and leak repair, cabergoline dose was titrated to 0.5 mg daily. Prolactin reduced to 160727 uIU/mL and the tumour size decreased to 6.0 x 8.3 x 6.0 cm. Multidisciplinary team discussion decided on a trial of higher dose cabergoline (5.5

mg/week) prior to consideration for radiotherapy; however, the patient developed another CSF leak 1 month after dose titration, requiring another repair.

## CONCLUSION

Invasive giant prolactinoma may rarely present with skull base invasion and intranasal extension masquerading as nasopharyngeal tumor. Careful clinical evaluation is important to diagnose this rare presentation to allow timely and appropriate management.

## EP\_A064

### TSHoma: A CASE OF MISTAKEN IDENTITY

<https://doi.org/10.15605/jafes.038.S2.82>

**Chong Li Ren Albert, Chan Pei Lin, Florence Tan Hui Sieng**

*Endocrinology Unit, Medical Department, Sarawak General Hospital, Malaysia*

#### INTRODUCTION/BACKGROUND

TSH-secreting pituitary tumours are rare causes of hyperthyroidism. Its diagnosis is often delayed due to its uncommon presentation.

#### CASE

We report a case of TSHoma in a female initially misdiagnosed as Graves' disease.

A 36-year-old female was diagnosed with Graves' disease by a general practitioner since 2016 following symptoms of palpitations and weight loss. There was no family history of thyroid disease. She was treated with carbimazole for 6 years before receiving radioactive iodine 15 mCi in May 2022. However, 5 months post RAI, her FT4 remained elevated, ranging from 34.1- 39.1 pmol/L (Normal: 12.3-20.2 pmol/L) with high TSH of 7.12-10.1 mIU/L (Normal: 0.3-3.94 mIU/L). She was restarted on carbimazole and referred to the endocrine unit. On retrospective review, prior to RAI, she had raised FT4 and TSH levels as well. She also reported intermittent headaches for ten years but no visual disturbances and menstrual irregularities. She was clinically euthyroid. Pulse rate was 70/min and regular without beta blocker. She had a small diffuse goitre but no thyroid eye signs, visual field was normal. Thyroid ultrasound showed diffuse thyroid gland enlargement. Additional testing showed no feature of assay interference. Sex-hormone binding globulin was elevated at 190 nmol/L (Normal: 30-90). Prolactin and cortisol were within normal range. MRI of the brain showed a heterogenous sellar-suprasellar mass measuring 2.0 x 2.5 x 2.4 cm. Six months post RAI she had normal FT4 and FT3 on carbimazole 5 mg daily, but TSH was elevated at 65.2 mIU/L. Carbimazole was



discontinued and she was scheduled for transsphenoidal surgery.

#### CONCLUSION

In patients with discordant thyroid function results, the possibility of TSHoma should be considered after excluding assay interference and thyroid hormone resistance. Failure to recognize central hyperthyroidism (high FT4 with inappropriately normal or high TSH) can lead to delayed or inappropriate treatment such as RAI ablation with risk of tumour expansion.

## EP\_A065

### PITUITARY MACROADENOMA MIMICRY: A CASE REPORT

<https://doi.org/10.15605/jafes.038.S2.83>

**Nurqystina AS and Syahrizan S**

*Endocrine Unit, Hospital Sultan Idris Shah, Serdang, Malaysia*

#### INTRODUCTION/BACKGROUND

Nasal polyps causing compression to the pituitary fossa, increased intracranial pressure and ocular nerve palsies are rare. A prompt investigation to exclude pituitary insufficiency is mandatory to prevent a debilitating outcome.

#### CASE

Initial pituitary hormone panels demonstrated eipituitarism: morning cortisol 462 nmol/L (NR 102–535 nmol/L), FSH 4.25 IU/ml (NR 3.5–12.5 IU/ml), LH 2.75 mu/ml (2.4–12.6 IU/ml), free T4 11.24 pmol/L (NR 9–19 pmol/L), TSH 1.42 uIU/ml (NR 0.35–4.9 uIU/ml), and prolactin 306 mU/L (NR 102–535 mU/L). However, prior to surgery, she developed secondary hypothyroidism; free T4 9 pmol/L, TSH 3.69 uIU/ml requiring L-thyroxine at 25 mcg/day. Endoscopic transsphenoidal surgery (ETS) was successfully performed and intraoperatively showed suspicion of Rathke's cleft cyst, which histopathologically was reported as an inflammatory polyp. She required a higher dose of L-thyroxine with a temporary replacement of steroids post-op. Her left eye made a full recovery with no residual mass radiologically, but she sustained permanent hypothyroidism.

#### CONCLUSION

Nasal polyps uncommonly lead to ocular nerve palsies. Nevertheless, a huge polyp may resemble a pituitary macroadenoma in terms of biochemical investigation and imaging due to its compressive effect, making a histopathological finding a crucial differentiating tool.

## EP\_A066

### DIAGNOSTIC AND THERAPEUTIC UTILITY OF GONADOTROPHIN-RELEASING HORMONE AGONIST IN POSTMENOPAUSAL HYPERANDROGENISM OF OVARIAN ORIGIN

<https://doi.org/10.15605/jafes.038.S2.84>

**Muhammad Qyairil Anwar Che Zainol,<sup>1</sup> Rosliza Shafie,<sup>2</sup> Noor Rafhati Adyani Abdull<sup>3</sup>**

<sup>1</sup>*Department of Internal Medicine, Hospital Sultanah Bahiyah, Kedah, Malaysia*

<sup>2</sup>*Reproductive Unit, Department of Obstetrics and Gynaecology, Hospital Sultanah Bahiyah, Kedah, Malaysia*

<sup>3</sup>*Endocrinology Unit, Department of Internal Medicine, Hospital Sultanah Bahiyah, Kedah, Malaysia*

#### INTRODUCTION/BACKGROUND

Postmenopausal hyperandrogenism can be due to excessive androgen secretion from adrenal or ovarian virilizing tumours or nonneoplastic conditions, manifesting as increased terminal hair growth or virilization. Ovarian androgen secretion is usually nonautonomous and stimulated by gonadotrophins. The administration of a gonadotrophin-releasing Hormone (GnRH) agonist would suppress the production of androgen. GnRH agonist has been advocated as a diagnostic tool to distinguish between adrenal and ovarian hyperandrogenism. We described a patient with postmenopausal hyperandrogenism who was commenced on GnRH agonist with significant androgen suppression pointing towards ovarian in origin.

#### CASE

A 71-year-old female presented with hirsutism and acne for 2 years. Her Ferriman Gallwey score was 11 with the absence of hoarseness of voice, androgenic alopecia or clitoromegaly. Investigations revealed FSH 23.6 IU/L (26-133), LH 7.54 IU/L (5.16-61.99), oestradiol 40 pmol/L (0-28), testosterone 37.17 nmol/L (0.46-1.18), DHEAS 2 µmol/L (0.26-6.68), 17OHP 4.17 nmol/L (1-8.2), overnight dexamethasone suppression test (ODST) 27.6 nmol/L, ft4 10.78 pmol/L (9-19), TSH 0.69 mIU/L (0.35-4.94), sex hormone binding globulin (SHBG) 39 nmol/L (30-90), free androgen index (FAI) 47.26 (7-10). CT scan of the thorax, abdomen and pelvis revealed normal adrenal glands and bilateral ovaries. Transvaginal ultrasound demonstrated normal ovaries. She was initiated on leuprorelin injection 11.25 mg every 3 months and then switched to triptorelin 3.75 mg every month due to stock shortage. Following the first dose of GnRH agonist, testosterone dramatically reduced to 0.53 nmol/L (98.6% reduction), FSH reduced to 12.4 IU/L (47.5%), and LH reduced to 0.27 IU/L (96.4%) with clinical improvement. The possibility of adrenal hyperandrogenism was ruled out with normal ODST,



17OHP, DHEAS and CT findings. An ovarian source of androgen excess was further confirmed by the marked suppression of testosterone by the GnRH agonist. The histopathological diagnosis of ovarian hyperandrogenism could not be determined as she was not keen for bilateral oophorectomy.

#### CONCLUSION

Postmenopausal hyperandrogenism requires comprehensive assessment. GnRH agonist can be used in the evaluation and it can be adopted as a potential conservative treatment for patients who refuse or are not fit for surgery.

### EP\_A067

#### ANDROGEN-SECRETING OVARIAN STEROID CELL TUMOR: A RARE CASE OF POSTMENOPAUSAL HIRSUTISM AND POLYCYTHEMIA

<https://doi.org/10.15605/jafes.038.S2.85>

Jing Li Lim,<sup>1</sup> Hwee Ching Tee,<sup>1</sup> Jin Hui Ho,<sup>1</sup> Joon Hi Tham<sup>2</sup>

<sup>1</sup>Endocrine Department, Hospital Queen Elizabeth II, Malaysia

<sup>2</sup>Pathology Department, Hospital Queen Elizabeth, Malaysia

#### INTRODUCTION/BACKGROUND

Ovarian steroid cell tumours are very rare sex hormone secreting sex-cord stromal tumours with malignant potential. Steroid cell tumours account for <0.1% of all ovarian tumours. They can occur in females at any age, ranging from 2-80 years old, with the mean age of presentation at around 40 years, most of which are associated with androgenic changes (56-77%), oestrogen secretion in 6-23% and Cushing syndrome in 6-10%. Erythrocytosis can also occur as a result of high testosterone levels.

#### CASE

We report a rare case of ovarian steroid cell tumour presenting with postmenopausal hirsutism and polycythaemia.

A 54-year-old postmenopausal female presented with 2 years history of hirsutism, hoarseness of voice and polycythaemia. A markedly elevated testosterone level at 15.88nmol/l and polycythaemia were noted at initial evaluation. Computed tomography of the abdomen and pelvis revealed a left adnexal solid mass (5.3 x 6.7 x 5.9 cm), for which she underwent extra fascial hysterectomy with bilateral salpingo-oophorectomy, infragastric omentectomy, left pelvic lymph node dissection and appendectomy. Histopathology revealed not otherwise specified subtype of ovarian steroid cell tumours. Within two months of surgery, she showed regression of hirsutism. Polycythaemia and testosterone levels were also normalized after operation.

#### CONCLUSION

This case highlights the importance of considering a neoplastic source of hyperandrogenism in postmenopausal hirsutism with markedly elevated testosterone levels. Bilateral rather than unilateral salpingo-oophorectomy is the treatment of choice for steroid cell ovarian tumour in postmenopausal patients because of the high likelihood of pathological changes in the contralateral ovary.

### EP\_A068

#### GELLER SYNDROME: A RARE CASE OF HYPOKALAEMIA IN PREGNANCY

<https://doi.org/10.15605/jafes.038.S2.86>

Mas Suria

Internal Medicine, Hospital Tengku Ampuan Afzan, Malaysia

#### INTRODUCTION/BACKGROUND

Geller syndrome was first described by David S. Geller in 2000. The disease is rare with only a few cases reported and has an autosomal dominant pathway causing a mutation of mineralocorticoid receptor (MR) S108L. As a result, progesterone which normally antagonises the MR, now acts as a potent agonist due to the mutation. The typical manifestations are hypokalaemia with low aldosterone and renin level along with hypertension which becomes prominent during later stage of pregnancy due to progesterone effect on the mutated receptor.

#### CASE

Our patient was a 26-year-old unbooked gravida 3 para 2 at 27 weeks of gestation, presenting with hypertension and bilateral lower limb weakness. She had occasional vomiting but denied having diarrhea. She also had persistent tachycardia and profound, symptomatic, refractory hypokalaemia while in the ICU. Further history revealed a similar presentation of hypokalaemia with significant lower limbs weakness during her first pregnancy ten years prior which resolved spontaneously after delivery.

Geller syndrome was given as the possible diagnosis but thyrotoxic periodic paralysis was also suspected. Labour was induced as the foetus expired in-utero. She was treated with potassium corrections and carbimazole together with hydrocortisone and broad-spectrum antibiotics. However, her condition deteriorated due to a nosocomial infection despite the resolution of hypokalaemia. She eventually succumbed on day 7 of admission due to severe sepsis.

#### CONCLUSION

Pregnancy-induced hypokalaemia from an activating MR mutation has rarely been reported. This is the first likely Geller's syndrome based on the history and presentation



reported in the country. Prompt recognition is crucial to prevent serious complications to both mother and foetus from hypokalaemia and hypertension. As the hypokalaemia and hypertension resolve postpartum, supportive management during pregnancy is necessary. Otherwise, no specific treatment is warranted.

## EP\_A069

### ANDROGEN INSENSITIVITY SYNDROME WITH METABOLIC SYNDROME: A CHALLENGE IN BALANCING THE HORMONES

<https://doi.org/10.15605/jafes.038.S2.87>

**Fatimah Zaherah Mohamed Shah, Mohd Hazriq Awang, Nur'Aini Eddy Warman, Nur Aisyah Zainordin, Aimi Fadilah Mohamad, Rohana Abdul Ghani**

*Endocrine Unit, Universiti Teknologi MARA, Sungai Buloh, Malaysia*

#### INTRODUCTION/BACKGROUND

Androgen Insensitivity Syndrome (AIS) is an androgen receptor disorder characterised by complete or partial resistance to actions of androgen. Although features of hypogonadism are well-documented, association of AIS with metabolic disorder is not widely recognized.

#### CASE

We describe a case of a female who initially presented at 18-years of age for evaluation of primary amenorrhea. She had infantile female genitalia with minimal secondary sexual characteristics. Investigations revealed high testosterone, with absent uterus and ovaries, and a blind vaginal canal. Chromosomal analysis revealed 46XY, clinching the diagnosis of complete androgen insensitivity syndrome (CAIS).

She underwent gonadectomy for removal of intraabdominal testes a year later and was started on hormonal replacement therapy (HRT), initially with Tibolone for six-years, resulting in significant and continuous weight gain. Her body mass index (BMI) increased from 32 to 45 kg/m<sup>2</sup> in the next few years. Lifestyle modification was unsuccessful, particularly after she developed knee osteoarthritis and reduced mobility. She was given phentermine, with initial weight loss, but with subsequent rebound. During the next few years, she received different types of HRT and developed multiple obesity-related co-morbidities, namely obstructive sleep apnoea requiring continuous-positive-airway-pressure (CPAP), essential hypertension, dyslipidaemia, fatty liver, and was diagnosed to have type 2 diabetes mellitus at 38 years old. Addition of glucagon-

like peptide (GLP)-1 receptor-agonist to metformin resulted in initial weight loss, which then plateaued. Her more recent HRT with estradiol/dydrogesterone caused no further weight-gain. However, with a BMI of more than 50 kg/m<sup>2</sup>, full complement of metabolic syndrome and incapability of weight reduction and maintenance on medical therapy, she was recommended for bariatric surgery.

#### CONCLUSION

This case illustrates the association of metabolic syndrome with AIS, which may contribute to the understanding of the role of androgen receptor in metabolic regulation. Recognising this association aids in understanding the spectrum of conditions associated with AIS and may mitigate some complications due to both androgen and insulin resistance.

## EP\_A070

### VAN WYK-GRUMBACH SYNDROME: A CHILD WITH MENSTRUATION

<https://doi.org/10.15605/jafes.038.S2.88>

**Gerard Jason Mathews, Teh When Yee, Seetha Devi Subramaniam, Joel Mathews, Nor Shaffinaz Yusoff Azmi Merican, Noor Rafhati Adyani Abdullah, Shartiyah Ismail**

*Endocrinology Unit, Department of Medicine, Hospital Sultanah Bahiyah, Malaysia*

#### INTRODUCTION/BACKGROUND

Van Wyk-Grumbach Syndrome (VWGS) is a rare presentation of severe untreated hypothyroidism. Classically, it presents with isosexual pseudopuberty, enlarged multicystic ovaries and delayed bone age.

#### CASE

We report a case of a 10-year-old female who presented to our department with weight gain and severe anaemia (Hb 4.2 g/dL) secondary to menorrhagia. Further history revealed she attained menarche at the age of 8. Her Tanner staging at presentation was B3 and P1. She was obese and short with a height of 127 cm (below 3<sup>rd</sup> centile). She lacked pubic hair, with short stature and delayed bone age which differentiated her from the usual presentation of central precocious puberty. Abdominal ultrasonography revealed bulky uterus with multicystic ovaries. Blood investigations revealed TSH 91.6 mIU/L, T4 12.92 pmol/L, LH 4.6IU/L, FSH 5.1IU /L, estradiol (E2) 984.4 pmol/L. Thyroid peroxidase antibodies were elevated. Therefore, she was diagnosed with severe autoimmune hypothyroidism with precocious puberty.



She was treated with L-thyroxine 100 mcg daily. GnRH Agonist (Leuprorelin) was initiated for a total of 18 months to halt premature puberty and to achieve age-appropriate target height.

#### CONCLUSION

Sexual precocity in a short, obese child with delayed bone age is a harbinger of VWGS. High TSH levels act through FSH receptors inducing an FSH like effect causing the prepubertal response seen in VWGS. Early puberty accelerates growth and promotes bone maturation, leading to early fusions that cause a decrease in final adult height (FAH). In our case, Leuprorelin was used to suppress the secretion of sex hormones, inhibit rapid bone maturation, and prolong the growth period, which improved FAH. This case highlights the importance of recognizing VWGS, so that thyroxine treatment can be initiated.

### EP\_A071

#### SYNDROME OF RESISTANCE TO THYROID HORMONE

<https://doi.org/10.15605/jafes.038.S2.89>

**Tan Jia Miao**

*Department of Internal Medicine, Hospital Tawau, Sabah, Malaysia*

#### INTRODUCTION/BACKGROUND

Resistance to thyroid hormone (RTH) is a rare genetic disorder characterized by clinically mild hyperthyroidism and biochemically elevated circulating free thyroid hormone levels with unsuppressed serum thyroid stimulating hormone. Here we reported the case of a 18-year-old male who was previously under paediatric follow-up for hyperthyroidism but with non-suppressed thyroid stimulating hormone (TSH). When treated with anti-thyroid drug, his thyroid hormone levels normalized but TSH increased, suggesting thyroid resistance.

#### CASE

We present a case of an 18-year-old male who was under paediatric follow-up since infancy. His mother was diagnosed with hyperthyroidism during her third pregnancy, and she underwent radioactive ablation after delivery. His initial cord T4 was 124 nmo/L (124-244 nmol/L), and subsequent serial thyroid function tests revealed persistently high free T4 (FT4), so he was started on propylthiouracil at the age of 1 year and 8 months. After starting an antithyroid medication, his TSH became elevated while his FT4 returned to normal. His TSH returned to normal and FT4 increased after discontinuing the anti-thyroid medication. Even with elevated FT4 and non-suppressed TSH, he remained euthyroid. Clinically,

there was no goitre. All systemic examinations, including his mental development and learning, were normal. His thyroglobulin antibody and thyroid microsomal antibody were positive. Neck ultrasound and TSH receptor antibody levels were both normal. Magnetic resonance imaging of the pituitary revealed no evidence of pituitary adenoma. Because the patient was asymptomatic, the decision was made to discontinue carbimazole. He remained asymptomatic despite having an FT4 in the upper range. Thyroid hormone resistance syndrome was eventually diagnosed. We had our limitations to further workup because the genetic test was not available in our country. He has not needed any antithyroid medication since then.

#### CONCLUSION

This case demonstrates not all hyperthyroidism must be treated with antithyroid medications. Early recognition could avoid unnecessary treatment.

### EP\_A072

#### THE SILENT ATTACK: PANCYTOPENIA AS AN ATYPICAL PRESENTATION OF HASHITOXICOSIS PHASE OF HASHIMOTO'S DISEASE

<https://doi.org/10.15605/jafes.038.S2.90>

**Siti Nabihah Mohamed Hatta, Mohd Fyzal Bahrudin, Zahira Zohari**

*Medical Department, Hospital Sultan Abdul Aziz Shah, Universiti Putra Malaysia*

#### INTRODUCTION/BACKGROUND

Autoimmune thyroid disease (AITD) has been linked to cytopenia with hyperthyroidism causing pancytopenia, while hypothyroidism is linked with anaemia. However, pancytopenia rarely occurs in hypothyroidism. We present a case of alternating hyperthyroidism and hypothyroidism presenting initially with pancytopenia.

#### CASE

A 70-year-old female presented with prolonged fever for three weeks without any other symptoms. Physical examination was normal, but initial blood tests showed cytopenia of all cell lineage with no identified cause. Screening tests for malnutrition, infection, tuberculosis, and connective tissue disease were normal.

CECT Thorax Abdomen and Pelvis showed only multiple thyroid nodules. Thyroid function showed hyperthyroidism with TSH levels <0.01 ml/UL, fT4 28pmol/L, elevated anti-TG, and anti-TPO, while TSI was normal. Carbimazole 5 mg daily was initiated for hyperthyroidism. Two months later, the patient showed symptoms and signs of



hypothyroidism, TSH 57.10 ml/UL and fT4 2.72 pmol/L, consistent with diagnosis of Hashimoto's disease. Carbimazole was discontinued, L-thyroxine replacement initiated. Follow up period noted normalization of thyroid function, but poor recovery of pancytopenia under further evaluation and management by haematologist.

Hashimoto's disease can present with alternating hyperthyroidism known as hashitoxicosis phase, followed by hypothyroid state. Hyperthyroidism-induced pancytopenia is caused by decreased production of haemopoietic cells or increased destruction by immunological mechanisms or hypersplenism. However, the exact mechanism of hypothyroidism-induced pancytopenia is not well understood, but it is thought to be related to the immune system's dysregulation leading to a decrease in the lifespan of certain blood cells.

#### CONCLUSION

Hashimoto's disease needs to be considered as a differential diagnosis for pancytopenia. Resolution of pancytopenia is usually achieved after reaching a euthyroid state, but further haematological evaluation may be needed if the condition persists.

### EP\_A073

#### OVERT HYPOTHYROIDISM COMPLICATED BY STROKE IN A YOUNG PREGNANT WOMAN

<https://doi.org/10.15605/jafes.038.S2.91>

Noor Amirah Mohd Hairani,<sup>1</sup> Mohd Fyzal Bahrudin,<sup>2</sup> Ooi Chuan Ng<sup>1</sup>

<sup>1</sup>Faculty of Medicine and Health Sciences UPM, Selangor Malaysia

<sup>2</sup>Department of Internal Medicine, Hospital Sultan Abdul Aziz Shah UPM, Selangor, Malaysia

#### INTRODUCTION/BACKGROUND

Overt hypothyroidism in pregnancy presenting with stroke is infrequent. Physiological changes during pregnancy have the potential of masking hypothyroidism, making its diagnosis challenging. Hypothyroidism in pregnancy augments the hypercoagulable state leading to stroke.

#### CASE

We are reporting a previously well 25-year-old female, who was gravida 2 para 1 at 9 weeks of gestation who presented with sudden onset of right sided body weakness, slurring of speech and headache. She was found to have overt hypothyroidism. She had weight gain of 8 kg for 2 months associated with constipation. At presentation, she had a brief loss of consciousness followed by slurred speech and

numbness over the right limb. Her GCS was E4V5M6 with blood pressure of 144/96 mmHg, regular pulse rate of 80 beats per minute and normal temperature. She has no goitre, coarse hair, and pitting oedema. National Institutes of Health (NIH) stroke scale was 9/42. MRI revealed left basal ganglia infarct with large vessel occlusion at M1, while the cerebral angiogram shown left M1 occlusion. As thrombolysis was contraindicated because of pregnancy, thrombectomy was attempted. Left M1 occlusion was recanalized but residual clot persisted at superior branch of left M1. Autoimmune work-up was negative. Additional laboratory work-up for young stroke, revealed significantly abnormal thyroid function tests with T4: 7 pmol/L (9-19 pmol/L) and TSH of 14.87 mIU/L (normal value: 0.35-4.94 mIU/L). With positive antithyroglobulin (TG) antibodies of 1189.4 IU/mL (normal value: <4.11 IU/ml) and anti- thyroperoxidase (TPO) antibodies of 1158.4 IU/ml (normal value: <5.61 IU/ml), a diagnosis of hypothyroidism secondary to Hashimoto's disease was made. She was given thyroxine replacement.

#### CONCLUSION

In conclusion, overt hypothyroidism in pregnancy is associated with an increased risk of stroke due to changes in lipid metabolism, inflammation, and blood coagulation. Pregnant women with hypothyroidism should receive appropriate management to reduce their risk of stroke.

### EP\_A074

#### ACUTE MYOCARDIAL INFARCTION MASKING THYROTOXICOSIS IN PREGNANCY

<https://doi.org/10.15605/jafes.038.S2.92>

Nur Hidayah MM, Masliza Hanuni MA, Sini Sanaa WA

Endocrine Unit Hospital Sultanah Nur Zahirah, Terengganu, Malaysia

#### INTRODUCTION/BACKGROUND

Myocardial infarction in pregnancy is a rare incidence with cases ranging from 1 to 10 per 100 000 deliveries and only 2% are caused by vasospasm. A direct explanation or mechanism as to how hyperthyroidism can cause acute myocardial infarction is not fully understood, but a few mechanisms has been proposed and one of it is related to coronary artery vasospasm.

#### CASE

We report a case of a 28-year-old female with twin pregnancy at 11 weeks of gestation, presenting with severe left sided chest pain radiating to left upper limb. She had no previous thyroid disease and was clinically euthyroid. Blood pressure was 119/76 with pulse rate 100 beats per minute at presentation.



Electrocardiography done showed ST elevation at inferior lead with lateral involvement. CKMB done was 724 u/L (< 24). Thrombolysis achieved no resolution of ST elevation post thrombolysis. Echocardiography shows basal posterior dyskinesia. Coronary angiography revealed normal coronary arteries. Thyroid function test (TFT) reveals TSH <0.005 mIU/L (0.4 – 4.0), free T4 (fT4) 58.31 pmol/L (7.8 – 14.4) and T3 16.73 pmol/L. TSH-receptor antibody <0.80 iu/L (<1.75). The liver enzymes were deranged with AST 833 u/L (<75) and ALT 185 u/L (<45). She was diagnosed as Myocardial Infarction with Non-Obstructive Coronary Arteries (MINOCA) with thyrotoxicosis. She was started on Lugol's solution in the ward. Prior to discharge, her repeat TSH was <0.005 mIU/L and fT4 14 pmol/L after 5 days of Lugol's. She was discharged with Carbimazole 15 mg daily which was stopped at 19 weeks as TFTs normalized.

#### CONCLUSION

Thyrotoxicosis can have a variety of presentations and AMI is one manifestation. It should be considered in a patient presenting with acute MI who do not fit the usual demography and has no obvious risk factors for coronary artery disease.

### EP\_A075

#### SEEING BLUES ALL AROUND: A CASE OF PROPYLTHIOURACIL-INDUCED CYANOPSIA

<https://doi.org/10.15605/jafes.038.S2.93>

Noor Hafis Md Tob, Chin Voon Tong, Joel Xiang Loong Lee, Siow Ping Lee, Melissa Vergis  
*Malacca Hospital, Malaysia*

#### INTRODUCTION/BACKGROUND

Cyanopsia is a subjective symptom characterized by a bluish appearance of the overall visual field and has been reported among patients taking phosphodiesterase-5 inhibitors. Propylthiouracil (PTU) is a member of the thiouracil group and widely used for the treatment of thyrotoxicosis. Despite being associated with various side effects, such as hepatitis, agranulocytosis, body rash, and antineutrophil cytoplasmic antibody (ANCA)-associated vasculitis, PTU-related cyanopsia has not been reported.

#### CASE

In this report, we describe a case of PTU-induced cyanopsia, including the results of biochemical laboratory tests. We also discuss treatment strategies and include literature review.

A 33-year-old female presented with palpitations and tremors. Clinically, she appeared anxious with hand tremor and diffuse goiter. Her pulse was regular, and other systemic

examinations were unremarkable. Thyroid function tests (TFTs) showed overt hyperthyroidism with suppressed thyroid-stimulating hormone (TSH) levels (<0.008 mIU/L) and high free T4 levels (55.9 pmol/L). She was treated for Grave's disease with carbimazole but developed significant urticaria. PTU was then introduced, but she developed a bluish appearance of her surrounding vision right after the second dose. The symptoms subsided after one day of discontinuing PTU. Re-challenging with PTU at a lower dose also resulted in a similar effect. Eye assessment by ophthalmology was normal. She was then given propranolol and cholestyramine to control her thyroid status. Definitive treatment with radioactive iodine will be administered once her thyroid function improves.

PTU is one of the mainstay oral medications for hyperthyroidism and is generally well-tolerated. However, PTU-induced cyanopsia may limit oral treatment options, although the phenomenon appears reversible after stopping medication, regardless of the dose. It may cause significant distress and lead to discontinuation of treatment.

#### CONCLUSION

We report here, the first known case of PTU-induced cyanopsia.

### EP\_A076

#### MYXEDEMA ASCITES: A RARE INITIAL PRESENTATION OF HASHIMOTO THYROIDITIS

<https://doi.org/10.15605/jafes.038.S2.94>

Sanmuga Vimalanathan and Sivasangkari Mugilarasan

*Department of Medicine, Hospital Taiping, Malaysia*

#### INTRODUCTION/BACKGROUND

Ascites due to hypothyroidism is rare and only occurs in less than 4% of cases. Here, we present a case of severe hypothyroidism due to Hashimoto's thyroiditis, where the patient's initial presentation was gross ascites.

#### CASE

A 45-year-old male who has hypertension, presented with worsening abdominal distension for 1 month. Examination showed gross ascites and bilateral lower limb oedema with no other stigmata of chronic liver disease. Peritoneal fluid Serum-Ascites Albumin Gradient (SAAG) was 0.5 g/dL, suggesting a non-portal hypertension cause of ascites with high protein level of 2.9 g/dL and presence of lymphocytes count of 30 cell/mm<sup>3</sup>. Peritoneal fluid examination, imaging and endoscopy findings excluded the usual causes of ascites. Patient showed no response



to initial treatment with diuretics and required multiple abdominal paracentesis. Echocardiogram showed presence of loculated pericardial effusion at posterior wall measuring 1.15 - 1.44 cm. Thyroid function test (TFT) was then done, showed severe hypothyroidism (Free T4 <5.41 pmol/L and TSH 89.71 mIU/L) secondary to Hashimoto's thyroiditis (anti-TPO 205 IU/mL). Patient was started on L-Thyroxine 150 mcg OD. There was significant resolution of ascites with normalisation of TFT.

It was postulated that low level of T3, increases level of Hyaluronic acid (HA), HA then induces capillary leak which results in fluid accumulation. Literature suggests that in patients with ascites who have SAAG less than 1.1 g/dL, high protein level (>2.5 g/dL), and predominant cell count of lymphocytes, hypothyroidism should be suspected. Early suspicion of hypothyroidism prevents patients from undergoing unnecessary procedures while its treatment provides resolution of ascites.

#### CONCLUSION

Hypothyroidism should be considered in patients with unexplained cause of ascites.

### EP\_A077

#### A RARE PRESENTATION OF SYMPTOMATIC COMPLETE HEART BLOCK IN A MILDLY HYPERTHYROID PATIENT

<https://doi.org/10.15605/jafes.038.S2.95>

Alia Anis Y,<sup>1</sup> Masliza Hanuni MA,<sup>1</sup> Siti Sanaa WA,<sup>1</sup> Ahmad Wazi R<sup>2</sup>

<sup>1</sup>Endocrinology Division, Medical Department, Hospital Sultanah Nur Zahirah, Kuala Terengganu, Malaysia

<sup>2</sup>Cardiology Division, Medical Department, Hospital Sultanah Nur Zahirah, Kuala Terengganu, Malaysia

#### INTRODUCTION/BACKGROUND

Hyperthyroidism mainly causes sinus tachycardia and atrial fibrillation. Complete heart block is an extremely rare complication of hyperthyroidism with very few cases reported, mainly in association with acute inflammatory disease, hypercalcemia, administration of drugs, or structural heart disease.

#### CASE

Here, we report a case of a 62-year-old male with underlying DM, hypertension and cerebrovascular accident. He was brought in for syncopal attack with lethargy, profuse sweating, and dizziness. He denied any history of fever or anginal chest pain. Upon arrival BP was 151/49 mmHg, with heart rate of 27-34 bpm. Systemic examination was unremarkable; there was no goitre or thyroid eye sign present.

Serial ECG revealed complete heart block and he was initially managed with intra- venous infusion (IVI) of adrenaline and dopamine, IV atropine boluses and followed by transvenous pacemaker (TPM) insertion. Laboratory investigation including FBC, RP, electrolytes, liver enzymes, and cardiac enzymes were all within normal range.

However, thyroid function test showed mild hyperthyroidism with free T4 of 16.4 pmol/l (7.86-14.41), and TSH 0.115 mIU/L (0.38-5.33). TSH receptor antibody was negative. Echocardiography demonstrated good left ventricular systolic function with ejection fraction of 55%, and no regional wall motion abnormalities which made an ischemic aetiology as unlikely. We commenced carbimazole at a dose of 10 mg daily. Subsequently permanent pacemaker was inserted due to dependency on TPM. He had an uneventful recovery and was discharged well.

#### CONCLUSION

The exact mechanism of complete atrioventricular (AV) block remains unclear. Few reports postulated that interstitial inflammation of the AV node and His-bundle or focal myocarditis around the AV node could have led to cumulative damage to the cardiac conduction system. This case reiterates the importance of recognizing the association between complete AV block and hyperthyroidism due to the rarity of this condition. There is still insufficient information regarding the optimal management of this condition.

### EP\_A078

#### THE INNOCENT CARBIMAZOLE

<https://doi.org/10.15605/jafes.038.S2.96>

Wee Mee Cheng,<sup>1</sup> Yueh Chien Kuan,<sup>1</sup> Qi Ji Lai,<sup>2</sup> Sharifah Aishah bt Wan Mohamad Akbar<sup>3</sup>

<sup>1</sup>Endocrine Unit, Medical Department Sarawak General Hospital, Malaysia

<sup>2</sup>Pathology Department, Sarawak General Hospital, Malaysia

<sup>3</sup>Rheumatology Unit, Medical Department Sarawak General Hospital, Malaysia

#### INTRODUCTION/BACKGROUND

Agranulocytosis is a life-threatening condition with mortality rate of 21.5% seen in 0.30.6% of patients taking thionamides. However, thionamides may not be the only culprit and other aetiologies should be considered.

#### CASE

We describe here a 29-year-old male with Grave's disease diagnosed since 2017 who was recently restarted on high dose carbimazole after a period of non-adherence leading to raised Free T4 53.7 pmol/L [13.1 - 21.3] with



suppressed TSH. He presented with fever, sore throat, and malaise. Blood investigations revealed leukopenia with agranulocytosis and thrombocytopenia - total white cells of  $1.81 \times 10^3/\text{ul}$ , neutrophil count of  $0.65 \times 10^3/\text{ul}$  and platelet of  $110 \times 10^3/\text{ul}$ . Renal and liver profile were normal, but his lactate dehydrogenase was elevated at 716 U/L [135 - 225].

He was admitted with the initial suspicion of carbimazole-induced agranulocytosis. Hence, carbimazole was withheld and treatment with cholestyramine 16 g/day, broad spectrum antibiotics and subcutaneous Neupogen were commenced. Oral lithium was later added but he developed generalized maculopapular rash.

However, as physical examination revealed generalised lymphadenopathy, other differential diagnoses were also pursued. Finally histopathological examination of the excisional biopsy of the right inguinal lymph node showed necrotising histiocytic lymphadenitis consistent with Kikuchi-Fujimoto disease. Anti-nuclear antibody was negative and complements levels were normal. The rheumatology team initiated oral prednisolone and this was followed by prompt recovery of blood counts (total white cells  $9.29 \times 10^3/\text{ul}$ , neutrophil  $3.39 \times 10^3/\text{ul}$  and platelet  $196 \times 10^3/\text{ul}$ ) a week later. He was restarted on carbimazole to render him euthyroid before definitive thyroidectomy.

#### CONCLUSION

This case describes a rare case of Kikuchi-Fujimoto disease and highlights the importance of considering and pursuing other aetiologies of agranulocytosis especially in a patient who has been on and off carbimazole for years.

### EP\_A079

#### SEVERE MARROW APLASIA SECONDARY TO CARBIMAZOLE

<https://doi.org/10.15605/jafes.038.S2.97>

**Nur Adani Ishak, Elliyyin Katiman, Hazwani Aziz**  
*Endocrine Unit, Department of Medicine, Hospital Kajang, Selangor, Malaysia*

#### INTRODUCTION/BACKGROUND

One of the adverse effects of thionamide therapy for Graves' disease is agranulocytosis. Generally, agranulocytosis recovers spontaneously after withdrawal of thionamide or with short course of granulocyte colony-stimulating factor (G-CSF).

#### CASE

We report a case of Graves' disease presenting with delayed recovery of severe agranulocytosis after treatment with Carbimazole.

A 26-year-old female diagnosed with Graves' disease with high antibody titre presented with fever and sore throat after one month treatment with carbimazole 30 mg daily. She was treated as neutropenic sepsis with severe agranulocytosis. The baseline absolute neutrophil count was  $0.01 \times 10^9/\text{L}$  (3.929-7.147). She was started on G-CSF and broad-spectrum antibiotics including Piperacillin/Tazobactam and subsequently escalated to Meropenem. Her thyrotoxicosis was treated with lithium, prednisolone, and cholestyramine. Haematology team was also consulted in view of delayed recovery of severe aplasia and she was prepared for possible bone marrow transplant. The patient's neutrophil counts recovered only after seven days of G-CSF treatment.

It was later observed that she was not responding to treatment after two months of optimized dose of lithium, prednisolone, and cholestyramine. Hence, the patient was planned for semi-urgent total thyroidectomy. During admission for surgery, her fT4 level was 58.9 pmol/l (7.88 - 14.41). She required 3 cycles of plasma exchange and Lugol's iodine prior to thyroidectomy as part of pre-operative optimization. She underwent total thyroidectomy with fT4 level of 33.5 pmol/l. The surgery was successful with transient hypocalcaemia postoperatively.

#### CONCLUSION

This case showed a rare incident of delayed recovery of severe marrow aplasia secondary to Carbimazole. In view of resistance to second line thyrotoxicosis treatment, the patient underwent semi-urgent total thyroidectomy with plasma exchange prior to surgery.

### EP\_A080

#### SUCCESSFUL TREATMENT OF HYPOTHYROIDISM WITH RECTAL LEVOTHYROXINE: A CASE REPORT

<https://doi.org/10.15605/jafes.038.S2.98>

**Woh Wei Mak, Yong Siang Ng, Qing Ci Goh, Gayathri Devi Krishnan, Yoke Mui Ng, Shazatul Reza Mohd Redzuan, Subashini Rajoo, Mohamed Badrulnizam Long Bidin**  
*Hospital Kuala Lumpur, Malaysia*

#### INTRODUCTION/BACKGROUND

Appropriate hormone replacement therapy is the cornerstone of management and is typically in the form of oral levothyroxine. The aim of this case report is to describe an alternative route when the oral and parenteral routes are not available.



## CASE

Our patient was a 73-year-old male diagnosed with recurrent transglottic squamous cell carcinoma (T2N0M0) and had total laryngectomy, total thyroidectomy and bilateral neck dissection done. Oral thyroxine replacement 100 mcg (1.3 mcg/kg/day) daily was started 3 days post operatively. Patient's post operative recovery was complicated with neck wound breakdown with suspicion of pharyngo-cutaneous fistula and was subsequently started on total parental nutrition by day 12 post operation. Patient was referred to endocrine team due to worsening hypothyroidism FT4 7.68 pmol/L (12.0-22.0) TSH 12.8 mIU/L (0.27-4.20). On examination, patient was conscious, alert, GCS full, BP 127/75 mmHg, pulse rate 86 beats per minute, on vacuum dressing over neck wound, reflexes normal, clinically asymptomatic of hypothyroidism. Patient was converted to per rectal administration of levothyroxine. Levothyroxine tablet was crushed and mix with 10 mls of water and 20 mls of lignocaine gel, pushed into rectum with nasogastric tube.

Patient was initially started on 2.6 mcg/kg/day per rectal thyroxine and subsequently increased to 4 mcg/kg/day 5 days later due to the lack of adequate biochemical response. Thyroid function normalized after 3 weeks of therapy, with FT4 18.4 pmol/L (12.0-22.0) TSH 2.80 mIU/L (0.27-4.20).

## CONCLUSION

In conclusion, per rectal administration of levothyroxine can be a useful, safe, and effective alternative to oral levothyroxine in conditions precluding oral administration. We should advocate for increased availability of rectal levothyroxine preparations worldwide.

## EP\_A081

### A CASE OF TRIPTORELIN-INDUCED THYROIDITIS

<https://doi.org/10.15605/jafes.038.S2.99>

Marisa Khatijah Borhan,<sup>1</sup> Shirenee Ratna Vethakkan,<sup>1</sup> Jeyakantha Ratnasingam,<sup>2</sup> Lee-Ling Lim,<sup>2</sup> Sharmila Sunita Paramshivam<sup>2</sup>

<sup>1</sup>University Malaya Medical Centre, Kuala Lumpur, Malaysia

<sup>2</sup>Medical Department, Hospital Sultanah Aminah, Johor Bahru, Malaysia

## INTRODUCTION/BACKGROUND

Gonadotrophin-releasing hormone agonists (GnRHa) therapy has been associated with thyroid dysfunction, including thyroiditis. Triptorelin, a GnRHa, is used as androgen deprivation therapy (ADT) in men with prostate cancer. We present a case of triptorelin-induced thyroiditis in a patient with locally advanced prostate cancer.

## CASE

An 83-year-old male with underlying stable prostate cancer presented with an acute transient episode of abnormal behaviour. After completed radiotherapy, he was on 3-monthly SC leuprorelin before recently changing to 3-monthly SC triptorelin. He had received the second dose of SC triptorelin 4 weeks prior to presentation. A plain brain CT ruled out a space-occupying lesion. His renal profile, serum calcium, glucose and dementia workup were normal, except for a deranged TFT [suppressed TSH (0.01 mIU/L, N:0.55-4.78), high fT4 (55.1 pmol/L, N:11.5-22.7), high fT3 (13.0 pmol/L, N:3.5-6.5)]. Baseline TFT taken two years ago was normal. He had no fever, neck pain, dysphagia, respiratory or thyrotoxicosis symptoms. He denied any family history of thyroid disease, recent vaccination, or supplement use, including biotin. He was clinically euthyroid, and there was no evidence of Graves' ophthalmopathy, tremor, atrial fibrillation, or a goiter. Serum anti-TPO antibody was raised (67.2 iu/mL, N<35.0). Lumbar puncture findings were normal and the cerebrospinal fluid anti-TPO antibody was not detected. Technetium-99m uptake scan reported reduced uptake in both thyroid lobes, suggestive of thyroiditis. Hence, a diagnosis of triptorelin-induced thyroiditis was made. Upon discharge, his behaviour normalized and his TFT improved (TSH 0.02 mIU/L, fT4 32.3 pmol/L, fT3 6.7 pmol/L) without antithyroid drugs or glucocorticoids. During clinic review two months after he completed ADT, he was clinically euthyroid and his TFT had normalized (TSH 1.96m IU/L, fT4 12.0 pmol/L).

## CONCLUSION

Patients with thyroid autoimmunity are more susceptible to thyroid dysfunction after GnRHa administration, probably due to GnRHa immunostimulatory actions, emphasizing need for TFT monitoring during GnRHa treatment. Those with persistent thyroid dysfunction after discontinuation of GnRHa therapy may require treatment.

## EP\_A082

### ONE-YEAR AUDIT OF PATIENTS ADMITTED WITH THYROID DISORDERS TO THE MEDICAL DEPARTMENT, SIBU HOSPITAL

<https://doi.org/10.15605/jafes.038.S2.100>

Lau Pei Ying, Lai Shu Xian, Eunice Lau Yi Chwen  
Sibu Hospital, Malaysia

## INTRODUCTION

The prevalence of thyroid disorders in Malaysia is around 3.4%. It is the second most common endocrine disorder after diabetes. Organ dysfunction related to thyroid disorders such as hyperthyroidism and hypothyroidism may result in significant morbidity and mortality.



## METHODOLOGY

This was a retrospective review of patient medical records who were admitted to the medical department of Hospital Sibul between January 2022 to December 2022 department with hyperthyroidism and hypothyroidism. Patient demographics, clinical and biochemical data were documented and analysed

## RESULT

There was a total of 94 admissions during this period. The mean patient age was 57.2 years (14 to 91 years old) with a female preponderance (61%). Most of the patients were thyrotoxic, 64% while 36% had hypothyroidism. The most common indication for hospitalization was atrial fibrillation (AF) (33%). Cardiac disease was a complication in 52% of admissions, predominantly AF and heart failure. Other thyroid-related complications included stroke, hyponatremia, hypokalaemic periodic paralysis and agranulocytosis. 2 (2%) patients were admitted for thyroid storm. Approximately one-third of patients were newly diagnosed during the admission and 5 (5%) patients had previously defaulted follow-up and treatment.

## CONCLUSION

This study shows that a large proportion of patients admitted had poorly controlled thyroid function with multiple complications. This highlights the need for improved education and access to diagnostic and treatment facilities in our local population.

## EP\_A083

### RETROSPECTIVE ANALYSIS AND EVALUATION OF SPECIALISED MULTIDISCIPLINARY THYROID EYE SERVICES IN A TERTIARY CENTRE IN MALAYSIA

<https://doi.org/10.15605/jafes.038.S2.101>

Tan Ying Jie,<sup>1</sup> Teh When Yee,<sup>2</sup> Tan Yi Shan,<sup>2</sup> Chai Huei Xian,<sup>3</sup> Adlina Abdul Rahim,<sup>3</sup> Noor Raffhati Adyani Abdullah<sup>3</sup>

<sup>1</sup>Endocrinology Unit, Department of Internal Medicine, Hospital Sultanah Bahiyah, Kedah, Malaysia

<sup>2</sup>Department of Internal Medicine, Hospital Sultanah Bahiyah, Kedah, Malaysia

<sup>3</sup>Oculoplasty Unit, Department of Ophthalmology, Hospital Sultanah Bahiyah, Kedah, Malaysia

## INTRODUCTION

Thyroid eye disease (TED) is one of the major extrathyroidal manifestations of Graves' disease encountered in a variety of clinical settings from primary to tertiary care. Failure to engage appropriate therapeutic options in a timely manner

may contribute to a suboptimal outcome. The American Thyroid Association and the European Group on Graves' Orbitopathy (EUGOGO) highlighted the paramount importance of specialised multidisciplinary clinics for the management of TED. In Malaysia, combined thyroid eye clinics are not readily accessible, and many patients with TED are managed outside multidisciplinary clinics.

## METHODOLOGY

We conducted a retrospective evaluation on TED patients treated in our multidisciplinary thyroid eye clinics from March 2021 to March 2023. Data collected for all patients included demographics, endocrine thyroid data, thyroid eye clinical metrics, treatments, and outcomes with comparison between the first and final visits.

## RESULTS

Out of 51 patients who attended the clinics, 60.8% (31/51) were female, 76.5% (31/51) were Malays. 23.5% (12/51) were current smokers, and 91.6% (11/12) received smoking cessation advice. Mild, moderate-severe and sight-threatening TED were seen in 35.3%, 47.1% and 17.6%, respectively. Biochemical euthyroidism was attained by 76.7% (33/48) compared to 23% (10/51) from the initial visit ( $p=0.001$ ). Active TED was seen in 33% (17/51); none were active during the last visit ( $p=0.001$ ). IV methylprednisolone was given in 23% (12/51) throughout their follow-up. Median cumulative IV methylprednisolone was 4250 mg  $\pm$  3937.50. Second-line immunosuppressive therapy was given in 29.4% (15/51). Orbital decompressive surgery was done in 9.8% (5/51) as part of the management of active sight-threatening disease or as rehabilitation surgery. All patients with moderate-severe and sight-threatening disease received their treatment within seven days.

## CONCLUSION

Specialised multidisciplinary TED clinics demonstrated favourable outcomes for patients to attain biochemical euthyroidism and improvement in overall TED care.



## EP\_A084

### TROCHANTERIC FEMORAL FRACTURE UNRAVELS FUNCTIONAL METASTATIC FOLLICULAR THYROID CARCINOMA: A CASE REPORT

<https://doi.org/10.15605/jafes.038.S2.102>

Ilham Ismail, Chee Keong See, Saiful Shahrizal Shudim, Nurbadriah Jasmiad, Zhe Lan Wong, Eileen Tan

*Hospital Sultan Haji Ahmad Shah, Temerloh, Malaysia*

#### INTRODUCTION

In postmenopausal women, the aetiology of low-trauma trochanteric femoral fractures is often attributed to osteoporosis. However, a pathologic fracture must also be considered. Follicular thyroid carcinoma (FTC) is the second most common thyroid malignancy, but it rarely co-exists with hyperthyroidism. FTC can metastasize to bone, lung and mediastinum. Functioning metastatic disease in FTC is rare but have been reported in literature.

#### CASE

We report a case of metastatic FTC presenting with a pathologic trochanteric fracture and uncontrolled hyperthyroidism.

A 63-year-old female sustained a closed intertrochanteric femoral fracture following a low-trauma fall. She was receiving antithyroid medication for hyperthyroidism. Initial tests showed elevated FT4 (30.7 pmol/L), suppressed TSH and negative thyroid autoantibodies. Neck ultrasonography showed multiple thyroid nodules, including a 5.6 cm x 6.5 cm TIRADS 5 nodule. Following FNAC showing follicular neoplasm, she underwent total thyroidectomy with level 6 paratracheal lymph node dissection due to tumour infiltration of the right internal jugular vein (IJV) and parathyroid gland. Histopathology revealed a high-risk invasive FTC (pT4apN1a). Despite thyroidectomy, she remained hyperthyroid and required increased antithyroid therapy. Postoperative neck CT and carotid angiography revealed residual thyroid tissue and long segment IJV and superior vena cava thrombosis. No residual tissue was detected on re-operation. Concomitant high thyroglobulin (>5000 ng/mL) prompted F-fluorodeoxyglucose PET/CT which revealed recurrent disease at the thyroid bed, and metastases to cervical nodes, mediastinum, lungs, left femur and trochanter.

#### CONCLUSION

This illustrates a complex case of FTC coexisting with hyperthyroidism, and metastases likely to be functionally active thyroid tissue. Subsequent management would

require combined surgical intervention for trochanteric fracture with local radiation therapy and radioiodine ablative therapy.

## EP\_A085

### THE CONUNDRUM OF RADIOACTIVE IODINE TREATMENT IN CONCOMITANT DIFFERENTIATED THYROID CARCINOMA AND GRAVES' OPHTHALMOPATHY

<https://doi.org/10.15605/jafes.038.S2.103>

Ee Wen Loh, Shireene Ratna Vethakkan, Jeyakantha Ratnasingam, Lee-Ling Lim, Quan Hziung Lim, Nicholas Ken Yoong Hee, Sharmila Sunita Paramasivam

*University Malaya Medical Centre, Kuala Lumpur, Malaysia*

#### INTRODUCTION

Although uncommon, concomitant differentiated thyroid carcinoma (DTC) has been reported in patients with Graves' disease (GD). Surgery is the mainstay treatment for DTC followed by radioactive iodine (RAI) ablation in selected patients. RAI therapy may pose a problem in patients with concurrent Graves' ophthalmopathy (GO) as it may potentially worsen the ophthalmopathy. This could result in a treatment conundrum.

#### CASES

**Case 1.** A 63-year-old female presented with significant bilateral exophthalmos and ophthalmoplegia. She had a diffuse goiter and was thyrotoxic, with high TSH-stimulating immunoglobulin (TSI) levels. She was diagnosed as GD with sight-threatening GO. She received multiple courses of methylprednisolone as well as immunosuppressant therapy for GO. She underwent total thyroidectomy as definitive therapy. Histopathologic examination (HPE) of the thyroid gland revealed papillary thyroid carcinoma (PTC) in both thyroid lobes, with resection margin of <0.1cm in the right lobe. Following counseling for RAI ablation, she refused RAI due to the risk of worsening GO. She is currently on regular surveillance with no evidence of PTC recurrence to date.

**Case 2.** A 41-year-old female developed moderate active GO three years after initial diagnosis of GD. She was given high-dose prednisolone for GO and underwent total thyroidectomy as definitive therapy for GD. HPE showed multifocal follicular thyroid carcinoma with suspicion of vascular permeation. After multi-disciplinary discussions, she underwent 10 fractions of ocular radiotherapy and received prophylactic prednisolone cover during RAI. On close monitoring, her GO has remained stable thus far.



## CONCLUSION

Managing DTC in the presence of GO represents a significant challenge to the treating physician. A multidisciplinary approach and in-depth discussion with patients are essential in making treatment decisions.

## EP\_A086

### MYELODYSPLASTIC SYNDROME AND GRAVES' DISEASE

<https://doi.org/10.15605/jafes.038.S2.104>

**Yong Siang Ng, Qing Ci Goh, Woh Wei Mak, Gayathri Devi Krishnan, Yoke Mui Ng, Shazatul Reza Mohd Redzuan, Subashini Rajoo, Mohamed Badrulnizam Long Bidin**

*Hospital Kuala Lumpur, Malaysia*

#### INTRODUCTION

Myelodysplastic syndrome (MDS) is a heterogeneous group of hematopoietic neoplasms characterized by bone marrow failure resulting in cytopenia and dysplastic haematopoiesis. The association between MDS and autoimmune diseases has been previously described in the literature. Here we report a case of Graves' disease (GD) with secondary MDS.

#### CASE

A 43-year-old male with vitiligo was admitted for pancytopenia and left parapneumonic effusion. GD was concomitantly diagnosed based on weight loss, tachycardia, exophthalmos and the presence of TSH receptor antibodies. Antithyroid drugs were carefully used with close monitoring of cell counts. Despite clinical improvement with antibiotics and achievement of biochemical control of hyperthyroidism, cytopenia persisted. Results showed WBC  $1.58$  to  $3.38 \times 10^9/L$ , absolute neutrophil counts  $0.65$  to  $1.18 \times 10^9/L$ , haemoglobin  $9.6$  to  $10.6$  g/L, and platelet counts  $74$  to  $10^7 \times 10^9/L$ . Autoimmune panels tested negative. Peripheral blood film revealed pancytopenia without evidence of haemolysis or blast cells. Bone marrow aspirate and trephine biopsy showed mildly hypocellular marrow with relatively reduced myelopoiesis together with subtle dysplastic changes of erythrocytes and megakaryocytes. No cytogenetic abnormality was detected.

Emerging evidence suggests that autoimmune diseases are risk factors for MDS. A Swedish population-based study demonstrated an apparent link between the development of MDS and autoimmune diseases. Most of the reported cases had a history of hypothyroidism. The development of MDS in relation to autoimmune diseases is still poorly understood. The proposed explanations include shared genetic or environmental risk factors, a direct insult to

the bone marrow leading to malignant transformation by untreated autoimmune diseases, or the inflammatory process from a haematological neoplasm resulting in the subsequent diagnosis of an autoimmune disease.

## CONCLUSION

Our case highlighted the association between autoimmune thyroid disease (GD) and MDS. Further studies to underpin the association and pathophysiology are required.

## EP\_A087

### THE CALM BEFORE THE STORM AND THE STORM BEFORE THE CALM: A CASE OF RETRACTABLE THYROID STORM

<https://doi.org/10.15605/jafes.038.S2.105>

**Mohd Hazriq A, Aimi Fadilah M, Nur Aini EW, Aisyah Z, Fatimah Zaherah MS, Rohana AG**

*Fakulti Perubatan, Universiti Teknologi MARA (UiTM), Sungai Buloh, Malaysia*

#### INTRODUCTION

Thyroid storm is a severe complication of hyperthyroidism with a high mortality rate. Multimodal pharmacotherapy is the cornerstone of treatment. In severe cases, plasmapheresis may also be done. However, this practice is not widespread with a lack of clear guidelines.

#### CASE

We describe a 37-year-old female with severe thyroid storm and multiple organ failure. She initially presented with a three-week history of worsening jaundice, dyspnea and pedal edema. At presentation, she was neurologically intact but had prominent jaundice, congestive heart failure, atrial fibrillation, goiter and mild thyroid ophthalmopathy. Tests revealed elevated FT4  $>90$  pmol/L, TSH  $<0.01$  mIU/L, bilirubin  $267$   $\mu\text{mol/L}$  and coagulopathy. With a Burch-Watforsky Point Scale of 65, full pharmacotherapy for thyroid storm was promptly instituted. Due to lack of clinical improvement and rising bilirubin, we resorted to plasmapheresis after seven days with a view for early thyroidectomy. Plasmapheresis was administered over three sessions and resulted in normalization of FT4 ( $14.32$  pmol/L), resolution of heart failure, and improvement of bilirubin and other blood parameters. Three days later, sensorium quickly deteriorated to coma requiring intubation. EEG showed nonconvulsive seizure; other neurologic investigations were non-contributory. Her condition was further complicated with retractable arrhythmia, worsening coagulopathy with lower gastrointestinal bleed, and rising FT4 level and liver function tests. Four further courses of plasmapheresis were administered to control FT4, with improvement in other biochemical markers, subsequent



resolution of seizure and recovery of consciousness. This allowed a safe window for urgent thyroidectomy four days after plasmapheresis and an uneventful surgery.

#### CONCLUSION

This case highlights the complexities in the management of thyroid storm, and the risk of relapse despite initial biochemical and clinical improvement. A sufficient course of plasmapheresis is essential to allow for urgent thyroidectomy.

### EP\_A088

#### ATRIAL FLUTTER IN HYPERTHYROIDISM: ACHIEVING EARLY RHYTHM CONTROL

<https://doi.org/10.15605/jafes.038.S2.106>

**M. Razi Zulkufli,<sup>1</sup> H.K.R. Subbarao,<sup>1</sup> Mohd Syafiq MS,<sup>1</sup> Salbiah S,<sup>1</sup> Rafizi Mohamed Rus<sup>2</sup>**

<sup>1</sup>94 Hospital Angkatan Tentera, Kem Terendak Malacca, Malaysia

<sup>2</sup>Hospital Angkatan Tentera Tuanku Mizan, Kuala Lumpur, Malaysia

#### INTRODUCTION

Atrial arrhythmia is a common manifestation of cardiac complications of hyperthyroidism. However, most literature focus on the incidence and management of atrial fibrillation rather than atrial flutter. It also suggests postponement of cardioversion until the fourth month of maintaining a euthyroid state, as more than half of cases revert spontaneously to sinus rhythm and atrial fibrillation may recur with thyrotoxicosis. Here we present a case of atrial flutter with early rhythm control with electrical cardioversion without subsequent recurrence.

#### CASE

A 29-year-old male presented with a two-day history of fever and recurrent episodes of palpitations. Upon arrival, findings showed BP 110/70, temperature 38°C, and typical counterclockwise atrial flutter with variable block and HR 130 bpm on ECG. Results revealed low TSH (<0.01 mIU/L) and elevated FT4 (90 pmol/L). He was treated as Graves' thyrotoxicosis precipitated by viral fever. Treatment included carbimazole 30 mg OD, rate control with propranolol 40 mg TDS and supportive care. Echocardiogram showed EF 44% with dilated RA, RV and LA. In view of evidence of cardiomyopathy, transoesophageal echocardiogram and elective cardioversion was performed a week after discharge. Rhythm was successfully cardioverted back to sinus rhythm. He remains in sinus rhythm with improvement in cardiac function four weeks after cardioversion.

#### CONCLUSION

In general, the management of atrial flutter is slightly different from atrial fibrillation, as the former may be treated with immediate rhythm control using electrical cardioversion. Despite the thyrotoxic state, earlier rhythm control is better for cases of atrial flutter in order to prevent development or worsening of thyrotoxic cardiomyopathy.

### EP\_A089

#### PERSISTENT VOMITING AS THE PRESENTATION OF THYROTOXICOSIS: A CASE REPORT

<https://doi.org/10.15605/jafes.038.S2.107>

**Chee Keong Seow and Chin Voon Tong**

*Hospital Melaka, Malaysia*

#### INTRODUCTION

Thyrotoxicosis may have many different presentations at diagnosis. We present a case of thyrotoxicosis with the presentation of only recurrent vomiting in pregnancy.

#### CASE

The patient's medical records were traced and reviewed.

A 41-year-old Malay female, G4P2 with one miscarriage, with underlying type 2 DM initially presented during pregnancy with recurrent admissions for vomiting since the first trimester. She was admitted and treated for hyperemesis gravidarum and urinary tract infection at 12 and 14 weeks gestation. She was readmitted at 28 weeks for recurrent vomiting and reduced oral intake one week prior to admission. She denied having conventional symptoms of thyrotoxicosis. She did not have any family history of thyroid disorder. Examination findings revealed a small goitre with no fine tremors or thyroid eye signs, BP within normal range and HR 100 to 107. Clinically, she had mild dehydration. Multiple investigations including serum calcium, ketone, amylase and brain MRI to look for the cause of persistent vomiting were normal. During her third admission, thyroid tests were done for evaluation of tachycardia. Results showed elevated FT4 (66 pmol/L), suppressed TSH (0.01mIU/L), negative thyroid antibodies and no significant abnormality on neck ultrasonography. She was started on oral carbimazole 20 mg OD and oral propranolol 20 mg BD. Vomiting was resolved thereafter. She delivered via emergency lower caesarean section at 31 weeks for abnormal cardiotocography and foetal intrauterine growth restriction.

#### CONCLUSION

Recurrent vomiting in pregnancy is a rare presentation for thyrotoxicosis. This should not be missed in clinical practice to prevent adverse maternal and foetal outcomes.



## EP\_A090

### REFRACTORY HYPOTHYROIDISM POST-CHOLECYSTECTOMY SUCCESSFULLY TREATED WITH SOFTGEL CAPSULE THYROXINE

<https://doi.org/10.15605/jafes.038.S2.108>

**Seetha Devi Subramanian, Gerard Jason Mathews,  
Teh When Yee, Nor Shaffinaz Yusoff Azmi Merican,  
Noor Rafhati Adyani Abdullah, Shartiyah Ismail**  
*Hospital Sultanah Bahiyah, Malaysia*

#### INTRODUCTION

Refractory hypothyroidism has been increasingly identified globally and its management can be challenging. Primary hypothyroidism is considered refractory when there is persistent elevation of TSH despite escalating doses of levothyroxine >1.9 µg/kg/day. Physicians should rule out non-compliance and pursue further evaluation to identify aetiologies for increased dose requirements.

#### CASE

We present a case of a 44-year-old female with Hashimoto's thyroiditis well-replaced with levothyroxine 100 µg/day (1.6 µg/kg/day). After cholecystectomy, her TSH was persistently high despite increasing levothyroxine to 500 µg/day, good compliance and no concurrent drug interference. She developed progressive hypothyroid symptoms with elevated TSH levels >100 mIU/L. Thyroxine absorption test confirmed poor enteral absorption. Extensive evaluation failed to reveal any evidence of malabsorption where her esophagogastroduodenoscopy finding shows mild antral erosion. Further tests excluded *H. pylori* infection, coeliac disease and exocrine pancreatic insufficiency. She was hospitalized multiple times for severe symptomatic hypothyroidism and responded well with intravenous thyroxine. After extensive diagnostic measures, she was started on levothyroxine 300 µg/day in soft gel capsules. Her TSH and FT4 normalized following 8 weeks of treatment.

#### CONCLUSION

Various gastrointestinal disorders that lead to malabsorption or loss of intestinal secretions may result in higher requirements of levothyroxine. Our case highlights the malabsorption of oral levothyroxine in tablets after cholecystectomy. Hypothesized causes include intestinal malabsorption of levothyroxine due to reduction in bile salts after cholecystectomy and altered intestinal microbiota. An empirical switch to soft gel capsule formulation may resolve this treatment-refractory issue. This formulation has been shown to have the most consistent dissolution pattern, resulting in a more reliable bioavailability than the tablet form.

## EP\_A091

### INCREASED LEVOTHYROXINE REQUIREMENT IN A PATIENT WITH NEPHROTIC SYNDROME

<https://doi.org/10.15605/jafes.038.S2.109>

**Chong Yee Chua and Azraai Nasruddin**  
*Hospital Putrajaya, Putrajaya, Malaysia*

#### INTRODUCTION/BACKGROUND

In hypothyroid patients, there are no studies that exemplify the need for levothyroxine adjustment in patients with coexisting nephrotic syndrome.

#### CASE

This case report highlights the degree of levothyroxine adjustment that may be required.

A 36-year-old Malay male with post-radioiodine hypothyroidism presented in October 2022 with bilateral lower limb swelling, abdominal distention and a 10-kg weight gain over the preceding 3 months. He received RAI twice (October 2020 and February 2021) for relapsed Graves' disease. He had been on a levothyroxine replacement dose of 700 µg/week (1.12 µg/kg/day). Tests revealed low albumin (16 g/L), elevated urine protein:creatinine index (PCI) (341 mg/mmol), elevated TSH (148 mU/L), normal T4 (11 pmol/L) and significant hypercholesterolaemia. Following nephrology consultation and renal biopsy showing minimal change disease, the diagnosis of nephrotic syndrome was made. Nephrotic syndrome has been rarely reported in association with Graves' disease. Reports show membranous glomerulonephritis rather than minimal change disease. In nephrotic syndrome, there is increased permeability of the glomerular basement membrane to large molecules. Thyroxine replacement was deemed inadequate as a consequence of thyroid-binding globulin wasting. Levothyroxine dose was increased to 1150 mcg/week (1.93 µg/kg/day) initially. He had good clinical response to high-dose steroid, and this was gradually tapered over several months. At the time of publication (May 2023), his urine PCI improved to 68.47 mg/mmol. Prednisolone requirement had been reduced to 10 mg/day, along with levothyroxine dose at 850 µg/wk (1.4 µg/kg/day).

#### CONCLUSION

This case highlights the importance of recognising the increased levothyroxine requirement in patients with nephrotic syndrome. Although rare, the association between autoimmune thyroid disease and nephrotic syndrome should be recognised.



## Basic Science Oral Presentation

### OP\_B001

#### DECREASED PTX3 DNA METHYLATION LEVELS ARE ASSOCIATED WITH DIABETIC NEPHROPATHY IN MALE PATIENTS

<https://doi.org/10.15605/jafes.038.S2.110>

Norhashimah Abu Seman,<sup>1</sup> Wan Nazaimoon Wan Mohamud,<sup>1</sup> Harvest F. Gu<sup>2</sup>

<sup>1</sup>Endocrine and Metabolic Unit, Institute for Medical Research, National Institutes of Health Malaysia, Ministry of Health, Shah Alam, Selangor, Malaysia

<sup>2</sup>School of Basic Medicine and Clinical Pharmacy, China Pharmaceutical University, Nanjing, China

#### INTRODUCTION

Inflammation is an established mechanism of diabetic nephropathy (DN). Pentraxin 3 (PTX3) has been suggested to play an important role in inflammation. Epigenetic mechanisms, as well as transcription and translation, have an impact on gene expression. Hypermethylation of gene promoter regions may result in transcriptional silencing. The epigenetic regulation of PTX3 gene expression in relation to diabetic nephropathy (DN) has not been studied. We aimed to determine the DNA methylation levels of the PTX3 gene in the Malay population with T2D and DN.

#### METHODOLOGY

We performed a case-control study involving a total of 27 non-diabetic control (NDC) subjects, 109 subjects with T2D and 43 subjects with DN. Epigenetic analysis of five CpG sites in the PTX3 gene promoter was performed using bisulfite pyrosequencing technology. Plasma PTX3 levels were measured using an enzyme-linked immunosorbent assay.

#### RESULT

DNA methylation levels of the PTX3 gene were gradually decreased in patients with T2D and DN, both in males and females compared to their NDC counterparts. Total mean values of the PTX3 DNA methylation levels were significantly decreased in male patients with DN (5.53%) and T2D (6.41%) compared to NDC subjects (7.00%) ( $p=0.001$ ). Lower levels of DNA methylation at the PTX3 gene promoter were associated with higher levels of PTX3 protein in patients with DN and T2D compared to NDC subjects. However, no significant difference was observed.

#### CONCLUSION

Our results showed that hypomethylation of PTX3 gene was associated with T2D and DN in Malay males. The result was supported by the association of the DNA methylation and plasma levels of the PTX3 gene among patients with T2D and DN.



## OP\_B002

### ASSOCIATION OF THADA, LHCGR, DENND1A, CYP17A1, AND FSHR GENE POLYMORPHISMS IN INFERTILE MALAY FEMALES WITH PCOS

<https://doi.org/10.15605/jafes.038.S2.111>

**Mariam Ahmed Abdelbadie Mohamed,<sup>1</sup> Habibah Abdul Hamid,<sup>2</sup> Ling King Hwa<sup>3</sup>**

<sup>1</sup>Faculty of Medicine and Health Sciences Universiti Putra Malaysia

<sup>2</sup>Department of Obstetrics and Gynecology, Universiti Putra Malaysia

<sup>3</sup>Medical Genetics Unit, Universiti Putra Malaysia

#### INTRODUCTION

Polycystic ovary syndrome (PCOS) is the most common endocrinopathy in reproductive-aged women, affecting 5-20% of females. There is a wide heterogeneity and complexity in clinical manifestations and metabolic complications. Therefore, several genes and environmental factors are implicated in the pathogenesis of this disease. Genome-wide association studies (GWAS) identified several susceptible loci with substantial ethnic variations. Our study aimed to investigate the association of *THADA*, *LHCGR*, *DENND1A*, *CYP17A1*, and *FSHR* polymorphisms in Malay patients with PCOS and infertility.

#### METHODOLOGY

Sixty patients with PCOS and infertility (case group) and 70 infertile females due to other abnormalities (control group) were recruited from infertility clinics at HPUPM, Serdang, Kajang, and Putrajaya hospitals. Clinical data and biochemical results were collected and analysed. High-resolution melting analysis followed by sequencing were used for SNPs (single nucleotide polymorphisms) detection in case and control groups.

#### RESULT

Weight and the LH, FSH, D21 progesterone, and testosterone levels were significantly elevated in patients with PCOS compared to the control group.

#### CONCLUSION

The study suggests that SNPs in *DENND1A* gene (rs10818854, rs2479106 and rs10986105), *THADA* (rs13429458), *LHCGR* (rs13405728), *FSHR* (rs6165, rs6166) and *CYP17A1* (rs743572) are associated with PCOS in infertile Malay females.



## Basic Science Physical Poster Presentation

**PP\_B001**

### DIABETIC AUTOANTIBODY TESTING IN MALAYSIA: TIME FOR A PARADIGM CHANGE

<https://doi.org/10.15605/jafes.038.S2.112>

Saraswathy Apparow,<sup>1</sup> Ker Yang Chua,<sup>2</sup> Poi Giok Lim,<sup>2</sup> Vengketeswara Rao Seetharaman,<sup>3</sup> Shamharini Nagaratnam,<sup>4</sup> Janet Yeow Hua Hong<sup>5</sup>

<sup>1</sup>Endocrine Unit, Institute of Medical Research, Kuala Lumpur, Malaysia

<sup>2</sup>Department of Paediatrics, Hospital Tunku Azizah, Kuala Lumpur, Malaysia

<sup>3</sup>District Health Clinic, Hulu Selangor, Malaysia

<sup>4</sup>Department of Medicine, Hospital Putrajaya, Putrajaya, Malaysia

<sup>5</sup>Department of Paediatrics, Hospital Putrajaya, Putrajaya, Malaysia

#### INTRODUCTION

The positivity of at least one pancreatic islet cells autoantibodies is a marker for diagnosis of type 1 diabetes mellitus (T1DM) and latent autoimmune diabetes of adults (LADA). The Endocrine Lab at the Institute of Medical Research (IMR) offers diabetes autoantibodies testing for all government hospitals and health clinics in Malaysia. This includes islet cell cytoplasmic autoantibodies (ICA), anti-glutamic acid decarboxylase 65 antibodies (anti-GAD65) and anti-insulinoma associated protein-2 (anti-IA2) as 3-panel testing and Insulin autoantibodies (IAA) tested on immunoassay platform.

#### METHODOLOGY

A retrospective study was conducted on the diabetes autoantibodies requests from 1 January 2021 until 31 March 2023 and the data was obtained from the laboratory information system in IMR.

#### RESULT

A total of 5903 patients with diabetes had autoantibodies testing and 1221 (20.6%) patients demonstrated at least one positive autoantibody (ICA/ anti-GAD65/ anti IA2). However, only 347 (5.9%) patients tested positive for all 4 autoantibodies (ICA, GAD65, anti IA2 and IAA). Thirty-one of 87 (35.6%) patients demonstrated IAA positivity with negative 3 autoantibodies (ICA, GAD65, anti IA2) panel testing. After excluding 22 patients with possible insulin exposure (unknown or confirmed), there were still 9/65 (13.8%) with only IAA-positive and negative 3 autoantibodies panel who were insulin naïve patients. Cohen's kappa statistical analysis was performed to test concordance between current 3-panel test (ICA, antiGAD65 and anti-IA2) and testing all 4 autoantibodies as panel. There was substantial agreement between both combinations,  $\kappa=0.73$ , (95% CI, 0.64 to 0.82). Alternatively, testing the combination of IAA, anti-IA2 and anti-GAD65 against all 4 autoantibodies showed perfect agreement,  $\kappa=1$  (95%CI, 1 to 1).

#### CONCLUSION

The current 3 autoantibodies testing panel could miss between 13.8% to 35.6% patients who showed IAA positivity and 3 panel autoantibodies negativity. Ideally, testing for all 4 autoantibodies may be considered.



## Basic Science E-Poster Presentation

### EP\_B001

#### **NIRMATRELVIR/RITONAVIR-INDUCED HYPONATREMIA PRESENTING WITH SIADH AND GASTROINTESTINAL LOSS: A CASE REPORT**

<https://doi.org/10.15605/jafes.038.S2.113>

**Reemarachna P, Suprhamanyam E, Subashini R**  
*Department of Internal Medicine, Hospital Kuala Lumpur, Malaysia*

#### **INTRODUCTION/BACKGROUND**

Nirmatrelvir/ritonavir (Paxlovid™) is an antiviral used to treat mild to moderate COVID-19 infection. Hyponatremia in COVID-19 has been documented in several case reports but none related to treatment with nirmatrelvir/ritonavir to date.

#### **CASE**

A 75-year-old female with diabetes mellitus, hypertension and bronchial asthma was treated as COVID-19 Category 2b with symptoms of fever, diarrhoea and poor oral intake. Serum sodium on admission was 138 mmol/L. She was given nirmatrelvir/ritonavir and intravenous drip due to ongoing gastrointestinal losses. Her symptoms resolved in the next two days. On day 7 of illness, she started having new-onset diarrhoea. Repeat Na was 112 mmol/L. Further hydration led to declining Na levels until she became symptomatic at 105 mmol/L. Her paired sample results suggested SIADH, with serum osmolality 228 mOsm/kg, urine osmolality 233 mOsm/kg and urine Na 84 mmol/L despite ongoing gastrointestinal losses and clinical signs of hypovolemia. Nirmatrelvir/ritonavir was already discontinued. She was treated with hypertonic 3% saline until her symptoms improved. Her diarrhoea resolved, and her Na levels normalized with fluid restriction and oral salt treatment.

#### **CONCLUSION**

Nirmatrelvir/ritonavir has been reported to cause elevated transaminases, hypertension and diarrhoea, apart from its known drug-drug interactions. This case highlights the importance of SIADH as one of the possible adverse effects of this new drug which is now widely used for the management of COVID-19. It is important for clinicians to be vigilant about drug-induced SIADH when investigating the cause of hyponatremia in patients with COVID-19.

### EP\_B002

#### **INHIBITION OF LIPID ACCUMULATION AND UPREGULATION OF BROWNING GENES BY SIRT1 ACTIVATION IN 3T3-L1 CELLS**

<https://doi.org/10.15605/jafes.038.S2.114>

**Siti Sarah Hamzah,<sup>1,2</sup> Liyana Ahmad Zamri,<sup>1</sup> Norhashimah Abu Seman,<sup>2</sup> Shazana Rifham Abdullah<sup>1</sup>**

<sup>1</sup>*Institute for Medical Research (IMR), National Institutes of Health (NIH)*

<sup>2</sup>*Persiaran Setia Murni, Setia Alam, Selangor, Malaysia*

#### **INTRODUCTION**

Obesity is the cause of over 4 million deaths each year according to the Global Burden of Disease study. It is characterized by an increase in adipocyte number and size, making adipogenesis an important target in the prevention and management of obesity. A possible approach is to induce adipose cells into becoming thermogenesis-competent, such as brown or beige adipose cells. In this study, the effect of activating Sirtuin1 (Sirt1) in 3T3-L1 and its role in promoting the browning of white adipose cells was investigated.

#### **METHODOLOGY**

White pre-adipocyte cell lines 3T3-L1 were treated with Sirt1 activator (SRT1720) 2.5 mM, Sirt1 inhibitor (EX527) 10 mM or rosiglitazone (positive control for adipogenesis) 50 mM throughout ten days of adipogenic differentiation period. The effect of these treatments was assessed by western blotting, oil red O lipid staining and real-time PCR.

#### **RESULTS**

Inducing Sirt1 activity affected intracellular lipid accumulation. This was based on the observation of lesser accumulation of lipid in Sirt1-activated cells stained with oil red O. In contrast, when Sirt1 activity was attenuated by Sirt1-specific inhibitor, lipid production increased. Further investigation showed that the expression of genes critical for brown adipose tissue regulation, such as PGC1a and Cidea, were found to be elevated when Sirt1 activity was induced.

#### **CONCLUSION**

This work shows that targeting Sirt1 activity in white adipose cells would instigate an underlying molecular network that modulates the adipogenesis process during cell differentiation by producing less lipid. It also promotes the cells to differentiate into brown-like adipose cells that



have better thermogenic capability. This can serve as a target for further investigation for therapeutic intervention in obesity.

## EP\_B003

### CENTRAL DIABETES INSIPIDUS WITH COVID-19 PNEUMONIA: A CASE REPORT

<https://doi.org/10.15605/jafes.038.S2.115>

**Suprhamanyam E, Subashini R, Leong CL**

*Department of Internal Medicine, Hospital Kuala Lumpur, Malaysia*

#### INTRODUCTION

Although COVID-19 is well-known for its respiratory manifestations, extrapulmonary presentations such as cardiac arrhythmias, acute coronary syndrome, thrombosis, neurologic and ocular illnesses have also been reported. The mechanism of extrapulmonary complications of COVID-19 involves both the direct effects of SARS-CoV-2 via ACE2 receptors and indirect mechanisms associated with dysregulated host immune response. Apart from the respiratory system, ACE2 receptors are widely expressed in the cardiovascular, gastrointestinal, urogenital and nervous systems, which explains the multisystemic effects seen in COVID-19.

#### CASE

We present a case of COVID-19 pneumonia complicated by central diabetes insipidus.

A 64-year-old female with hypertension, diabetes mellitus and atrial fibrillation presented with fever and vomiting for two days. She was lethargic, with stable vitals and slight tenderness at the right upper quadrant of abdomen. She was initially treated with antibiotics in the emergency unit for ascending cholangitis. Contrast-enhanced abdominal CT showed cholelithiasis with no intraabdominal collections. COVID-19 GeneXpert tested positive. Chest radiography showed right lower zone opacities. On the ninth day of admission, she had polyuria (6000 mL in 24 hours). Test results showed serum Na 141 mmol/L, serum osmolarity 300 mOsm/kg, urine osmolarity 89 mOsm/kg and urine Na 15 mmol/L, suggestive of diabetes insipidus. She responded well to subcutaneous desmopressin, which reduced urine output to 15 to 30 mL/hour and improved results of her paired samples. While pituitary tests were normal, MRI revealed absence of T1 hyperintensity in the posterior pituitary, supporting the diagnosis of central DI. She required regular desmopressin doses for up to 3 weeks. Her polyuria resolved in her subsequent admission 4 months later for heart failure.

#### CONCLUSION

This case highlights self-limited diabetes insipidus as one of the extrapulmonary manifestations of COVID-19.

## EP\_B004

### IMPACT OF COVID-19 ON THE INCIDENCE OF NEWLY DIAGNOSED TYPE 1 DIABETES MELLITUS: A SINGLE-CENTRE EXPERIENCE

<https://doi.org/10.15605/jafes.038.S2.116>

**Amira Yasmin Mohamed Zaini, Syarifah Nursyazana Syed Ridzuan, Alexis Anandas Lordudass, Azriyanti Anuar Zaini, Nurshadia Samingan**

*Paediatric Endocrine Unit, Department of Paediatrics, University Malaya Medical Centre, Department of Paediatrics, Faculty of Medicine, University Malaya*

#### INTRODUCTION

Recent studies suggest the increasing occurrence of newly diagnosed type 1 diabetes mellitus during the COVID-19 pandemic. It is postulated that the COVID-19 virus triggers a cascade of autoimmune reactions leading to the development of antibodies against beta cells of the pancreas. This study investigates the incidence of newly diagnosed T1DM in a Malaysian tertiary centre during the COVID-19 era in comparison to the same duration prior to it.

#### METHODOLOGY

This is a single-centre retrospective cross-sectional study among newly diagnosed T1DM patients. Patients aged between one year to less than 18 years old, who were referred to the Paediatric Endocrine Unit of the University Malaya Medical Centre from September 2017 to August 2022 were included in this study. Data including age, gender, anthropometric measurements, diabetic ketoacidosis occurrence, biochemical results and COVID-19 status for the past three months were obtained.

#### RESULTS

Fifty-seven patients who fulfilled the criteria of T1DM were included. Thirty-two patients (56%) were diagnosed during the COVID-19 era. Forty-four patients (77%) presented with DKA. There is no difference in the incidence of DKA and the severity status between these two periods, (77% versus 76.7%,  $p=0.902$ ; and 51.9% versus 53.3%,  $p=0.546$ , respectively. Although not statistically significant, more patients needed pediatric ICU admission (13 versus 9), with lower pH at presentation during the COVID-19 era (7.05 versus 7.12). More than a third (37.5%) needed intubation ( $p=0.019$ ). Recovery was also longer (48 hours versus 36 hours).



## CONCLUSION

Despite the absence of a significant statistical difference, more patients presented with more severe DKA with longer recovery during the COVID-19 pandemic. A larger multi-centre study is needed to evaluate the magnitude of the impact of COVID-19.

## EP\_B005

### DOES THE INCIDENCE OF DIABETIC KETOACIDOSIS IN PATIENTS WITH TYPE 1 DIABETES MELLITUS DIFFER DURING COVID-19 PANDEMIC?

<https://doi.org/10.15605/jafes.038.S2.117>

Syarifah Nursyazana Syed Ridzuan,<sup>1</sup> Amira Yasmin Mohamed Zaini,<sup>2</sup> Alexis Anandas Lordudass,<sup>2</sup> Azriyanti Anuar Zaini,<sup>2</sup> Nurshadia Samingan<sup>2</sup>

<sup>1</sup>Paediatric Endocrine Unit, Department of Paediatrics, University Malaya Medical Centre, Malaysia

<sup>2</sup>Department of Paediatrics, Faculty of Medicine, Universiti Malaya, Malaysia

## INTRODUCTION

Recent studies have observed increased numbers of newly diagnosed type 1 diabetes patients and higher incidence of diabetic ketoacidosis in T1DM patients during the COVID-19 pandemic. The care of non-COVID-19 patients was compromised due to the tremendous burden of managing critical cases of COVID-19 patients. However, this finding is not consistent. This study compares the incidence of DKA and its severity during the pandemic with the similar timing prior to it.

## METHODOLOGY

This is a retrospective cross-sectional study on all of patients who were either newly diagnosed or pre-existing patients with T1DM aged one to 18 years old treated at University Malaya Medical Centre for DKA. from September 2017 until August 2022. Data on demographics, first DKA presentation, recurrence, severity, pediatric ICU admission, duration of recovery, COVID-19 status, duration from symptoms to presentation, and biochemical values were obtained.

## RESULT

A total of 96 DKA cases were reported from September 2017 until August 2022. An equal number of DKA cases (48) was seen in each period. Fifty patients (69%) were newly diagnosed. Recurrent DKA occurred more during the COVID-19 period (27 versus 21). More patients presented with severe DKA during the pandemic (24 versus 19). Although not statistically significant, newly diagnosed T1DM presented with more severe DKA with lower pH

(7.05 versus 7.12,  $p=0.417$ ) and took longer to recover compared to the pre-pandemic period (48 versus 36 hours,  $p=0.150$ ). Three newly diagnosed patients were COVID-19 positive with COVID-19 Category 2b and presented in moderate to severe DKA.

## CONCLUSION

There was no difference in the number and severity of DKA cases during the pre-pandemic and COVID-19 pandemic period. A larger-scale study is needed to analyse the impact of COVID-19 on the incidence and severity of DKA.

## EP\_B006

### INSULIN ANTIBODY MEASUREMENTS: SHEDDING LIGHT ON HIRATA'S DISEASE

<https://doi.org/10.15605/jafes.038.S2.118>

Saraswathy Apparow,<sup>1</sup> Chin Voon Tong,<sup>2</sup> Chee Koon Low,<sup>3</sup> Hui Chin Wong,<sup>3</sup> Sy Liang Yong<sup>3</sup>

<sup>1</sup>Endocrine Unit, Institute for Medical Research, Kuala Lumpur, Malaysia

<sup>2</sup>Endocrine Unit, Department of Medicine, Hospital Melaka, Malaysia

<sup>3</sup>Endocrine Unit, Department of Medicine, Hospital Tengku Ampuan Rahimah, Klang, Malaysia

## INTRODUCTION

The Endocrine Society Clinical Practice Guideline recommends measurement of insulin autoantibodies (IAA) upon confirmation of endogenous hyperinsulinism. The differential diagnosis of endogenous hyperinsulinism include insulinoma, post-bariatric hypoglycaemia, nesidioblastosis and insulin autoimmune syndrome (IAS). IAS, also known as Hirata's disease, is a rare immune-mediated disorder characterised by hyperinsulinaemic hypoglycaemic episodes. It is increasingly being recognized in Malaysia because of accessibility to IAA testing.

## CASE

We describe two cases of newly diagnosed IAS with varied clinical presentations and treatment approaches. The first patient is a 57-year-old male with Graves' disease who experienced severe and recurrent hypoglycaemia during fasting and postprandial states. The second patient is a 56-year-old female with hypertension and bronchial asthma who developed recurrent hypoglycaemia despite cessation of insulin therapy following the treatment for severe refractory diabetic ketoacidosis.

Laboratory findings for both patients showed elevated serum insulin and C-peptide during the hypoglycaemic event, with insulin/C-peptide ratio  $>1$ . Pancreatic antibodies were negative. Serum insulin autoantibodies measured on



chemiluminescent immunoassay revealed remarkably high titres in both cases. Triggering factors were identifiable in both cases: in the first, exposure to carbimazole; and in the second patient: exposure to pantoprazole, amlodipine, metoprolol, perindopril and amoxicillin clavulanate. The first patient improved with dietary modification and alpha-glucosidase inhibitor. The second patient was treated with steroids.

#### CONCLUSION

Our case series highlighted the importance of measuring insulin antibody titer after confirming endogenous hyperinsulinism. High insulin concentration along with insulin/C-peptide molar ratio  $>1$  should raise the clinical suspicion of IAS. Early recognition of this syndrome can avoid the need for laborious and costly investigation of presumed insulinoma with appropriate therapeutic approach.

#### KEYWORDS

endogenous hyperinsulinism, hypoglycaemia, insulin autoantibodies

## EP\_B007

### HYPERGLYCAEMIA-INDUCED MOVEMENT DISORDER

<https://doi.org/10.15605/jafes.038.S2.119>

**Nor Afifah Iberahim, Sanihah Abdul Halim, Wan Izani Wan Mahmood**

*Internal Medicine Department, Hospital Universiti Sains Malaysia*

#### INTRODUCTION/BACKGROUND

Dyskinetic syndromes are one of the rarer initial presentations of undiagnosed diabetes. We report a case of hyperglycaemia-induced movement disorder in a newly diagnosed diabetes mellitus patient.

#### CASE

A 27-year-old male with no known medical illness presented to our centre in September 2019 with involuntary movement of left facial and left upper limb for five days, along with lethargy and persistent vomiting. Initial tests showed serum glucose 17.7 mmol/L, serum ketone 2.2 mmol/L and metabolic acidosis on blood gas, indicating non-ketotic hyperglycaemia. Serum osmolality was 292 with deranged renal profile. His HbA1c level was 16.8%. He had a strong family history of DM. In the ward, he was treated with insulin infusion and adequate hydration. Risperidone tablet was started for new-onset chorea. Cranial CT during this initial admission showed hyperdense areas at both basal ganglia and thalamus, suggesting changes

that correlated with his hyperglycaemic state. He presented again in November 2019 for lower gastrointestinal bleed secondary to rectal ulcer. During this admission, his involuntary movement progressed into hemidystonia of the left facial and left upper limb. He was then started on Baclofen tablet. Blood glucose was controlled during this admission. Brain MRI showed hyperintensity T1-weighted sequence, heterogenous hypointensity on T2-weighted and FLAIR sequences at bilateral caudate nuclei, bilateral lentiform nuclei and posterior thalamus. There were no other focal lesions to suggest other causes of the movement disorder.

Metabolic derangement in the absence of focal vascular lesions at the basal ganglia area are the common cause of hemiballism and hemichorea as was observed in our patient.

#### CONCLUSION

The case illustrates that abnormal movement may persist despite adequate glycaemic control. Appropriate medical therapy should be initiated to control the complication.



## Paediatrics Oral Presentation

### OP\_P001

#### NEW ONSET DIABETES BEFORE AND DURING THE COVID-19 PANDEMIC AND FACTORS ASSOCIATED WITH DIABETIC KETOACIDOSIS IN SELECTED TERTIARY HOSPITALS

<https://doi.org/10.15605/jafes.038.S2.120>

Fatin Fariyah Wan Ahmad Nasir,<sup>1</sup> Muhammad Yazid Jalaludin,<sup>2</sup> Azriyanti Anuar Zaini,<sup>2</sup> Nalini Selveindra,<sup>3</sup> Poi Giok Lim,<sup>4</sup> Yee Lin Lee<sup>1</sup>

<sup>1</sup>Department of Paediatrics, Faculty of Medicine and Health Sciences, Universiti Putra Malaysia

<sup>2</sup>Department of Paediatrics, Faculty of Medicine, Universiti Malaya, Malaysia

<sup>3</sup>Department of Paediatrics, Hospital Putrajaya, Malaysia

<sup>4</sup>Department of Paediatrics, Hospital Tunku Azizah, Malaysia

#### INTRODUCTION

New onset diabetes mellitus (DM) and diabetic ketoacidosis (DKA) among children have increased worldwide following the COVID-19 pandemic. This study aimed to determine the frequency of new-onset DM and DKA during the COVID-19 pandemic as compared to the pre-pandemic period and to determine the factors associated with DKA among children with new onset DM.

#### METHODOLOGY

A cross-sectional retrospective study was conducted at four paediatric endocrine tertiary hospitals in Klang Valley, Selangor among all patients with new-onset diabetes during two-time intervals, 2015 to 2019 (before the pandemic) and 2020 to 2022 (during the pandemic). Data on patients' demographics and clinical characteristics were collected.

#### RESULT

Three hundred eighty-eight patients with new onset DM were included. Both new-onset DM and DKA showed increased relative frequencies after the onset of the pandemic (17.2% in 2021, 14.1% in 2020, 11.2% in 2019, 12.8% in 2018) and (18.5% in 2021, 16.2% in 2020, 9.3% in 2019, 10.3% in 2018) respectively. The relative frequencies of patients with new-onset type 1 diabetes mellitus (T1DM) increased during the pandemic, but type 2 diabetes mellitus (T2DM) cases declined. Median BMI was found to be higher among patients with new-onset T2DM during the pandemic compared to those who developed T2DM pre-pandemic ( $p=0.04$ ). Patients with T2DM also had a shorter duration of symptoms ( $p=0.019$ ) and lower HbA1c ( $p=0.008$ ) during the pandemic. On multiple logistic regression, a younger age, lower BMI, T1DM, higher blood glucose and higher HbA1c were factors significantly associated with new-onset DKA.

#### CONCLUSION

There was an increase in Type 1 DM and DKA following the pandemic. Awareness of at-risk groups and associated clinical characteristics enables early detection of new-onset DKA and DM. Early surveillance of T2DM among persons with higher BMI should be emphasised. Public health education and campaigns for lifestyle modification, infection control precautions and COVID-19 vaccination should be actively implemented.



## OP\_P002

### PAEDIATRIC GRAVES' DISEASE AND FACTORS ASSOCIATED WITH REMISSION IN A SINGLE TERTIARY CENTRE

<https://doi.org/10.15605/jafes.038.S2.121>

**Shi Hui Saw, Nalini M Selveindra, Janet Yeow Hua Hong**

*Hospital Putrajaya, Putrajaya, Malaysia*

#### INTRODUCTION

Graves' disease (GD) accounts for 10-15% of all childhood thyroid disorders. It is a multifactorial disease with complex interactions among genetic, environmental, and endogenous factors.

#### METHODOLOGY

Sixty-eight children and adolescents under the age of 18 who were diagnosed with GD at Hospital Putrajaya were included in this cross-sectional review. Diagnostic criteria for GD were supporting clinical features, raised thyroxine (FT4), suppressed thyrotropin stimulating hormone (TSH) and positive thyrotropin receptor antibodies (TRAb). Remission was defined as the preservation of euthyroid status for more than a year following discontinuation of the antithyroid drug (ATD). Patients who achieved remission were compared to those with persistent disease to identify positive predictive factors.

#### RESULT

This study included 53 (77.9%) females and 15 (22.1%) males. The mean age at diagnosis was  $8.77 \pm 2.7$  years old. Kaplan-Meier survival analysis showed cumulative remission rate was 6.5%, 16.2%, 26.4% and 46.9% with a duration of ATD treatment at 2 years, 4 years, 6 years, and 8 years respectively. Patients in the remission group were more likely to be female ( $p=0.029$ ) and had a family history of autoimmune thyroid disorder ( $p=0.004$ ). The duration of ATD treatment in this cohort was  $3.8 \pm 2.5$  years. Adverse events (AE) were reported in 14.7% of the patients. Elevated liver enzyme was the most common AE ( $n=6$ ), followed by hematologic abnormalities ( $n=3$ ) and rash ( $n=1$ ). All were minor AE which resolved without sequelae.

#### CONCLUSION

Gender and family history of autoimmune thyroid disorder can be used to stratify patients in terms of the likelihood of achieving remission. The cumulative remission rate increased with the duration of ATD use. These local population-based data and evidence can be helpful during the counselling of patients for treatment planning.



## OP\_P003

### **SOCIETAL JUDGEMENTS OF PHYSICAL APPEARANCE IN RELATION TO FOOD BEHAVIOUR, PHYSICAL ACTIVITIES, SMOKING AND INTERNET USE IN ADOLESCENTS SEEN IN THE PAEDIATRIC OBESITY AND DIABETES CLINIC**

<https://doi.org/10.15605/jafes.038.S2.122>

**Balqis Nur Sabrina Affendi,<sup>1</sup> Hakima Muhamad Ali,<sup>1</sup> Nur Aimi Nabilah Zanalabidin,<sup>1</sup> Azriyanti Anuar Zaini<sup>1,2</sup>**

<sup>1</sup>Department of Paediatrics Faculty of Medicine, University Malaya, Kuala Lumpur, Malaysia

<sup>2</sup>Paediatric Endocrine and Diabetes Unit, University Malaya Medical Centre, Kuala Lumpur, Malaysia

#### **INTRODUCTION**

The prevalence of childhood obesity and diabetes among adolescents in Malaysia is a concern. It affects the quality of life, and exposes to societal judgements related to physical appearance, which affects mental well-being. This study seeks to contribute valuable insights into the experiences of adolescents with obesity and diabetes and their implications for physical and mental health.

#### **METHODOLOGY**

Patients aged 12 to 18 years old attending the obesity and diabetes clinic at UMMC were invited to participate. A questionnaire-based assessment was offered. The questionnaire was adapted with consent from the NHMS 2017 committee. The study was approved by UMMC ethics. We analysed 4 components which include food behaviour, physical activities, smoking and internet usage.

#### **RESULT**

A total of 43 patients responded to the questionnaire. Forty-four percent (n=19) were males with 7.0% (n=3) recruited from the obesity clinic and 93.0% (n=40) from the diabetes clinic. Their mean age was 14.8 years old. Twelve (28%) reported that they were unhappy with their physical appearance. Amongst them, 79% (n=24) considered weight to be a very important aspect of their life. Eighteen (42%) reported consuming fruits less than once/day, while 20.9% (n=9) reported the same for vegetables. Additionally, 30% (n=15) did not drink milk at least once/day, while 4.6% (n=2) admitted to consuming carbonated drinks more than once/day. Eleven (25.6%) confessed to indulging in fast food more than twice/week. One respondent reported using e-cigarettes/vape more than three days/month and started vaping at the age of 14 years old. No one currently smokes. Seventeen (39.5%) reported infrequent physical activities less than once/week, while 52% (n=22) were driven to school. The majority 93% (n=40) were dependent on electronics, including smartphones, computers, and iPads, in their daily activities.

#### **CONCLUSION**

We anticipate that children with obesity and diabetes will encounter challenges with their mental and physical well-being. Understanding and addressing their daily behaviours and risk associated with lifestyle may be useful to prevent potential physical and mental health concerns.



## OP\_P004

### **MENTAL HEALTH CONCERNS IN RELATION TO BULLYING, FEELINGS AND FRIENDSHIP, EMOTIONAL DISTURBANCES IN HOME AND SCHOOL, AMONG ADOLESCENTS SEEN IN THE PAEDIATRIC OBESITY AND DIABETES CLINIC**

<https://doi.org/10.15605/jafes.038.S2.123>

**Hakima Muhamad Ali,<sup>1</sup> Balqis Nur Sabrina Affendi,<sup>1</sup> Nur Aimi Nabilah Zanalabidin,<sup>1</sup> Azriyanti Anuar Zaini<sup>1,2</sup>**

<sup>1</sup>*Department of Paediatrics Faculty of Medicine, University Malaya, Kuala Lumpur, Malaysia,*

<sup>2</sup>*Paediatric Endocrine and Diabetes Unit, University Malaya Medical Centre, Kuala Lumpur, Malaysia*

#### **INTRODUCTION**

The issues surrounding childhood obesity and chronic illnesses such as diabetes, in relation to their physical appearance, and mental well-being are always a concern. This study explores potential insights into the experiences of adolescents with obesity and diabetes and their implications towards physical and mental health.

#### **METHODOLOGY**

Patients aged 12 to 18 years old attending the obesity and diabetes clinic at UMMC were invited to participate in the study. A questionnaire-based assessment was offered. The questionnaire was adapted with consent from the NHMS 2017 committee. The study was approved by UMMC ethics committee. We analysed 4 components which includes bullying, feelings and friendship, home and school experiences, as well as emotional disturbances. A scoring system was adapted to stratify risks.

#### **RESULT**

A total of 43 patients responded to the questionnaire. Forty-four percent (n=19) were males with 7.0% (n=3) recruited from the obesity clinic and 93.0% (n=40) from the diabetes clinic. Their mean age was 14.8 years old. The responses were grouped according to either high risk or low risk depending on the scores. None reported bullying. One in four (n=10) scored high risk when questioned about their feelings (which includes suicidal ideation) and friendship. Thirteen (30.2%) scored high risk for experiences at home and school (which explores school absences and parental support). Three (7%) expressed high-risk score for emotional component which includes anxiety, agitation, motivation, and self-worth.

#### **CONCLUSION**

Childhood obesity and chronic illness like diabetes confer a higher risk for psychological disturbances. Addressing their risks and mental health concerns should be prioritised to prevent further deterioration. These study findings highlight the issues and suggest that further liaison with other medical professionals e.g., child psychologist, is warranted.



## OP\_P005

### OUTCOME OF CONGENITAL HYPERINSULINISM (CHI): A SINGLE-CENTRE EXPERIENCE

<https://doi.org/10.15605/jafes.038.S2.124>

**Mazidah Noordin,<sup>1,2</sup> Hajime Miyagi,<sup>1</sup> Mizuho Igarashi,<sup>1</sup> Takemoto Kashima,<sup>1</sup> Akiko Fujioka,<sup>1</sup> Nagisa Ujita,<sup>1</sup> Keisuke Yoshii,<sup>1</sup> Yasuhiro Naiki,<sup>1</sup> Reiko Horikawa<sup>1</sup>**

<sup>1</sup>Division of Endocrinology, National Centre for Child Health & Development, Tokyo, Japan

<sup>2</sup>Paediatric Department, Faculty of Medicine, Universiti Teknologi MARA (UiTM), Sungai Buloh, Malaysia

#### INTRODUCTION

Congenital hyperinsulinism (CHI) is a condition that results in recurrent hypoglycaemia due to inappropriate insulin secretion. This condition is generally rare; however, it is still a common cause of persistent hypoglycaemia beyond infancy.

#### METHODOLOGY

This is a cross-sectional study of the patients attending the paediatric endocrinology unit in the National Centre for Child Health & Development (NCCHD), Tokyo, Japan from March 2022 to March 2023. Our study aimed to analyse the characteristics of the CHI patients who are in remission as compared to those who still have persistent disease.

#### RESULT

There was a total of 39 patients, with 23(59%) patients who were male. The mean age was 10.9 (2.3 – 31.75) years old and the majority of the patients were of Japanese ethnicity, 37 (94.9%). At the time of study, 28 (71.8%) patients still had persistent CHI, while the remaining were in remission.

There was a total of 10 patients who had surgery in our cohort. Among those patients who had surgery, 8 (80%) are already in remission. The majority of the CHI patients, 29 (74%), were managed with medical therapy, and among these, only 3 patients (10.3%) are in remission. The patients who still have persistent disease are still dependent on nutritional and/or medical therapy. Among the patients who still have persistent disease, 23 patients (82.1%) require monotherapy while the remaining 5 patients (17.9%) require 2 or more therapy to maintain the blood glucose within control. Long-term complications were observed within our cohort including diabetes and dysregulated glycemia, pancreatic insufficiency and neurological effects.

#### CONCLUSION

In conclusion, CHI is a challenging disease to manage, not only for the paediatric endocrinologists, but most importantly, for the patients and their families. This condition not only requires multidisciplinary management, but also close follow-up for long-term complications.



## Paediatrics Physical Poster Presentation

### PP\_P001

#### PREVALENCE AND RISK FACTORS OF ENDOCRINE DISORDER IN CHILDHOOD BRAIN TUMOR SURVIVORS: A SINGLE-CENTRE STUDY

<https://doi.org/10.15605/jafes.038.S2.125>

**Nurul Wahidah Ramezan,<sup>1,2</sup> Suhaimi Hussain,<sup>1,2</sup> Norsarwany Mohamad,<sup>1,2</sup> Najib Majdi Yaacob<sup>3</sup>**

<sup>1</sup>Department of Paediatric, School of Medical Sciences, Universiti Sains Malaysia, Kelantan, Malaysia.

<sup>2</sup>Hospital Universiti Sains Malaysia, Health Campus, Universiti Sains Malaysia, Kelantan, Malaysia

<sup>3</sup>Department of Biostatistics and Research Methodology, School of Medical Science, Universiti Sains Malaysia, Universiti Sains Malaysia, Kelantan, Malaysia

#### INTRODUCTION

Brain tumours are the most common type of paediatric solid organ tumors and the second most common childhood malignancy after leukaemia, in which it contributes to 21% of all paediatric malignancies. The survival outcomes in childhood brain tumours have improved significantly due to the advances in diagnosis and treatment, as well as the understanding of the disease aetiology. With improved survival rate, there has been a rising concern regarding the sequelae of childhood brain tumour survivors. We aimed to study the prevalence and risk factors of endocrine disorder in childhood brain tumour survivors.

#### METHODOLOGY

This study took place at Hospital USM and recruited 124 childhood brain tumour survivors from January 2002 till December 2017. We included brain tumour survivors aged 18 years or younger with either stable disease or in remission and survived for at least 2 years after diagnosis. Data collected included demographic data (age at diagnosis, gender, ethnicity, socioeconomic status), clinical clues for endocrine disorders, anthropometrics (weight, height, mid-parental height), pubertal stage according to Tanner staging, tumour-related characteristics, treatment modalities and endocrine laboratory measurements at diagnosis and during follow up. Logistic regression was applied to evaluate risk factors of endocrine disorders in childhood brain tumour survivors.

#### RESULT

The prevalence of endocrine disorders in childhood brain tumour survivors was 62.1%. The risk factors were high BMI [adjusted odds ratio (AOR) 1.29, 95% Confidence interval (CI): 1.12 to 1.5], high risk site [AOR 7.15, 95% CI: 1.41 to 36.3] and chemotherapy [AOR 0.18, 95% CI: 0.05 to 0.62].

#### CONCLUSION

The prevalence of endocrine disorders in childhood brain tumour survivors in our centre was 62.1%. The significant risk factors were high BMI, tumour location (suprasellar and intrasellar) and chemotherapy.

#### KEYWORDS

endocrine disorder, childhood brain tumour survivors, risk factors



## PP\_P002

### CLINICAL CHARACTERISTICS AND OUTCOMES OF PEDIATRIC TYPE 2 DIABETES IN HOSPITAL PUTRAJAYA

<https://doi.org/10.15605/jafes.038.S2.126>

**Siti Salamah Binti Mohd Idris, Janet Hong Yeow Hua, Nalini M. Selveindran**

*Paediatric Endocrine Unit, Paediatric Department, Hospital Putrajaya, Putrajaya, Malaysia*

#### INTRODUCTION

In Malaysia, the estimated prevalence of children and adolescents with type 2 Diabetes mellitus (T2DM) was 17.7% of all paediatric patients with diabetes (DiCARE Annual Report 2006-2007). We report the characteristics and outcomes of patients with type 2 DM in Hospital Putrajaya.

#### METHODOLOGY

Data retrieved from the electronic database were reviewed. All patients diagnosed with type 2 diabetes attending the Paediatric Clinic Hospital Putrajaya from January 2012 until December 2022 were included. Data were presented as mean, median and percentages.

#### RESULT

There was a total of 41 patients reviewed. The mean age of presentation was  $11 \pm 1.9$  years old with a median diabetes duration of  $4.3 \pm 2.1$  years. A majority (68.3%) presented between 10 to < 15 years old, predominantly females (63.4%) and of Malay ethnicity (65.8%). All patients had negative diabetes autoantibodies, 82.9% were obese and 92.6% had positive family history of diabetes. At presentation, 14.6% of patients had diabetic ketoacidosis (DKA). The mean fasting blood sugar was  $11.3 \pm 3.8$  mmol/L and the mean HbA1c was  $11.4 \pm 3.2\%$ . Diabetes-related complications namely hypertension, dyslipidaemia, microalbuminuria and retinopathy were observed in 24.4%, 17.5%, 17.1% and 4.9% of patients, respectively. Dyslipidaemia was detected at  $2.4 \pm 2.6$  years, retinopathy at  $2.5 \pm 0.7$ , hypertension at  $3 \pm 2.3$  years and microalbuminuria was detected at  $3.5 \pm 1.3$  years from onset of DM.

There were 80.6% of patients who required insulin at initial presentations and 74.3% still needed combination therapy with metformin later on. At the end of the follow-up, only 12.1% of patients achieved HbA1c < 6.5%, while 51.2% had HbA1c > 10%.

#### CONCLUSION

Paediatric Type 2 diabetes patients had poor glycaemic control with early development of complications. A multi-disciplinary approach with an individualised management plan is needed to prevent the progression of the disease.



## PP\_P003

### IMPACT OF THE COVID-19 PANDEMIC ON GLYCAEMIC CONTROL, BODY MASS INDEX AND LIFESTYLE CHANGES IN CHILDREN AND ADOLESCENT PATIENTS WITH DIABETES MELLITUS IN THE STATE OF NEGERI SEMBILAN

<https://doi.org/10.15605/jafes.038.S2.127>

**Mastura Ibrahim**

*Paediatric Department, Hospital Tuanku Jaafar Seremban, Malaysia*

#### INTRODUCTION

This study aimed to look for the impact of the COVID-19 pandemic on glycaemic control, body mass index (BMI) and lifestyle changes in children and adolescent Patients with Diabetes Mellitus (DM) in the State of Negeri Sembilan

#### METHODOLOGY

This cross-sectional study involved 3 main specialist hospitals in Negeri Sembilan including HTJS (Hospital Tuanku Jaafar Seremban), HTAN (Hospital Tuanku Ampuan Najihah Kuala Pilah) and HPD (Hospital Port Dickson). The included patients had follow-ups more than 3 months prior to the lockdown and had at least one physical clinic follow-up after the lockdown. All the records were retrieved and the patients' glycaemic control parameters such as HbA1c and their BMI before and during the COVID-19 pandemic MCO. Guided interviews were conducted regarding their changes in lifestyle before and during COVID-19 MCO.

#### RESULT

A total of 52 patients were enrolled in this study, 41 patients (78.8%) had Type 1 DM and 11 patients (21.2%) had Type 2 DM. The age of participants was 4 to 18 years old (mean SD 14.10 ± 2.6). The mean difference in HbA1c, before and during MCO, was 0.117 (95% CI:-0.519, 0.744;  $p=0.79$ ). BMI change before and during COVID-19 MCO was statistically significant at 0.383 (95% CI:0.204,0.561);  $p<0.001$ . Lifestyle changes had no significant inter-category difference in the association with the HbA1c and BMI.

#### CONCLUSION

Lifestyle changes, had no significant inter-category difference in the association with the HbA1c and BMI changes using linear regression in Children and Adolescent Patients with Diabetes Mellitus in the State of Negeri Sembilan.



## PP\_P004

### REVIEW OF HYPOPHOSPHATAEMIC RICKETS IN HOSPITAL PUTRAJAYA

<https://doi.org/10.15605/jafes.038.S2.128>

Shi Hui Saw,<sup>1</sup> Nalini Selveindran,<sup>1</sup> Tzer Hwu Ting,<sup>2</sup> Karuppiah Thilakavathy,<sup>3</sup> Janet Yeow Hua Hong<sup>1</sup>

<sup>1</sup>Department of Paediatrics, Hospital Putrajaya, Putrajaya, Malaysia

<sup>2</sup>Department of Paediatrics, Faculty of Medicine and Health Sciences, University Putra Malaysia (UPM)

<sup>3</sup>Department of Biomedical Science, Faculty of Medicine & Health Sciences, University Putra Malaysia (UPM), Malaysia

#### INTRODUCTION

Hypophosphataemic rickets (HR) is a rare cause of rickets characterized by renal phosphate wasting. X-linked dominant rickets (XLH) is the most common type of HR caused by inactivating mutations of PHEX.

#### METHODOLOGY

We reviewed medical records of 6 patients from the paediatric endocrine clinic in Hospital Putrajaya who presented with clinical and biochemical features of HR. DNA samples were sent for whole exome sequencing (WES) with the collaboration of Faculty of Medicine and Health Sciences, UPM.

#### RESULT

There were 2 male and 4 female patients from 5 families included in this review. The median age at onset and diagnosis was 1.75 years old (1-4 years) and 3.7 years old (1.8-5.9 years), respectively. The presenting features included bowed legs (100%), wrist swelling (100%), gait disturbance (50%) and limb pain (33%).

Laboratory findings at diagnosis included mean serum calcium and phosphate levels which were  $2.34 \pm 0.07$  mmol/L and  $0.72 \pm 0.06$  mmol/L, respectively. The mean alkaline phosphatase level was  $591 \pm 169$  IU/L. The serum  $25(\text{OH})\text{D}_3$  was  $66.43 \pm 24.3$  nmol/L (normal: 50-250 nmol/L). The serum iPTH was  $4.85 \pm 2.5$  pmol/L (normal: 1.3-9.3 pmol/L). Tubular reabsorption of phosphate was available for 2 patients which were 72 and 77% (normal: >85%). All patients had normal urine calcium/creatinine ratio for age. XLH was confirmed by WES in 4 patients from 3 families. 2 patients had no pathogenic mutation detected. All the patients were treated with multi-dose oral phosphate and active vitamin D analogue. However, the majority developed progressive bowing of lower limbs, in which half of the patients required corrective osteotomy. At the latest follow-up, they had lower mean height SDS ( $-3.2 \pm 0.63$ ) and higher mean iPTH levels ( $13 \pm 7.19$ ) compared to their initial presentation.

#### CONCLUSION

XLH is the most common cause of HR in this hospital. The challenges associated with a multi-dose oral phosphate regimen include worsening height SDS and iPTH levels. New treatment approaches may help to mitigate these negative effects.



## PP\_P005

### SUCCESSFUL TRANSITION CARE FOR ADOLESCENT AND YOUNG ADULTS WITH DIABETES: A SINGLE-CENTRE EXPERIENCE AND REPORT

<https://doi.org/10.15605/jafes.038.S2.129>

Qiao Yun Lee,<sup>1</sup> Noor Azleen Ambak,<sup>1</sup> Alexander Tong Boon Tan,<sup>2</sup> Luqman Ibrahim,<sup>3</sup> Azriyanti Anuar Zaini<sup>1,4</sup>

<sup>1</sup>Paediatric Department, University Malaya Medical Centre, Kuala Lumpur, Malaysia

<sup>2</sup>Sunway Medical Centre, Subang Jaya, Selangor, Malaysia

<sup>3</sup>Regency Specialist Hospital, Masai, Johor, Malaysia

<sup>4</sup>Department of Paediatric, Faculty of Medicine, University Malaya, Kuala Lumpur, Malaysia

#### INTRODUCTION

Planned and coordinated transition to adult services should be provided in all centres managing adolescents with diabetes. A variety of transition intervention programs can be implemented to ensure higher clinic attendance and lower disengagement rates. This audit aims to identify success in a single-centre transition clinic amongst adolescents with diabetes mellitus (DM).

#### METHODOLOGY

All adolescents transferred between January 2017-December 2022 were included in the analysis. Patients were either transferred out or referred to the transition clinic in the same centre. They were monitored for at least 2 years before transferring to the general adult diabetes clinic. Success transfer rate is defined as being seen at least twice in the first year. Success transition care is defined when the patient completed 2 years follow-up. Pre- and post-transfer HbA1c were compared.

#### RESULT

A total of 47 patients were transferred during the study period. Thirteen patients requested to be transferred to a different hospital. Two were enrolled in a local research project. Four patients were planned for transition care but did not turn up. Of the 28 patients who presented to the transition clinic, 71% (n=20) were Type 1 DM and 29% (n=8) were Type 2 DM. Twelve (43%) were female and their median age at transfer was  $19.2 \pm 2.2$  years old. The success transfer rate was 100% and successful transition care was 77% (n=23). Five patients requested to be transferred due to either studying/ working elsewhere (n=3) and the remaining 2 had financial constraints. There were no differences in the pre- and post-transfer A1c. Median pretransfer A1c was  $9.07 \pm 2.33\%$  and median post transfer A1c was  $9 \pm 2.4\%$  respectively.

#### CONCLUSION

Preparing the idea of transition early, collaboration between the paediatric and adult services within the same centre and identifying point persons in the service helped with the outcome and success rate of transition services in this centre.



## Paediatrics E-Poster Presentation

### EP\_P001

#### THYROID HORMONE RESISTANCE SYNDROME (THR): A CASE REPORT

<https://doi.org/10.15605/jafes.038.S2.130>

**W Mohd Hilmi bin W. Omar, Jia Cheng Ong, Suhaimi Hussain**

*Endocrine Unit, Paediatrics Dept, Hospital Universiti Sains Malaysia*

#### INTRODUCTION/BACKGROUND

Thyroid hormone resistance syndrome (THR) is a rare condition caused by defects in either one of the two thyroid hormone receptors which leads to tissue unresponsiveness to circulating thyroid hormones. The presentations vary depending on which receptor is affected.

#### CASE

A 3-year-old female who had a couple of admissions for tonsillitis was incidentally found to have failure to thrive, global developmental delay, intermittent tachycardia, and family history of goitre. She had soft dysmorphism, a baseline heart rate of 80 per min, no obvious goitre, and no skeletal dysplasia. Systemic examinations were unremarkable. Serial thyroid function tests (TFT) showed persistently high thyroid stimulating hormone (TSH) and FT4. TFT samples were sent to different biochemical laboratories and the results were similar. Autoantibody screening such as thyroid receptor antibodies, antithyroglobulin antibodies, and thyroid peroxidase antibodies were all negative. Her liver function, creatine kinase and lipid profile were normal. Thyroid ultrasound showed homogeneous enlargement of both thyroid lobes with increased vascularity within. MRI of the brain and the pituitary gland was normal which ruled out a TSHoma. Both her and her father have mutation R243W in the thyroid hormone beta gene thus confirming the diagnosis of THR-beta.

#### CONCLUSION

Diagnosis of THR was challenging in view of its rarity, wide spectrum of presentations, and lack of awareness among physicians.

### EP\_P002

#### A RARE CASE OF NEONATAL DIABETES WITH INSULIN GENE (INS) MUTATION: A CASE REPORT

<https://doi.org/10.15605/jafes.038.S2.131>

**Michael Pook Sow Zhung, L Alexis Anand, Arini Nuran Idris, Lim Poi Giok**

*Paediatric Endocrine Unit, Department of Paediatrics, Hospital Tunku Azizah Kuala Lumpur, Malaysia*

#### INTRODUCTION/BACKGROUND

Neonatal Diabetes (NDM) is a rare condition that affects 1 in every 100,000-500,000 livebirths. Certain individuals with genetic mutations in NDM can be managed with sulfonylurea therapy while for others, insulin remains the mainstay of treatment. We report an infant having NDM with insulin gene (INS) mutation.

#### CASE

We report a small for gestational age (SGA) female born at 39 weeks via spontaneous vaginal delivery (SVD) with birth weight of 2 kg. Her parents are non-consanguineous.

She presented with fever, respiratory distress, and vomiting at 3 weeks old. She was dehydrated with 11% weight-loss. Blood investigations revealed metabolic acidosis with pH of 6.92, serum bicarbonate of 5.7 with high anion gap of 25 mmol/L, hyperglycaemia with blood sugar level of 66.15 mmol/L, and blood ketone of 2.7 mmol/L. She had concurrent inappropriately low c-peptide of 54 pmol/L (367-1467) and negative insulin autoantibodies. The genetic result showed heterozygous (p.Pro9Arg) variant in INS gene.

She was treated with intravenous fluid therapy and insulin infusion. After 1 week of insulin infusion, she was converted to basal-bolus regimen with subcutaneous regular insulin and NPH insulin which was technically challenging due to difficulty in dilution and marked glycaemic variability. At 2 months old, she was placed on continuous subcutaneous insulin infusion (Medtronic Minimed 780) with continuous glucose monitoring system.

The onset of NDM is less than 6 months-old and genetic testing is indicated for patients diagnosed before 9 months-old. Typical presentations are SGA, dehydration and hyperglycaemia. Bolus subcutaneous insulin is not ideal in NDM because of frequent feeding, limited subcutaneous fat, reduced insulin requirement, and huge fluctuations in glycaemic levels regardless of the type of insulin used. The successful use of insulin pump has been described in NDM.



## CONCLUSION

Genetic mutations in children with NDM are common. Insulin remains the mainstay of therapy in INS-gene mutation. Genetic testing should be done to facilitate management.

## EP\_P003

### ZOLEDRONIC ACID THERAPY FOR MONO-OSTOTIC LANGERHANS CELL HISTIOCYTOSIS: A CASE REPORT

<https://doi.org/10.15605/jafes.038.S2.132>

Pian Pian Tee<sup>1,2</sup> and Wei Li Cindy Ho<sup>1</sup>

<sup>1</sup>*Khoo Teck Puat – National University Children's Medical Institute, National University Health System, Singapore*

<sup>2</sup>*Hospital Putrajaya, Putrajaya, Malaysia*

#### INTRODUCTION/BACKGROUND

Langerhans cell histiocytosis (LCH) is a rare disease. It can affect any organ in the body but is primarily characterized by osteolytic bony lesions. Skeletal LCH may range from a unifocal, self-limiting, asymptomatic lesion to severe, painful, destructive lesions that are prone to pathological fractures. Treatment decisions are individualized according to location, size, surgical accessibility, and functional impairment. Hence, there is no standard of care at the moment. Zoledronic acid (ZA) has been used in some neoplastic bone conditions to slow down the progression and reduce the bone pain.

#### CASE

We report a 6-year-old male with unifocal bony LCH at the left tibia who responded well to ZA. He presented at 4 years old with limping and was subsequently not ambulatory due to severe pain. He had a tender swollen left shin without skin changes.

X-ray showed a poorly defined 4.7 x 1.1 cm permeative lytic lesion in the medullary cavity of the midshaft of the left tibia with endosteal thinning. Subsequent MRI and isotope bone scans (Tc-99m MDP) confirmed a suspicious primary bone malignant lesion. A bone biopsy showed a neoplastic proliferation of histiocytoid cells with strong diffuse positivity for CD 1a, which was in keeping with LCH.

This confirmed a symptomatic mono-ostotic LCH with significant cortical destruction that was at risk of fracture. ZA was initiated after careful evaluation. His pain completely resolved with a return of function six weeks after the first dose of ZA. He received 4 doses of ZA in total and demonstrated radiographic evidence of regression and remained in remission.

## CONCLUSION

This case demonstrates the potential role of ZA therapy as the first line treatment for mono-ostotic LCH stabilisation and symptomatic control.

## EP\_P004

### CASE REPORT: MUCOLIPIDOSIS BONE DISEASE RESEMBLING NEONATAL RICKETS

<https://doi.org/10.15605/jafes.038.S2.133>

Jian Ann Boo, Sze Teik Teoh, Eric Boon Kuang Ang

*Hospital Sultanah Bahiyah, Malaysia*

#### INTRODUCTION/BACKGROUND

Mucopolipidosis II (I-cell disease) is a rare genetic metabolic disorder of lysosomal metabolism with a combined frequency of 1:422,000, that is characterized by coarse facial features, disproportionate short stature, hyperplastic gums, organomegaly, and retarded psychomotor development. These physical changes however require time to develop and are not apparent at birth. Opportunistically, neonates with I-cell disease are diagnosed after revealing typical spine changes in skeletal survey. Unlike nutritional rickets, their underlying cause and course of the bone disease are different.

#### CASE

We report a premature 34-week-old male with a birth weight of 1.6 kg. He was born in an ambulance while his mother was being transferred from a district hospital. He required cardiopulmonary resuscitation at birth and was admitted to the neonatal intensive care unit where he stayed for another 6 months due to respiratory reason. During his 1<sup>st</sup> to 4<sup>th</sup> months of life, he had markedly raised ALP level (>1000 IU/L), together with severe hyperparathyroidism that gradually resolved with time. He had radiographic changes resembling rickets which persisted and progressed to "chronic osteitis fibrosa cystica". His serum calcium, phosphate, and 25(OH)D<sub>3</sub> levels had always been normal. He never had a fracture. His diagnosis was later confirmed by marked elevation of plasma b-hexosaminidase, b-mannosidase and a-mannosidase. He was discharged home with tracheostomy and CPAP. He continues to survive at 11 months old by the time of this report.

#### CONCLUSION

Mucopolipidosis osteodystrophy could resemble nutritional rickets during the neonatal period but it is not related to either deficient vitamin D or minerals. Failure to respond to conventional treatment (vitamin D and calcium or phosphate), should prompt for a search for other causes of increased bone turnover. In I-cell disease,



hyperparathyroidism often remits but bone disease progresses. Bisphosphonate therapy such as pamidronic acid has been described in those with recurrent fractures in later life.

## EP\_P005

### CASE REPORT: VAN WYK-GRUMBACH SYNDROME: HYPOTHYROIDISM PRESENTING AS PRECOCIOUS PUBERTY

<https://doi.org/10.15605/jafes.038.S2.134>

**Hazirah Ahmad**

*Hospital Sultanah Bahiyah, Malaysia*

#### INTRODUCTION/BACKGROUND

Acquired causes of hypothyroidism such as Hashimoto's thyroiditis is mostly insidious and often goes undetected, unless there is concomitant thyroid gland enlargement or profound hypothyroid symptoms. Precocious puberty in girls is a rare cause of acquired hypothyroidism.

#### CASE

We report an 8 year-3-month-old female of Chinese-Indian descent, who presented with precocious puberty (bilateral breast budding, axillary hair, and pubic hair) about 6 months prior, with the mother's concern of poor learning in school. There were no other symptoms of puberty such as vaginal discharge or growth acceleration. She was adopted at 6 months old, thus, there is uncertainty about her biological family history. Her height was at the 25<sup>th</sup> centile and weight at 75<sup>th</sup> centile. She had a single café-au-lait spot at the right thigh, with Tanner stage 2 breasts, axillary hair, and pubic hair. She also had mild scoliosis with no other skeletal deformities. She had no thyroid gland enlargement but her facial expression was dull. Her blood investigations revealed pre-pubertal levels of gonadotrophins with undetectable estradiol, normal prolactin and negative b-HCG screen. Her thyroid function revealed markedly increased TSH (>100mIU/L) with severely low fT4 (<5.4 pmol/L). Her thyroid peroxidase antibody (anti-TPO) level was 131 IU/ml (<35). Ultrasound of the thyroid showed features in keeping with autoimmune thyroiditis with incidental thyroglossal duct cyst. Upon further questioning, the mother did recall prominent neck swelling since the past 2 years. Following L-thyroxine initiation, her thyroid function normalized and she showed significant improvement in height (she grew 10 cm/year) with progression of puberty. Her last bone age was 10 years old (CA: 9 year and 6 months).

#### CONCLUSION

Van Wyk-Grumbach syndrome is a relatively uncommon cause of pseudo-precocious puberty that often skips detection. Thyroid assessment is recommended in a girl presenting with precocious puberty, even in the absence of goiter. Timely diagnosis and treatment with L-thyroxine normalizes thyroid function and significantly improves linear growth.

## EP\_P006

### CASE REPORT: EXOGENOUS CUSHING SYNDROME IN A GROWING CHILD FOLLOWING CHRONIC TOPICAL STEROIDS FOR FAMILIAL PSORIASIS

<https://doi.org/10.15605/jafes.038.S2.135>

**Tsae Yun Tan**

*Hospital Sultanah Bahiyah, Malaysia*

#### INTRODUCTION/BACKGROUND

Cushing syndrome is relatively uncommon in young children but exogenous Cushing syndrome is increasingly seen due to both prescribed and surreptitious intake of steroids.

#### CASE

We report a 6 year-10-month-old female, referred from Dermatology for obesity. She had itchy and scaly red plaques about 1 year prior. Both her mother and elder sister had been diagnosed with psoriasis and treated elsewhere. Even without a doctor's advice, she was given over-the-counter topical betamethasone dipropionate by her mother 1 year before consult. The mother applied the steroid generously over the child's whole body including the face and inguinal region twice a day for every flare, which usually occurred around 2 episodes every month. Since then, her daughter gained weight and stopped growing. She had florid Cushingoid features with emotional lability (easily tearing), truncal obesity, thick violaceous purple striae over the trunk, neck, upper, and lower limbs, and extensive erythematous scaly psoriatic plaques (BSA~80%). She was hypertensive with blood pressures ranging from 130-150/88-100 mmHg. She did not have proximal muscle weakness. Her eye assessment was negative for glaucoma or cataract, or hypertensive retinopathy changes. She had a pre-pubertal Tanner stage with no virilisation or hirsutism. She had persistently suppressed 8am cortisol level (<27.6 nmol/L) and low ACTH level (1.10 pmol/L, reference range 1.6-13.9) with normal 17OHP and DHEAS screen. She had borderline HbA1c (5.7%), dyslipidaemia, and non-alcoholic fatty liver disease based on an abdominal ultrasound. Her topical steroids for psoriasis were stepped down and she was initiated on steroid-sparing UV



phototherapy in the ward. Her BP stabilized. She was given physiologic oral hydrocortisone replacement (6 mg/m<sup>2</sup>/day). Six months later, her weight reduced with resumption of linear growth, and improved metabolic control.

#### CONCLUSION

Exogenous Cushing syndrome resulting from topical medications has been described well especially among young infants. Potent topical steroids particularly for young children should ideally be administered with doctor's prescription.

### EP\_P007

#### STEROID-RESPONSIVE ENCEPHALOPATHY ASSOCIATED WITH AUTOIMMUNE THYROIDITIS: THE OUTCOME OF NEUROLOGICAL AND THYROID STATUS

<https://doi.org/10.15605/jafes.038.S2.136>

Jen Ern Tan,<sup>1</sup> Joyce Soo Synn Hong,<sup>2</sup> Sau Wei Wong<sup>1</sup>

<sup>1</sup>Neurology Unit, Department of Paediatrics, Hospital Pakar Kanak-Kanak, Universiti Kebangsaan Malaysia

<sup>2</sup>Endocrinology Unit, Department of Paediatrics, Hospital Pakar Kanak-Kanak, Universiti Kebangsaan Malaysia

#### INTRODUCTION/BACKGROUND

Steroid-Responsive Encephalopathy Associated with Autoimmune Thyroiditis (SREAT), also termed as Hashimoto's Encephalopathy is a neuroendocrine disorder characterized by a triad of subacute onset of encephalopathy, elevated anti-thyroid antibodies, and neurological improvement following steroid therapy. It is a rare but more likely under-diagnosed condition in patients presenting with encephalopathy.

#### CASE

A 7-year-old Chinese female was referred for headache, seizures, and mood changes for 2 months. She was found to have hyperthyroidism when she presented with frequent hunger and weight loss 4 months ago. She was started on carbimazole 2.5 mg twice a day and she became euthyroid clinically and biochemically. She was otherwise a brilliant child with no other medical illness. She had no family history of thyroid or autoimmune disorders. Examination revealed an irritable child with upper motor neuron signs. Her cerebrospinal fluid analysis for viral PCR and neuronal antibodies were negative. Her cranial MRI and EEG were reported as normal. Her thyroid function was normal (TSH 3.65 uIU/mL, T4 8.5 pmol/L). Her thyroid antibody levels were all significantly elevated (thyroid stimulating immunoglobulins 3.1 IU/L, anti-thyroid peroxidase antibodies 731.8 IU/ml, anti-thyroglobulin antibodies 642.9 IU/ml). A diagnosis of SREAT was made. She received

intravenous methylprednisolone 30 mg/kg/day for 5 days followed by a course of prednisolone for a month. She made a complete recovery. She remained clinically and biochemically euthyroid without medication. A year later, her symptoms recurred, and she was treated similarly as her previous presentation. She recovered but had persistent seizures and needed anti-seizure medication. Her seizure frequency was once a month until 4 years later wherein her seizure frequency increased to weekly without other symptoms. She was given a course of oral prednisolone for 3 months. She was seizure-free for 2 months before her seizures resumed monthly. She was also found to have hypothyroidism (TSH 28.69 uIU/ml, T4 6.65 pmol/L) on screening. She was started on L-thyroxine and became euthyroid after 2 months of treatment.

#### CONCLUSION

This case report illustrates that epilepsy is a clinical sequela of SREAT despite being a steroid-responsive condition. Thyroid status does not determine seizure control; hence it reflects an association rather than causation of the encephalopathy.

### EP\_P008

#### TRIPLE-A SYNDROME: A RARE PRESENTATION OF ADRENAL INSUFFICIENCY

<https://doi.org/10.15605/jafes.038.S2.137>

Muhamad Ideris Othman,<sup>1</sup> Song Hai Lim,<sup>1</sup> Janaeni Vethaguru<sup>2</sup>

<sup>1</sup>Department of Paediatrics, Sabah Women and Children Hospital, Kota Kinabalu, Malaysia

<sup>2</sup>Department of Paediatrics, Hospital Duchess of Kent, Sandakan, Malaysia

#### INTRODUCTION/BACKGROUND

Triple-A syndrome or Allgrove syndrome is a rare autosomal recessive congenital disorder. It is characterized by Addisonianism, achalasia and alacrima. It is a progressive disorder that can take years to develop the full-blown clinical picture.

#### CASE

We report 2 individuals with Triple-A syndrome who initially presented with recurrent hypoglycemic seizures at about 4 years old. They also had faltering growth with short stature. Both had significant hyperpigmentation, without ambiguous genitalia or neurological abnormality. Hormonal assay confirmed glucocorticoid deficiency, with sparing of mineralocorticoid involvement. Both were subsequently started on hydrocortisone replacement.



In the subsequent years, both developed new symptoms of recurrent vomiting and dysphagia, suggesting achalasia. Subsequently, patient 2 had barium swallow study done which confirmed an esophageal dysmotility disorder. Retrospectively, both patients were also found to have absent tear production from a very young age, signifying alacrima.

Patient 1 managed to undergo Whole Exome Sequencing (WES) study and a homozygous variant of uncertain significance (VUS) was identified in the AAAS gene (cDNA: NM\_015665.6:c.1087G>A). In view this is the gene of interest that fits into the clinical picture, the mutation was likely pathological.

#### CONCLUSION

High index of suspicion is required to diagnose this rare entity. Unexplained cases of adrenal insufficiency should be carefully evaluated for signs and symptoms of alacrima and achalasia.

### EP\_P009

#### AUTOSOMAL DOMINANT, NON-AUTOIMMUNE, CONGENITAL HYPERTHYROIDISM

<https://doi.org/10.15605/jafes.038.S2.138>

**Vivian Lai How Mun, Janet Hong Yeoh Hua, Nalini M. Selveindran**

*Hospital Putrajaya, Putrajaya, Malaysia*

#### INTRODUCTION/BACKGROUND

Primary non-autoimmune hyperthyroidism is a rare cause of neonatal hyperthyroidism. This results from an activating mutation in the thyrotropin-receptor (TSHR). TSHR is a G-protein coupled receptor and is found primarily in the thyroid gland. It is also present in adipocytes, fibroblasts and bone cells. It can be inherited in an autosomal dominant manner or occur sporadically as a de novo mutation. Affected individuals display a wide phenotype from severe neonatal to mild subclinical hyperthyroidism. The severity of the hyperthyroid symptoms is variable and phenotype differences have been described in subjects harbouring the same mutation.

#### CASE

A 10-month-old female was born late preterm at 36 weeks via spontaneous vertex delivery with birth weight of 2.5 kg. Antenatally, the mother was asymptomatic for hyperthyroidism. There was no family history of thyroid or autoimmune diseases. The baby was referred at birth with deranged cord TSH of 0.05 mIU/L. Repeat thyroid function tests at day 7 of life demonstrated an elevated T4 of 27.6

pmol/L and low TSH of 0.01 mIU/L. She had persistently high free T4, hence, was started on carbimazole at 3 months old. She was also asymptomatic for hyperthyroidism. Her growth parameters were appropriate for age. She does not have dysmorphism. She had normal heart rate, blood pressure, and tone. She did not have a goiter.

Her thyrotropin receptor autoantibodies were negative. Her neck ultrasound revealed a normal thyroid gland with normal vascularity, with no focal thyroid lesion seen. Genetic test revealed a heterozygous pathogenic variant in TSHR NM\_000369.5:c.1891T>G (NP\_000360.2:p.Phe631Val). During the course of follow-up, she was well and remained asymptomatic.

#### CONCLUSION

Although rare, TSHR gene mutation should be considered in an infant who presents with hyperthyroidism with a negative autoimmune screen and a negative maternal history of thyroid disorders. Early diagnosis is important so as to rapidly initiate anti-thyroid therapy and manage the thyrotoxicosis, to potentially avoid an enlarging goiter, and to prevent neurocognitive delays in young children with nonautoimmune hyperthyroidism.

### EP\_P010

#### DIABETIC KETOACIDOSIS WITH MELIOIDOSIS: A CASE REPORT

<https://doi.org/10.15605/jafes.038.S2.139>

**Nur Syafiqah Hamizi,<sup>1,2</sup> Jia Jian Tang,<sup>1,2</sup> Qiao Yun Lee,<sup>1</sup> Mia Tuang Koh,<sup>1</sup> Anna Marie Nathan,<sup>1,2</sup> Siti Zarina Yaakop,<sup>1</sup> Muhammad Yazid Jalaludin,<sup>1,2</sup> Azriyanti Anuar Zaini,<sup>1,2</sup> Nurshadia Samingan<sup>1,2</sup>**

<sup>1</sup>Department of Paediatrics, University Malaya Medical Centre, Kuala Lumpur, Malaysia

<sup>2</sup>Department of Paediatrics, Faculty of Medicine, Universiti Malaya, Kuala Lumpur, Malaysia

#### INTRODUCTION/BACKGROUND

Paediatric melioidosis is uncommon yet is associated with high morbidity and mortality in severe disease particularly in immunocompromised patients. Reports of melioidosis in paediatric diabetes are scarce. We present two patients with melioidosis who presented with diabetic ketoacidosis (DKA) in our centre.

#### CASE

Patient A is a 15 year-9-month-old female with underlying type 1 diabetes (T1D). She presented with mild DKA (serum glucose: 25 mmol/L, serum ketone: 3.9 mmol/L venous pH: 7.30, HCO<sub>3</sub><sup>-</sup>: 13 mmol/L) associated with fever and symptoms of upper respiratory tract infection (URTI) for



4 days. She remained febrile despite 2 courses of intravenous (IV) amoxicillin-clavulanic acid and oral erythromycin. A chest radiograph at day 9 of illness showed collapsed consolidation of the left upper lobe of the lung.

She was noted to have hepatosplenomegaly on physical examination at day 12. Abdominal ultrasound revealed multiple well-defined splenic microabscesses. Routine blood and respiratory cultures were negative, but serum IgM titres for melioidosis were positive. She was treated with IV meropenem and oral trimethoprim-sulfamethoxazole.

Patient B is a 12-year-old female who presented with prolonged fever and newly diagnosed DKA (serum glucose: 30.3 mmol/L, serum ketone: 3.5 mmol/L venous pH: 7.24, HCO<sub>3</sub><sup>-</sup>: 12.6 mmol/L). Her fever persisted despite DKA resolution. She developed septic shock needing intensive care admission due to severe pneumonia with bilateral pleural effusion. CT thorax and abdomen showed consolidated changes in the lungs and multiple abscesses in the liver and spleen. Blood cultures grew *Burkholderia pseudomallei* which confirmed melioidosis infection. She was treated with 6 weeks of IV ceftazidime, meropenem and trimethoprim-sulfamethoxazole.

#### CONCLUSION

Prolonged fever in children presenting with DKA must be thoroughly investigated. Melioidosis is uncommon, however, it needs to be ruled out to ensure adequate treatment of patients with immunocompromised status.

## EP\_P011

### HASHIMOTO'S THYROIDITIS WITH SYSTEMIC INVOLVEMENT: A CASE REPORT

<https://doi.org/10.15605/jafes.038.S2.140>

Jia Jian Tang,<sup>1</sup> Qiao Yun Lee,<sup>1</sup> Nur Syafiqah Hamizi,<sup>1,2</sup> Nurshadia Samingan,<sup>1,2</sup> Azriyanti Anuar Zaini,<sup>1,2</sup> Muhammad Yazid Jalaludin<sup>1,2</sup>

<sup>1</sup>Department of Paediatrics, University Malaya Medical Centre, Malaysia

<sup>2</sup>Department of Paediatrics, Faculty of Medicine, University Malaya, Malaysia

#### INTRODUCTION/BACKGROUND

Hashimoto's thyroiditis is the most common cause of acquired primary hypothyroidism in children. It is an autoimmune disease involving cell and antibody-mediated immune processes, leading to progressive fibrosis. Severe hypothyroidism may have variable clinical manifestation mimicking other multiorgan dysfunction.

#### CASE

We report an 8-year-old male who presented to our centre with a 4-month history of intermittent facial and lower limb swelling associated with unintentional weight gain, cold intolerance, easy fatigability, and regression in school performance. There was no family history of thyroid disease or autoimmune disorder. He visited the healthcare clinic 2 weeks prior to presentation for an upper respiratory tract infection however hypothyroid symptoms were not addressed. He was a short male with weight of 29.7 kg (75<sup>th</sup> centile) and height of 119 cm (10<sup>th</sup> centile) with evidence of faltering growth and coarse facies. He has a diffuse goitre measuring 8 x 3 cm (length x width) associated with thyroid acropachy, bilateral pretibial myxoedema and bradyarrhythmia (mean heart rate 56/min). His biochemical results showed a markedly elevated TSH 2233 mIU/L with FT4 2pmol/L, anti TPO >1000 IU/ml and anti-TG antibody 53.7 IU/ml. He was started with oral levothyroxine 25 mcg daily (0.8 mcg/kg/day) and the dose was titrated up slowly to 50 mcg daily (1.7 mcg/kg/day) over 4 weeks. He received one stress dose of intravenous hydrocortisone 100 mg (100 mg/m<sup>2</sup>/dose) on the day of admission due to hypotension upon starting thyroxine. His status of adrenal insufficiency has not been ruled out. There were no other complications of myxoedema coma.

#### CONCLUSION

We report a case of missed hypothyroidism despite frank symptoms and signs. This was the highest TSH reported in our centre and likely in Malaysia. Prolonged untreated Hashimoto's thyroiditis is associated with high morbidity and mortality risk. Initiating treatment must be done cautiously to prevent crisis and complications.



## EP\_P012

### A CASE OF CHILDHOOD ADRENOCORTICAL TUMOR: A TICKING TIME BOMB

<https://doi.org/10.15605/jafes.038.S2.141>

**Sin Toun Loh,<sup>1</sup> Poi Giok Lim,<sup>1</sup> Arini Nuran Idris,<sup>1</sup> Mohd Yusof Abdullah,<sup>2</sup> Mohd Yusran Othman,<sup>2</sup> Kok Hoi Teh,<sup>3</sup> Hui Hui Siah<sup>4</sup>**

<sup>1</sup>Department of Paediatrics, Endocrine Unit, Hospital Tunku Azizah, Malaysia

<sup>2</sup>Department of Paediatric Surgery, Hospital Tunku Azizah, Malaysia

<sup>3</sup>Department of Paediatrics, Hematology and Oncology Unit, Hospital Tunku Azizah, Malaysia

<sup>4</sup>Department of Pathology, Hospital Kuala Lumpur, Malaysia

#### INTRODUCTION/BACKGROUND

Childhood adrenocortical tumours (ACTs) are rare. Majority of children have clinical evidence of hormone hypersecretion at diagnosis which varies from virilization to Cushing's syndrome. Markers for risk stratification in ACTs are not well-defined and differentiating adenomas from carcinomas remain challenging.

#### CASE

We describe a child with adrenocortical tumour presenting with virilization and hypertensive crisis.

A 6-year-old male was initially admitted for status epilepticus attributed to rotavirus acute gastroenteritis. He had hirsutism, pubic hair, penile enlargement, and gynecomastia, which started 2 years ago. His weight and height were at the 50<sup>th</sup> centile. He developed hypertensive crisis requiring five anti-hypertensive agents including parenteral infusion. Blood tests showed high testosterone, renin and aldosterone. 24-hour urinary sample demonstrated hypercortisolism. Magnetic resonance imaging of the upper abdomen showed a left adrenal mass. He underwent complete resection of the solid mass, which measured 83 x 82 x 59 mm and showed no signs of infiltration. The tumour scored 2/9 using the Wieneke algorithm, features compatible with adrenocortical adenoma. Post-resection, his blood pressure normalized with a single oral anti-hypertensive. He was counselled for adjuvant chemotherapy, but the family opted for watchful management.

#### CONCLUSION

The paucity of data on prognostic factors, disease staging, and treatment hinders the clinician's ability in identifying patients at high risk of relapse even after complete tumour resection. More targeted predictive models for recurrence or malignant risk will be helpful in guiding treatment strategies.

## EP\_P013

### CONGENITAL HYPOTHYROIDISM IN A TWIN MISSED BY NEWBORN SCREENING: A CASE REPORT

<https://doi.org/10.15605/jafes.038.S2.142>

**Shemalatha Kejendaram, Ting Tzer Hwu, Lee Yee Lin**

Department of Pediatrics, Faculty of Medicine and Health Sciences, Universiti Putra Malaysia

#### INTRODUCTION/BACKGROUND

Thyroid hormone plays a significant role in the development of multiple organ systems especially the brain. Newborn screening program enables early detection and treatment of congenital hypothyroidism (CH) to prevent long-term cognitive and physical impairment. We report a case of a twin with CH missed by newborn screening using umbilical cord blood thyroid-stimulating hormone (TSH) in Malaysia.

#### CASE

A 13-year-old Malay female was born at 34 weeks of gestation with a birth weight of 1600 g. Her cord TSH screening was normal at birth (6.54 mIU/L). She is the first twin of monozygotic monoamniotic twins. Her larger twin sister weighed 2470 g at birth and also had normal cord TSH (3.12 mIU/L). The patient was admitted at birth for feeding establishment, nosocomial infection and neonatal jaundice. She presented later at 2 months of age with abdominal distension, constipation and lethargy, and was treated for sepsis. At 5 months of age, she was noted to have faltering growth, developmental delay, and constipation. Her growth parameters were way below the 3<sup>rd</sup> percentile (weight 3400 g, length 53 cm and head circumference of 34 cm) and she also had macroglossia and hypotonia. Thyroid function test (TFT) showed severe primary hypothyroidism (TSH 194 uIU/mL, free T4 <5.15 pmol/L). She was initiated on oral thyroxine 15 mcg/kg/day at 5 months of age and her TFTs normalized within a month of treatment. Ultrasound of the thyroid gland at 3 years of age revealed thyroid gland hypoplasia. Her twin had normal growth and development.

#### CONCLUSION

This case illustrates the need to retest the thyroid function in same-sex twins even when the cord TSH screening is normal. There should also be a high index of suspicion on the diagnosis of congenital hypothyroidism in infants with faltering growth, constipation, or developmental delay.



## EP\_P014

### CHALLENGES OF INITIATING GROWTH HORMONE THERAPY IN TURNER SYNDROME WITH CHIARI MALFORMATION: A FOLLOW UP REPORT

<https://doi.org/10.15605/jafes.038.S2.143>

Amir Hamzah Maju AS,<sup>1,2</sup> Muntari MI,<sup>1</sup> Noordin M,<sup>1,2</sup> Mohd Nor NS<sup>1,2,3</sup>

<sup>1</sup>Department of Paediatric, Hospital Al Sultan Abdullah UiTM, Puncak Alam, Malaysia

<sup>2</sup>Department of Paediatric, Faculty of Medicine, Universiti Teknologi MARA (UiTM), Sungai Buloh, Malaysia

<sup>3</sup>Institute for Pathology, Laboratory and Forensic (I-PPerForM), Universiti Teknologi MARA, Sungai Buloh, Malaysia

#### INTRODUCTION/BACKGROUND

Turner syndrome (TS) associated with congenital central nervous system abnormalities are uncommon. Study on outcome of growth hormone therapy in this group are limited. We present a follow up report on challenges of growth hormone (GH) therapy in our patient with Turner Syndrome (45, XO) and Type I Arnold Chiari Malformation.

#### CASE

NB is a 17-year-old female who was first referred to us for short stature and dysmorphism. Karyotype confirmed 45, XO, hence, TS diagnosis was made. She was pre-pubertal at presentation, with height of 132 cm (-4.98 SDS), and mean parental height of 153 cm. Her bone age was delayed at 12.5 years.

She was planned for GH therapy. Polysomnography (PSG) revealed an incidental finding of central apnoea with Apnoea-Hypopnea Index (AHI) of 22.5/H. This led to a brain MRI which revealed cerebellar tonsils descended 7 mm below the foramen magnum, consistent with Type I Arnold Chiari malformation. A repeat PSG showed significant improvement of her AHI index. Following multidisciplinary discussion, a decision was made for GH therapy.

She was started on GH therapy and the dosage was gradually titrated. After 3 months of GH therapy, her height velocity improved from 2.7 cm/year to 5.2 cm/year. She remained well, however a PSG post-GH therapy revealed worsening apnoea. Family counselling was done, and her parents were not keen to continue with GH therapy.

#### CONCLUSION

TS with Chiari malformation is uncommon. Commencement of GH therapy in this group requires multidisciplinary management. Close surveillance of potential side effects is crucial to avoid potential adverse events.

## EP\_P015

### A CASE OF NON-CLASSICAL CONGENITAL ADRENAL HYPERPLASIA (NCCAH) PRESENTING WITH CENTRAL PRECOCIOUS PUBERTY

<https://doi.org/10.15605/jafes.038.S2.144>

Mazidah Noordin,<sup>1</sup> Abdul Salam Amir Hamzah Maju,<sup>1</sup> Noor Shafina Mohd Nor<sup>1,2</sup>

<sup>1</sup>Department of Paediatrics, Faculty of Medicine, Universiti Teknologi MARA (UiTM), Sungai Buloh, Malaysia

<sup>2</sup>Institute for Pathology, Laboratory and Forensic Medicine (I-PPerForM), Universiti Teknologi MARA (UiTM), Sungai Buloh, Malaysia

#### INTRODUCTION/BACKGROUND

Non-classical congenital adrenal hyperplasia (NCCAH) usually has a late presentation as compared to classical CAH as the presentation is often atypical. Presentation in boys can be asymptomatic through family screening or with clinical presentation such as signs of premature adrenarche and growth spurt.

#### CASE

MFI, a 4 year-4-month-old male was referred to the paediatric endocrine clinic with complaints of body odour for 2 months, associated with pubic hair and acne. He seemed to be taller compared to his peers with a recent height spurt. His parents are not consanguineous with no significant family history. He has facial acne with signs of precocious puberty. He has Tanner II genitalia with stretched penile length of 7 cm, presence of pubic hair, and bilateral testicular volume of 4 ml.

Baseline investigations revealed low cortisol level, elevated 17-hydroxyprogesterone (17OHP) and detectable testosterone levels. Short synacthen test showed low cortisol level, with significantly elevated 17-OHP with a peak of 931 nmol/L. Both sodium and potassium were normal, however, renin was elevated at 166.5 mU/L (normal range 4.2 – 59.7) with aldosterone at a lower range of normal at 155 pmol/L (normal range 102 – 859). LHRH test showed pubertal respond with peak LH at 11.4 IU/L. Bone age was 7 years more advanced than his age, at 11.4 years. Genetic test for CAH panel was not performed due to financial constraint. Diagnosis of NCCAH with central precocious puberty was made and hydrocortisone, fludrocortisone and GnRH analogue were started.

#### CONCLUSION

This case illustrates an unusual presentation of a male patient with NCCAH complicated by central precocious puberty due to androgen excess that has activated the



central pubertal response. Treatment aims to control the CAH as well as suppress puberty with GnRH analogue, with the hope of preserving the patient's final adult height.

## EP\_P016

### A CASE OF AUTOSOMAL DOMINANT OSTEOPETROSIS TYPE 2 WITH A CLCN7 GENE MUTATION

<https://doi.org/10.15605/jafes.038.S2.145>

**Banumathy R, Nalini M Selveindran, Shi-Hui Saw, Noor Arliena Mat Amin, Janet Yeow Hua Hong**

*Department of Paediatric Endocrinology, Hospital Putrajaya, Putrajaya, Malaysia*

#### INTRODUCTION/BACKGROUND

Osteopetrosis encompasses a group of rare metabolic bone diseases characterized by impaired osteoclast activity or development, resulting in high bone mineral density making affected individuals paradoxically prone to fracture. The autosomal dominant adult (benign) form is associated with milder symptoms often appearing in later childhood and adulthood whereas the autosomal recessive infantile (malignant) form has severe presentations appearing in early childhood, and typically fatal if untreated.

The CLCN7 gene plays a pivotal role in the pathogenesis of various forms of osteopetrosis. Disruption of CLCN7 expression results in severe lysosomal storage disorders.

#### CASE

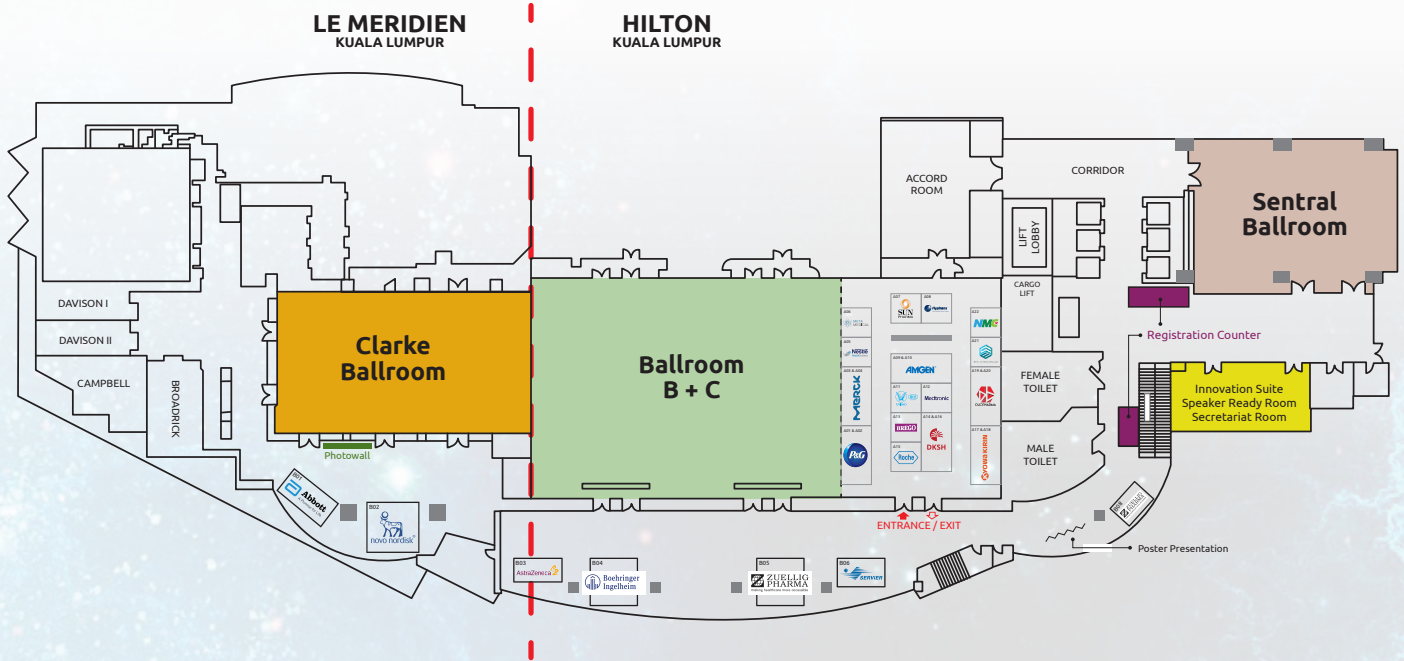
We present a 14-year-old female who was referred to the Paediatric Endocrine clinic, Hospital Putrajaya (Malaysia) for history of recurrent fractures after trivial insult. She had sustained a closed fracture of the left distal end of the tibia/fibula at age 7 years and bilateral distal third tibia/fibula at age 13 years. She also complained of lower back and lower limb pain after exertion. He had normal dentition and mild bowing of both lower limbs, with no organomegaly. Ophthalmology and ENT assessments were normal. There was no remarkable abnormality in serum biochemistry, besides Vitamin D deficiency and elevated aspartate aminotransferase (AST). Plain radiographs showed a generalized increase in bone density. Whole exome sequencing confirmed a heterozygous likely pathogenic variant of the CLCN7 gene (CLCN7 856C>T). There is a history of fracture following trivial insult in a sibling. Genetic testing for the family will be sent in the future. The patient was started on vitamin D supplementation and advised adequate dietary calcium intake.

#### CONCLUSION

In conclusion, we report a patient with osteopetrosis due to a novel mutation of the CLCN7 gene. Management of the less severe forms of osteopetrosis is not so clear as expert guidelines have focused on treatment of the severe infantile forms which require hematopoietic cell transplantation. Scarcity of published studies on osteopetrosis precludes the development of evidence-based guidelines for the management of these patients.



# Floor Plan



A06 	A07 	A08 	A22 
A05 	[Blank]		A21 
A03 & A04 	A09 & A10 		A19 & A20 
A01 & A02 	A11 	A12 	A17 & A18 
	A13 	A14 & A16 	
	A15 		



MEMS ANNUAL CONGRESS  
**MAC 13 2023**

*Thank You*  
for your support

*Diamond Sponsor*



Boehringer  
Ingelheim



ZUELLIG  
PHARMA  
making healthcare more accessible

*Platinum Sponsor*



**Abbott**  
A Promise for Life

AstraZeneca



**DKSH**



*Gold Sponsor*

**KYOWA KIRIN**



ZUELLIG  
PHARMA  
making healthcare more accessible

*Silver Sponsor*

**AMGEN<sup>®</sup> MERCK**

*Trade Exhibitor*

**BREGO**



DUOPHARMA



ETHOS HEALTHCARE



Hyphens  
Asean's Specialty Pharma Company

**Medtronic**



META  
MEDICAL







# AFES 2023

22<sup>ND</sup> ASEAN FEDERATION OF ENDOCRINE SOCIETIES CONGRESS



Save the date

**16-19**  
**November 2023**

[www.afes2023thailand.com](http://www.afes2023thailand.com)



Queen Sirikit National  
Convention Center  
Bangkok, Thailand



[secretariat@afes2023thailand.com](mailto:secretariat@afes2023thailand.com)



[afes2023thailand](https://www.facebook.com/afes2023thailand)





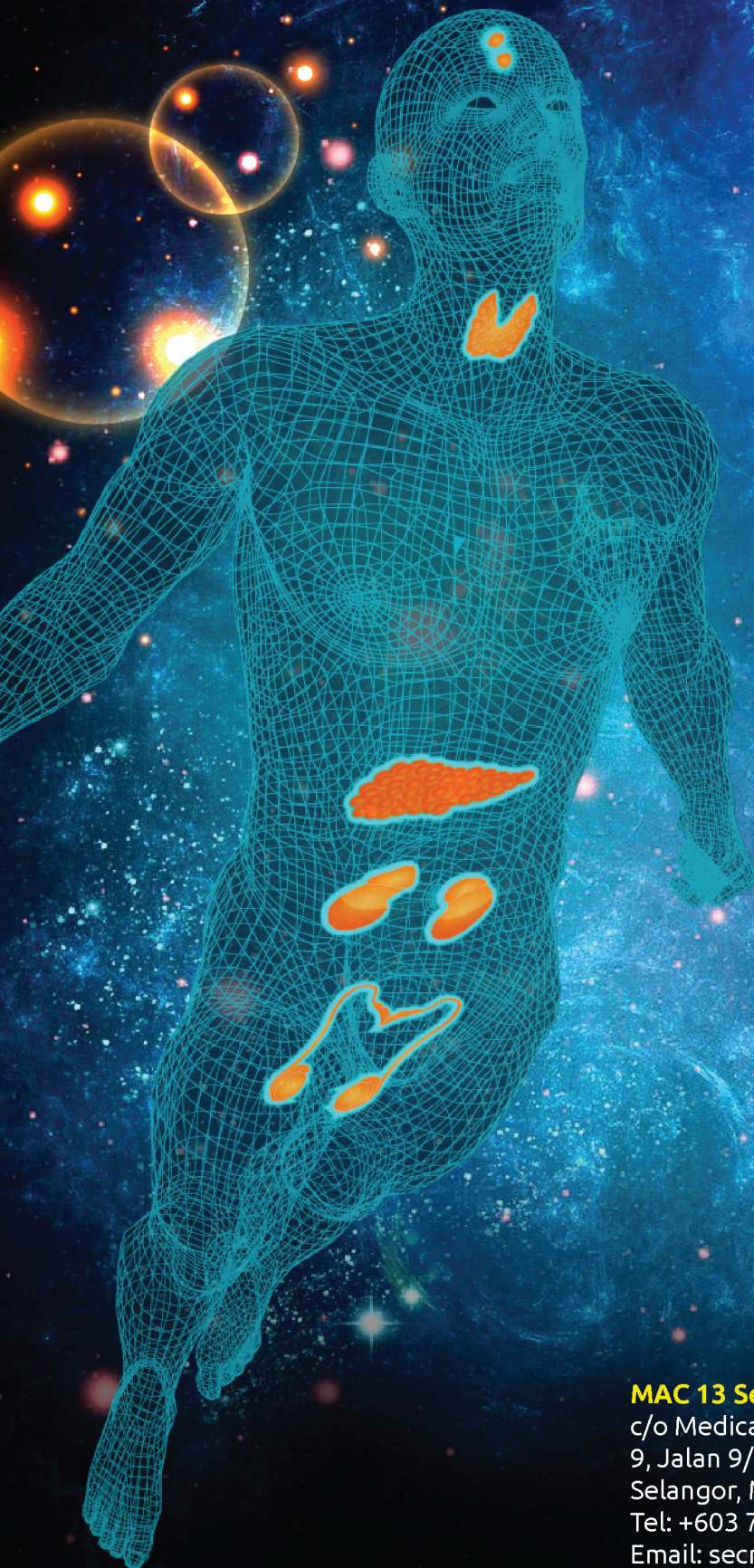


Malaysian Endocrine  
& Metabolic Society

MEMS ANNUAL CONGRESS

MAC

13  
2023



[www.memsmac.org](http://www.memsmac.org)

**MAC 13 Secretariat**

c/o Medical Conference Partners  
9, Jalan 9/3, Section 9, 46000, Petaling Jaya,  
Selangor, Malaysia  
Tel: +603 7931 2856 / +6016 3350 036  
Email: [secretariat@memsmac.org](mailto:secretariat@memsmac.org)